

3D Guided Implant Surgery using CBCT and Stent: A Case Report

**Dr. Anant Agarwal¹, Dr. Ankur Agarwal², Dr. Swarnika Parihar³,
Dr. Shivani Agarwal⁴**

¹Senior Lecturer, Department of Prosthodontics and Crown & Bridge, BBDCODS, Lucknow (U.P.)

²Assistant Professor, Department of Oral Pathology and Microbiology, Career Post Graduate Institute of Dental Sciences, Lucknow (U.P.)

³PG Resident, Department of Paediatric and Preventive Dentistry, Hitkarini Dental College and Hospital, Jabalpur (M.P.)

⁴PG Resident, Department of Conservative Dentistry and Endodontics, BBDCODS, Lucknow (U.P.)

Corresponding Author: Dr. Anant Agarwal

DOI: <https://doi.org/10.52403/ijrr.20220870>

ABSTRACT

The combination of CBCT and three dimensionally guided implant surgery using stents has given new direction and horizon to the field of Dental Implantology and has been studied and researched by Implantologists worldwide. Surgically guided implant is placed by creating osteotomy through a digitally designed and printed stent, has the potential to reach the highest level of precision, accuracy and control. This case report discusses placement of implant using superimposition of CBCT scan and digitally scanned cast through three-dimensional guide or stent customized for the patient.

Keywords: Guided implant surgery, CBCT, surgical guide, 3D stent.

INTRODUCTION

Dental Implantology has evolved over years as there is a shift from conventional to guided implant surgery. Treatment planning of dental implant therapy is one of the biggest and most encountered problem by the practitioners on employing either the conventional or the guided surgery.¹ The guided implant surgery is done in a very simplified and predictable fashion. A surgical guide is a medical device which is three dimensionally printed based on a CBCT and is customized for every patient

to assist in implant placement with optimal accuracy to guide your surgical instruments and implant accurately according to the planned position.² The accuracy of implant placement using the computer guided surgical stent has been checked and studied by several authors in their respective studies who conclude that the accuracy of placing and the survival rates are much higher than with the conventional technique.³

CASE REPORT

A 62 year old male patient reported to the Department of Prosthodontics and Crown & Bridge of BBDCODS, Lucknow, with the chief complaint of accumulation of food in his lower left back tooth region of jaw due to missing tooth in that region since 2 years (Fig. 1). A complete case history was recorded followed by thorough intraoral examination. The intraoral examination revealed generalized spacing in anterior region, generalized attrition generalized gingival recession and crown was present with respect to 46. Diagnostic impressions were made and then the CBCT Analysis was done for the patient. The diagnostic cast was scanned using software and then the CBCT scan was superimposed over the diagnostic cast (Fig. 2) scan to produce a 3-Dimensional guide or Stent (Fig. 3). The

stent was tried in to check the fit of the appliance before starting the surgery. Then after infiltrating the area with local anesthetic and stabilizing the stent, tissue punch was used to access the implant site. Dental Implant drill guide is first used to place drill and is available in various sizes

(Fig. 4). The stent was removed and tissue was scooped out using spoon excavator. The osteotomy was carried out through the surgical guide (Fig. 5) following the drilling protocol of the Genesis Implant System (Fig. 6) and the implant was placed (Fig. 7 & 8).

Fig 1: Pre operative intraoral picture

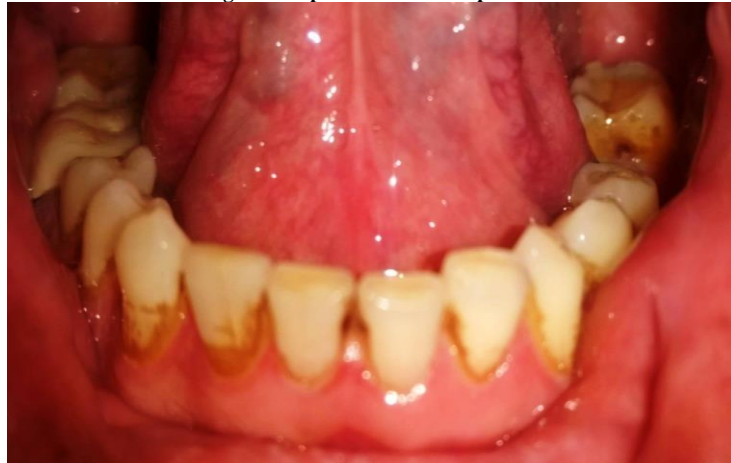

Fig 2: Superimposition of CBCT Scan and Diagnostic cast

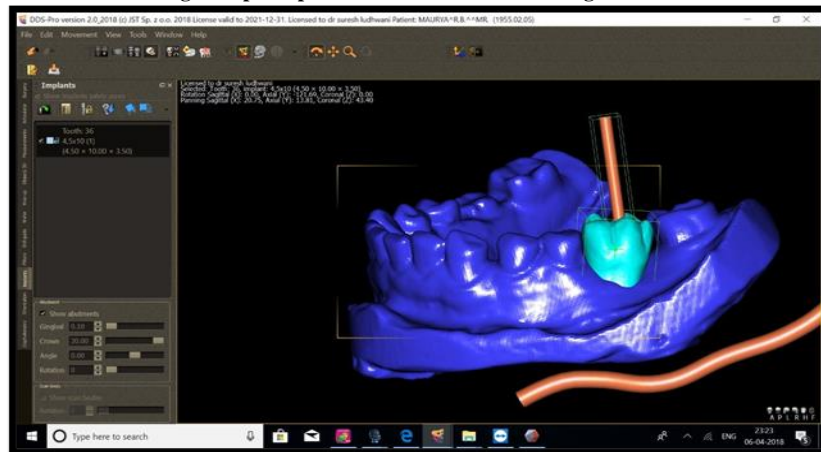


Fig 3: Surgical guide or Stent

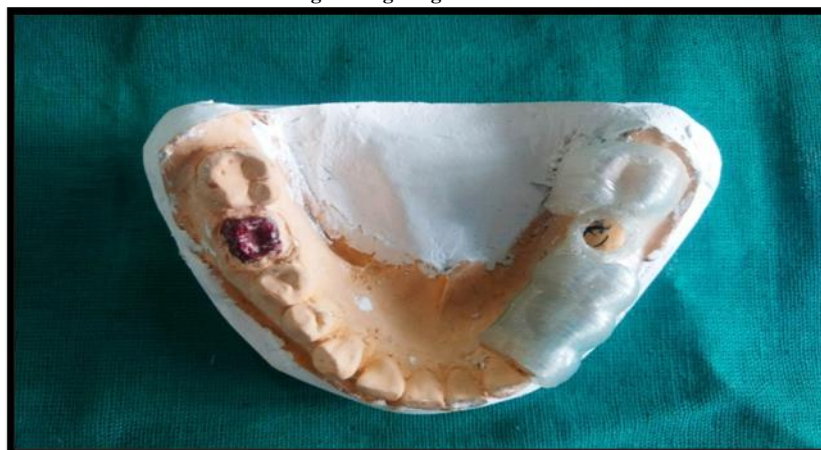

Fig 4: Dental Implant drill guide

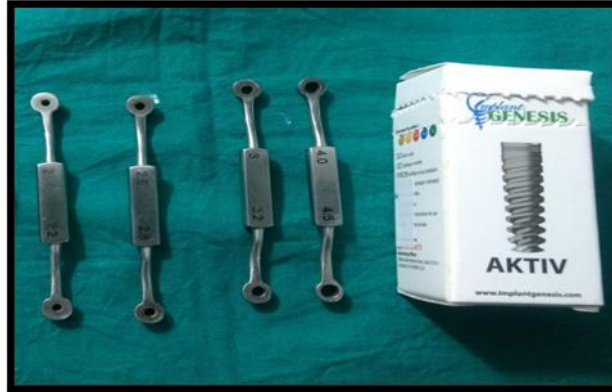

Fig 5: Placement of drill using drill guide

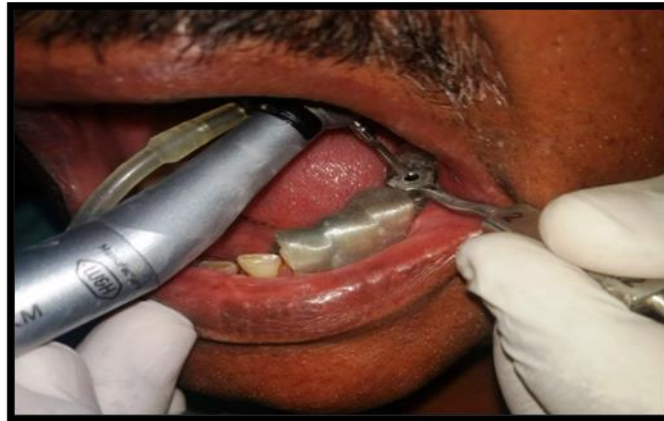

Fig 6: Genesis Implant System

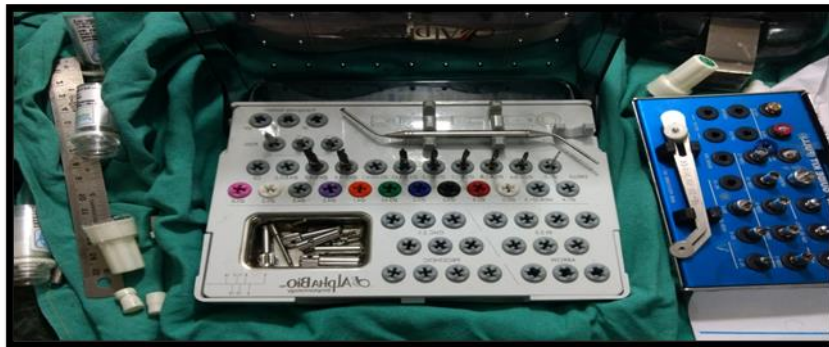

Fig 7: Placement of Implant

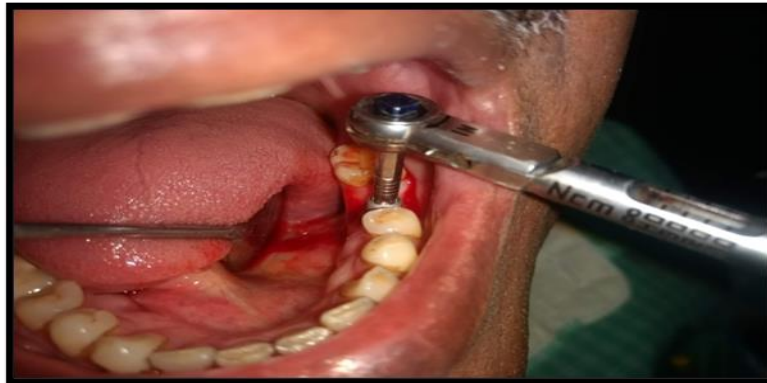
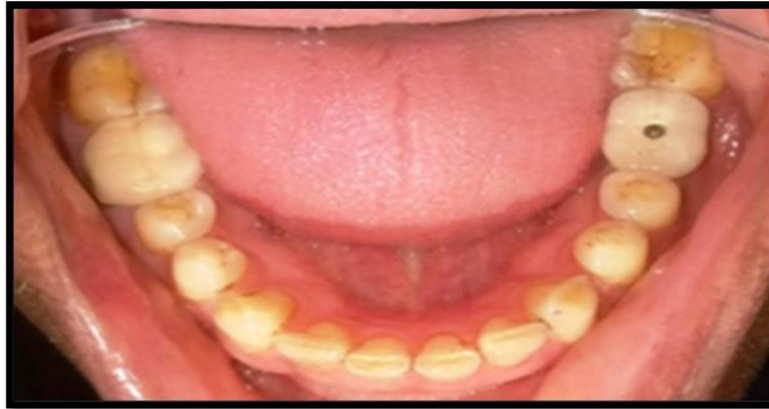
Fig 8: Post Operative Intraoral Image



DISCUSSION

Designing and placement of implant supported prosthesis is a challenge encountered by prosthodontists and implantologists. Malaligned implants complicate the lab procedures required for fabrication of implant superstructures. They also lead to improper load distribution, compromising the integrity of bone-implant interface.⁴ Use of surgical guides reduces surgical time, reduces trauma, pain and swelling, short recovery time, accurate transfer from virtual to clinical setting, better prosthetic results and enables immediate loading and flapless surgery in the cases.²

Ersoy et al. stated that CT-derived surgical stents significantly improve the accuracy, efficiency in both quality and time, minimizes surgical errors, beneficial for both the patient and dentist.⁵

Similarly, Beretta et al. stated that the flapless computer-assisted implant surgery provided Implantologists with tremendous advantages. The flapless approach helped to minimize surgical trauma and patient morbidity in the immediate postoperative duration. Also computer-assisted surgery reduces the possibility of intraoperative complications, allowing an ideal prosthetic-driven implant surgery.⁶

Aizenberg et.al reported less postoperative swelling in flapless surgery when compared to open flap surgery⁷

Nickeing et. al stated that the accuracy of implant placement after virtual planning using CBCT data and surgical stents is high

and significantly more accurate than the conventional freehand insertion.⁸

Pozzi et.al stated that when treatment planning was made with CBCT scanning using 3D implant planning dedicated software and free-hand conventional technique, postoperative pain and swelling at sites treated with free-hand conventional technique was more because more frequently flaps were elevated.⁹

CONCLUSION

With the advancements in implant placement techniques and computer-guided surgical techniques, accurate position and angulation of implants could be achieved, accompanied with better function and esthetics. Hence, the use of both the radiographic CBCT scans and surgical stents may be carried out for treatment planning and placement of dental implants.

Acknowledgement: None

Conflict of Interest: None

Source of Funding: None

REFERENCES

1. Chippalapally et al. Implant placement using CBCT guided stent and conventional stent - A case report. IP Annals of Prosthodontics and Restorative Dentistry 2018;4(1):9-12.
2. Jayashree M, Mohan N, Sunantha S, Parithimar K, Paul J. Cone Beam Computed Tomography [CBCT] in Guided Implant Surgery – A Case Report. J Clin

- Prosthodontics and Implantology 2019; 1(1):11-14.
3. Gajjar et al. A Flapless Surgical Placement of Implants in Mandibular Arch Using Computer-Guided Surgical Stent. J Adv Oral Res 2018; 9(1-2):55–60.
 4. Pal et al. Stents for dental implants. Natl J Maxillofac Surg 2010; 1(1): 22-23.
 5. Ersoy AE, Turkymiaz I. Reliability of implant placement with stereolithographic surgical guides generated from computed tomography-clinical data from 94 implants. J periodontal. 2008;79:1339-1345.
 6. Beretta M, Poli PP. Accuracy of computer aided template guided oral implant placement; a prospective clinical study. J periodontal Implant Sci. 2004;44:184- 193.
 7. Aizenberg A, Jansson J. Short term post operative discomfort in patients receiving flapless contra open implant surgery. Open J of Stomatology.2013;3;298- 305.
 8. Nickeing H J. Evaluation of difference in accuracy between implant placement by virtual planning data and surgical guide templates versus conventional free hand method- a combined in vivo- invitro technique using cone beam CT (part 2). J of Cranio maxilla facial surgery.2010;38:488-493.
 9. Pozzi A. four implant overdenture fully supported by a CAD/CAM titanium bar; a single cohort prospective 1 year preliminary study. J Prosthet Dent. 2016;116(4):516-523.

How to cite this article: Anant Agarwal, Ankur Agarwal, Swarnika Parihar et.al. 3D guided implant surgery using CBCT and stent: a case report. *International Journal of Research and Review*. 2022; 9(8): 833-837. DOI: <https://doi.org/10.52403/ijrr.20220870>
