

# Management of Furcal and Subcrestal Perforation with a Bioactive Material - A Case Report

Dr. Shikha Jaiswal<sup>1</sup>, Dr. Sachin Gupta<sup>2</sup>, Dr. Aleena Khan<sup>3</sup>, Dr. Komal Kumari<sup>4</sup>,  
Dr. Shalya Raj<sup>5</sup>

<sup>1</sup>Professor, Department of Conservative Dentistry and Endodontics, Subharti Dental College,  
Swami Vivekanand Subharti University, Meerut

<sup>2</sup>Professor, Department of Conservative dentistry and Endodontics, Subharti Dental College,  
Swami Vivekanand Subharti University, Meerut

<sup>3</sup>Post Graduate, Department of Conservative Dentistry and Endodontics, Subharti Dental College,  
Swami Vivekanand Subharti University, Meerut

<sup>4</sup>Post Graduate, Department of Conservative Dentistry and Endodontics, Subharti Dental College

<sup>5</sup>Professor, Department of Conservative Dentistry and Endodontics, Subharti Dental College,  
Swami Vivekanand Subharti University, Meerut

Corresponding Author: Dr. Aleena Khan

DOI: <https://doi.org/10.52403/ijrr.20220534>

## ABSTRACT

Perforations during endodontic procedures are cited as the second greatest cause of treatment failures. Hence, when a perforation occurs, the goal should be to sterilize the site and then seal the perforation as soon as possible. Amongst the various available material, calcium silicate-based materials especially MTA is the most widely used for perforation repair due to its favourable cementogenic and osteogenic potential. The purpose of this case report is to describe endodontic retreatment and nonsurgical management of iatrogenic perforation in retreatment cases managed successfully with MTA-Angelus.

**Keywords:** Iatrogenic perforation, Mineral trioxide aggregate, Endodontic retreatment, non-surgical repair

## INTRODUCTION

A perforation is a communication that arises between the periodontium and the root canal space. Perforations can be pathological, resulting from caries or resorptive defects, but most commonly occur iatrogenically (during or after root canal treatment). These procedural operative errors may occur at any phase of endodontic treatment and may have a negative impact

on treatment outcome. Present endodontic literature shows that 2–12% of endodontically treated teeth are associated with accidental perforations, which may have serious implications. Improper or delayed management of perforation may jeopardize the prognosis of root canal treatment. [1]

Success in the management of perforation depends on several factors e.g.: time elapsed from the perforation, presence or absence of bacterial contamination, size and shape and location of the perforation etc. Amongst all the factors, location of perforation plays a crucial role in determining the prognosis [2]. According to a study by Seltzer *et al*, furcal area perforations in molars are more troublesome and offer a guarded prognosis as there is an increased chance of periodontal involvement and tissue destruction in such cases. [3]

The goal of perforation repair is to decontaminate the site and then seal the perforation with a suitable material. Endodontic literature lists use of various materials in managing perforations like calcium hydroxide, composite resin, glass ionomer, resin modified glass ionomer etc.

However calcium silicate-based cement Mineral trioxide aggregate (MTA) has been used most extensively in repair of lateral radicular and furcal perforation due to its excellent osteogenic and regenerative potential.<sup>[4]</sup>

This case report describes subcrestal root perforation and a furcal perforation in two different retreatment cases which were successfully managed with MTA.

### CASE 1:

A 28yr-old male patient reported with the chief complaint of mild pain and food impaction in his lower right posterior region for 7 months and gave history of prior dental treatment of the same tooth at a private clinic. On intraoral examination, 47 (FDI) was found to be grossly decayed with slight tenderness on percussion and mobility between physiological limits.

Intraoral periapical radiograph revealed incomplete obturation of the canals in 47 which exhibited two fused roots indicating a C-shaped canal anatomy with periapical radiolucency at the apex and intracanal radiopaque material on the mesial side of the root. Additionally, a sub crestal root perforation and radiolucency around the perforation site was also observed (Figure 1[a]) Provisional diagnosis of previously initiated root canal with secondary apical periodontitis and subcrestal perforation in relation to 47 was made. Keeping in mind the guarded prognosis of the case, various treatment options were explained to the patient and he desired to retain the tooth. Hence a final treatment planning of retreatment of root canal of 47 combined with perforation repair with MTA followed by post and core and full coverage restoration was decided with patient's consent.

Standard isolation procedure with rubber dam was followed. Coronal access opening was refined and cleaned under a

Dental Operating Microscope under 16x magnification. Canal orifices were identified and gutta-percha from the main canal was removed with H-file (Dentsply-Maillefer, USA) and solvent xylene (Figure 1[b]). After, establishing the working length radiographically, (Figure 1[c]) the canals were cleaned with copious amount of 5.25% which was activated using Endo activator (Dentsply Maillefer, Switzerland) and shaped using Protaper Gold files ((Dentsply Tulsa Dental, Tulsa, OK, USA)

Previous attempt to adequately seal the perforation site was made with a white cement, probably zinc-oxide-eugenol, which on removal with burs showed a large lateral subcrestal perforation on the mesial area of the root, with intense haemorrhage indicating acutely inflamed tissue. Haemorrhage was controlled with copious irrigation with 1% NaOCl and pressure application with saline soaked cotton pellet. The perforation site was then packed with Ca(OH)<sub>2</sub> (Prime Dental Products. Pvt. Ltd) to control inflammation and simultaneously root canal was also packed with ICM.

On recall after 1 week, the patients were asymptomatic and there was no bleeding from perforation site. The canals were obturated with corresponding Protaper cones and endodseal sealer (Prevest Dent Pro Pvt. Lt.) while protecting the perforation site with polytetraethylene tape (Figure 2[d]). Thereafter perforation repair was done using resorbable matrix (Abgel, *Absorbable Gelatin Sponge*) against which MTA Angelus mixed with sterile saline paste in a 3:1 proportion was condensed with finger pluggers (Dentsply, Maillefer) (Figure 1[e]). After radiographic verification, access was sealed with IRM (Cavitemp, Ammdent) (Figure 1[f]).

On subsequent visit, fibrepost was placed (Figure 1[g]) with composite core which was followed by crown placement.

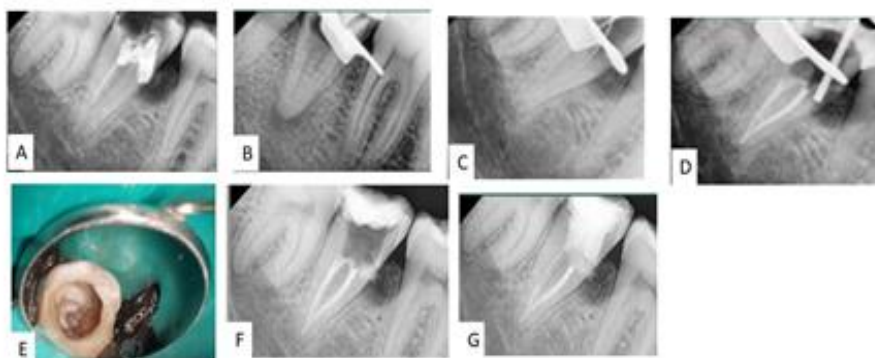


Figure 1 (a): Preoperative radiograph (b) Post GP removal (c) Working length determination (d) Obturation completed and placement of Abgel (e) Clinical photograph post MTA placement (f) Radiograph confirming correct placement of MTA in defect (G) Post operative radiograph with glass fiber post placed and core buildup completed



Figure 2(a): Working length determination (b) master cone confirmed radiographically (c) Clinical photograph post MTA placement (d) Radiograph confirming the correct placement of MTA

## CASE 2

A 60-year-old male patient presented with the complaint of chronic pain in lower left posterior region since one month. There was no significant medical history but patient gave the history of previous dental treatment. In the intraoral examination, grade I mobility and furcation involvement could be appreciated in 36 which was sensitive to percussion and painful on palpation. The mean probing pocket depth was within normal limit. Radiographic examination revealed an incomplete root canal treatment of 36 with radiolucency in the furcation area. With patient's consent, retreatment with perforation repair was planned. On removing of the temporary restoration, there was profuse haemorrhage

which was controlled with copious irrigation with help of 1% NaOCl and pressure with saline soaked cotton. The canal orifice was located under a Dental Operating Microscope under 16x magnification and perforation could be observed on the pulpal floor which was then confirmed radiographically. Simultaneous cleaning and shaping of the canal were done with Protaper Gold (Dentsply Tulsa Dental, Tulsa, OK, USA) till F2 after working length determination [Figure 2(a)]. Each successive filling was followed with 5.25% sodium hypochlorite (Prime Dental Product, Mumbai, India) which was activated using Endo activator (Dentsply Maillefer, Switzerland) and followed by saline (0.9 w/v NaCl) After completion of

biomechanical preparation, calcium hydroxide (Prime Dental Products. Pvt. Ltd) was placed simultaneously in the canal and at the perforation site, access cavity was sealed with IRM (Cavit™ 3M ESPE) and patient was recalled after one week.

On recall appointment, patient was asymptomatic and the canals were obturated with F2 Protaper Gutta Percha cone (Dentsply) [Figure 2(b)], there was no haemorrhage at perforation site so perforation repair was performed with MTA (Branco Branco White Angelus, Londrina, PR, Brasil) after placement of resorbable matrix (Abgel, *Absorbable Gelatin Sponge*) at perforation site. MTA was mixed in the ratio 3:1 and was carried to the perforation site with the help of MTA carrier- MAP (Micro Apical Placement System, Dentsply Maillefer) at perforation site and condensed with the help of finger plugger (Figure 2[c]) and verified radiographically (Figure 2[d]). A moist cotton pellet was placed in the pulp chamber to provide the humid environment for the MTA with the aim of achieving its solidification and followed by replacement of cavity as temporary restoration.

On recall visit, the patient was asymptomatic, temporary filling material and wet cotton pellet was removed and after testing the hardness of MTA gently with an operative explorer, the access cavity was restored with composite. On follow up visit after 1 month, the patient was asymptomatic indicating favourable outcome of the case.

## DISCUSSION

Peeso *et al* in 1903 stated that successful management of root perforations is hugely dependent on its early diagnosis, choice of treatment, materials used, host response, experience of the practitioner, in addition to location, size and time of contamination of the lesion.<sup>[5]</sup>

Non-surgical repair of perforation was considered in the both the cases due to good visibility and accessibility of the perforation sites. Major goals of nonsurgical retreatment of endodontically failed teeth with iatrogenic perforation include thorough

debridement, disinfection and three dimensional obturation of previously treated canals to remove all etiological factors, without compromising on the root dentin along with gaining access to prepare and seal the perforation with a biocompatible material and maintain an intact periodontal attachment apparatus.<sup>[6]</sup>

The size of a perforation is an important factor in determining the success of the repair procedure; In the present cases, as both sub crestal and furcal perforations were large, with a risk of filling material extrusion hence use of external resorbable matrix was favoured which served as a scaffold against which repair material was condensed.

Preoperative radiolucent area adjacent to the perforation site was observed in case 1 suggesting a long-standing lesion hence disinfection of perforation site becomes imperative in such cases. The available literature suggests that the use of calcium hydroxide for 7 days at the perforation site leads to a significant reduction of microorganisms and aids in perforation repair, by: (I) Controlling the inflammatory reaction (ii) neutralizing osteoclast acid products (iii) inducing cellular differentiation; (iv) inducing mineralization and (v) neutralization of endotoxins.<sup>[4]</sup> Hence in both cases calcium hydroxide was packed at the perforation site for a week.

The perforation site was irrigated with 1% NaOCl. Nicholls *et al* <sup>[7]</sup> and Pitt ford *et al* <sup>[8]</sup> recommended that contaminated perforations should be washed out with hypochlorite for thorough disinfection. In the present case the Dental Operating Microscope was used to repair the perforation defect and midrange magnification (16×) was used.

The increased magnification invaluable to diagnose and locate accurately the exact perforation site. Incremental placement of the Mineral Trioxide Aggregate over the perforation site can be carried out successfully and precisely under a microscope.



MTA-Angelus (Angelus, Londrina, PR, Brazil) was used for perforation repair due to its good handling characteristics and faster setting time (10 min). The highly biocompatible nature of MTA and its tendency to induce osteogenesis and cementogenesis makes it a suitable candidate for root perforation repair and attain the regeneration of periodontal attachment.<sup>[10]</sup>

MTA was selected as perforation repair material in both the cases. Pitt Ford *et al* and Torabinejad *et al*, highlighted superior sealing ability and biocompatibility of MTA, inducing cementum formation at the perforation site. <sup>[9]</sup>

The use of MTA helped in achieving a favourable and predictable outcome of the cases presented in this article, as there was a marked improvement in the prognosis of teeth repaired with MTA at the follow up visits.

However, careful consideration of the anatomy and position of the tooth are imperative before endodontic therapy to avoid procedural accidents in first place and to avoid such an occurrence, knowledge of root canal anatomy and appropriate diagnostic radiograph to guide for proper direction and depth of bur and use of magnification and illumination serve as an important adjuvants to prevent perforation.

**Acknowledgement:** None

**Conflict of Interest:** None

**Source of Funding:** None

## REFERENCES

1. Farzaneh M, Abitbol S, Friedman S. Treatment outcome in endodontics: The

- Toronto study. Phases I and II: Orthograde retreatment. *J Endod.* 2004;30(9):627-33.
2. Elbahary S, Haj YS, Koc C *et al.* Bacterial Colonization and Proliferation in Furcal Perforations Repaired by different materials: A Confocal Laser Scanning Microscopy Study. *Appl Sci.* 2021;11 3403.
3. Seltzer S, Sinai I, August D. Periodontal effects of root perforations before and during endodontic procedures. *J Dent Res.* 1970;49(2):332-9
4. Estrela C, Decurcio DA, Rossi-Fedele G *et al.* Root perforations: A review of diagnosis, prognosis and materials. *Braz Oral Res.* 2018;32: e73
5. Kvinnsland I, Oswald RJ, Halse A *et al.* A clinical and roentgenological study of 55 cases of root perforation. *Int Endod J.* 1989;22(2):75-84
6. Cohen S, Burns RC. *Pathways of the pulp.* 8th Ed. US: Mosby, St. Louis; 2002.p.875-929.
7. Nicholls E. Treatment of traumatic perforations of the pulp cavity. *Oral Surg Oral Med Oral Pathol.* 1962; 15:603-12
8. Pitt Ford TR, Torabinejad M, McKendry DJ *et al.* Use of mineral trioxide aggregate for repair of furcal perforations. *Oral Surg Oral Med Oral Pathol Oral Radiol Endod.* 1995;79:756-63
9. Torabinejad M, Pitt Ford TR, McKendry DJ *et al.* Histologic assessment of mineral trioxide aggregate as a root-end filling in monkeys. *J Endod.* 1997; 23:225-8.
10. Gomes-Filho JE, Watanabe S, Bernabé PF *et al.* A mineral trioxide aggregate sealer stimulated mineralization. *J Endod.* 2009; 35(2):256-60.

How to cite this article: Shikha Jaiswal, Sachin Gupta, Aleena khan et.al. Management of furcal and subcrestal perforation with a bioactive material - a case report. *International Journal of Research and Review.* 2022; 9(5): 267-271. DOI: <https://doi.org/10.52403/ijrr.20220534>

\*\*\*\*\*