

Multiple Cavernous Hemangiomas in Brain - A Rare Case Report

**Dr. B. Syam Sundara Rao¹, Dr. Nandam. Mohan Rao², Dr. Bhavana Grandhi³,
Dr. Vijaya Lakshmi Muram Reddy⁴, Dr. Sunandalakshmi GV⁵**

¹Professor, Department of Pathology, Narayana Medical College, Nellore (A.P), India

²Professor, Department of Pathology, Narayana Medical College, Nellore (A.P), India

³Professor, Department of Pathology, Narayana Medical College, Nellore (A.P), India

⁴Associate Professor, Department of Pathology, Narayana Medical College, Nellore (A.P), India

⁵Assistant Professor, Department of Pathology, Narayana Medical College, Nellore (A.P), India

Corresponding Author: Dr. B. Syam Sundara Rao

DOI: <https://doi.org/10.52403/ijrr.20220521>

ABSTRACT

Cavernous haemangiomas are vascular malformation of the brain and that are usually asymptomatic in central nervous system. They confound anywhere in Central Nervous system. We report a case of multiple cavernous haemangiomas of the brain as different lesions in a 45year old male who had presented with seizures to Neurosurgery department.

Keywords: Cavernoma, seizures, Multiple

INTRODUCTION

Cavernous haemangiomas are vascular malformations that are reported to be found at any location in Central Nervous system. It is a vascular tumor characterized by channels which are separated from brain tissue by a thin adventitia layer⁽¹⁾. Seizures, headache, and focal neurological deficits are the associated findings as a results of blood leakage and the hemosiderin deposition in the surrounding brain parenchyma^(2,3). The prevalence of cavernous hemangiomas is 0.5% of the population and include 5-13% of all brain vascular lesions. Cavernous hemangiomas may occur in a familial manner or sporadic and multiple lesions occurrence is mandatory in familial type. cavernous hemangioma most frequent site (80%) was supra tentorial and rarely in the brain stem accenting for 20 to 30% of all

intra cerebral hemangiomas⁽⁴⁾. Cavernomas are unusually large collections of blood vessels without parenchyma interceding between the sinusoidal vessels⁽⁵⁾. These blood vessels have thin walls and have no smooth muscle support. we present a case of multiple cavernous hemangioma in different sites of brain in a 42 years old male patient who had presented with seizures

CASE REPORT

A 42 years Male patient with a history of recurrent seizures for the past 5 years came to the neurosurgery department. He did not have any motor and sensory deficits or altered sensorium is seen. There were no abnormal laboratory findings. MRI of brain revealed well defined T1 isointense and T2 Flair heterogeneously hypointense lesions in right temporal frontal region and cerebellar vermis with T2 hypo intense surrounding rim suggestive of old bleed revealing a cavernous hemangioma (Fig-1,2). Patient underwent surgery and excised specimen was sent to the pathology department for Histopathological examination. Macroscopically specimen consists of multiple grey brown to grey white soft tissue bits altogether measuring 2x2x1cm. Histopathological examination of the lesion revealed multiple inter communicating cystically dilated blood

vessels lined by flattened endothelial cells and showing hemorrhage (Fig-3). Few vessels show evidence of thrombosis. Hemosiderin laden macrophages seen throughout section and glial tissue in one focus. A final diagnosis of cavernous hemangioma was based on Histopathological features. Patient recovery was uneventful and showed good recovery after 2 months.

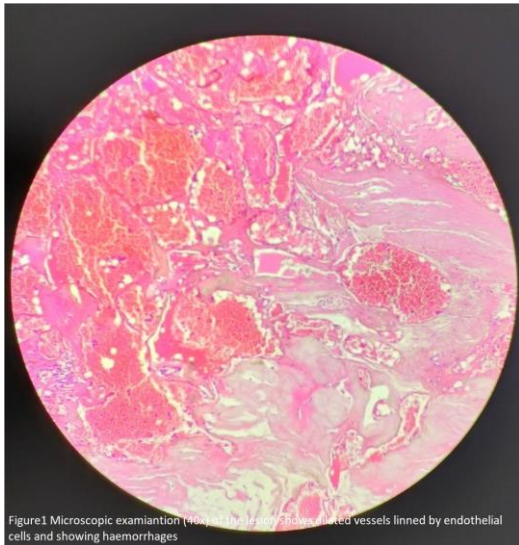


Figure 1: Microscopic examination (40x) of the lesion shows dilated vessels lined by endothelial cells and showing haemorrhages.

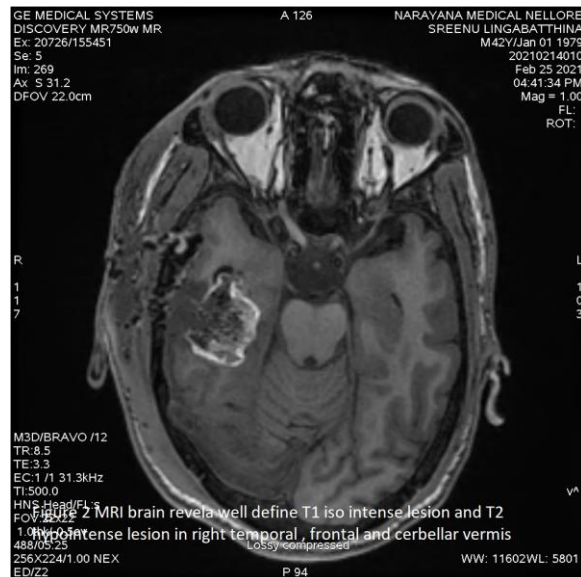


Figure 2: MRI brain reveals a well define T1 iso intense lesion and T2 hypointense lesion in right temporal, frontal and cerebellar vermis.

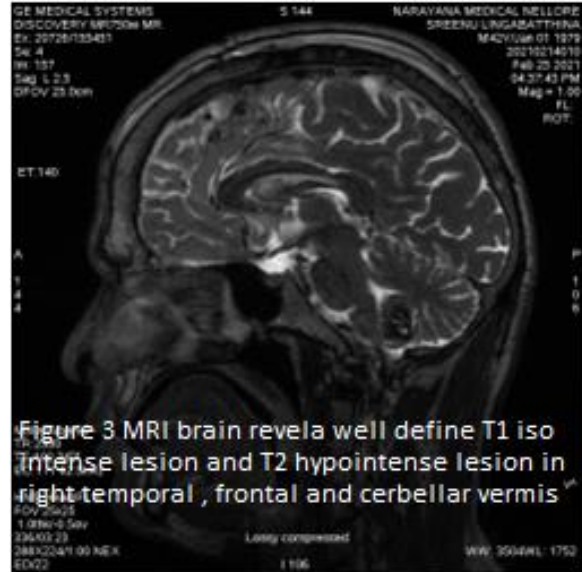


Figure 3: MRI brain reveals a well define T1 iso intense lesion and T2 hypointense lesion in right temporal, frontal and cerebellar vermis.

DISCUSSION

Cavernous hemangioma is a vascular disorder of the brain characterized by abnormal vascular channels lined by single layer of endothelium without any intervening neural parenchyma or identifiable mature vessel wall elements (6). It is a congenital vascular malformation, occurs as multiple lesions in familial form and an isolated lesion in sporadic form of disease. Incidence of cavernous hemangioma in adults is 0.00056%: In familial cases it occurs as Autosomal Dominant form. CCM1, CCM2, CCM3, are genetic mutations involved in Cavernous hemangioma (7). It can occur throughout the CNS, including spinal cord. seizures are the most common clinical presentation and other neurological symptoms like headache, focal motor/ sensory deficits may be seen. In MRI the lesion appears as popcorn ball appearance with mixed hyper and hypo intense blood containing channels (8). Grossly, majority of cases occur in supratentorial location with mulberry-like clusters of tightly compacted dilated vessels. (7) Microscopically composed of closely juxtaposed, dilated vascular channels with little/no intervening brain parenchyma (8). Areas of calcification and knots of hyalinization representing thrombosis and

periphery shows haemosiderin, gliosis and rarely gamma-gandy bodies. Capillary telangiectasia and Arteriovenous malformation are all in the differential diagnosis of cavernous hemangioma in brain. Microscopically arteriovenous malformation is differentiated from cavernous hemangioma by small number of arterial vessels usually lack thrombosis. Microscopically capillary telangiectasia is differentiated from cavernous hemangioma by capillary sized blood vessels devoid of thrombosis and small amount of normal intervening brain parenchyma

Cavernous haemangiomas which are found anywhere in the brain. High resolution MRI combined with tractography are helpful for choice of safest and more precise surgical approach. Histopathological examination was helpful for confirm the cavernous hemangioma and exclude other lesions such as arteriovenous malformations and capillary telangiectasia. Cavernous haemangiomas are diagnosis based on symptoms such as Seizures and neurological deficits and confirmed by Histopathological examination

CONCLUSION

Hemangioma often occurs in skin, liver and in brain cavernous sinus. In this case cavernous hemangioma occurs in frontotemporal and cerebellar region which is extremely rare, hence this case is reported. Histopathological examination was helpful for confirming the cavernous hemangioma.

Acknowledgement: None

Conflict of Interest: None

Source of Funding: None

REFERENCES

1. Atherton DJ, pitcher DW wells RS, Macdonald DM (1980): A syndrome of various Cutaneous pigmented lesions, myxoid neurofibromata and atrial myxoma: the NAME syndrome Br J Dermato,1980, 103(4):421-249.
2. Laurans MS, Diluna ML, Shin D, Niazi F, Voorhees JR, et al. (2003): Mutational analysis of 206 families with cavernous malformation. J Neurosurgery,2003,99:38-43.
3. Clatterbuck RE, Eberhart CG, crain BJ, Rigamonti D(2001) Ultrastructural and immunocytochemical evidence the an incompetent blood-brain barrier is related to the pathophysiology of cavernous malformation. J Neurol nerosurg Psychiatry. 2001, 71(2):188-192.
4. Gross BA, Batjer HH, Awad IA, Bendok BR Brainstem cavernous malformation. J Neurosurgery. 2009; 64(5): 805-818.
5. Cortes vela JJ, Concepcion Aramendia L, Ballenilla Marco F Gallego Leonb JI, Gonzalez-Spectrum of neurodiological findings RadiologIa. 2012;54(5):401-9
6. Yadlas, Jabbour P.M. Shekar, Shic Campbell P.G Award I. cerebral cavernous malformation as a disease of vascular Permeability: Neurosurgical focus. 2010: 29(3).
7. Rayachudhuri R, Batjer H.H, Award IA Intracranial cavernous angioma a practical review of clinical and biology aspects. Surgical neurology.2005:63(4) 319-328.
8. Porter R.W, DetulerP.w, Spetzer R F,etal cavernous malformation of the brain stem: experience with 100 patients. Journal of neurosurgery. 1995:83(1)56-59.

How to cite this article: B. Syam Sundara Rao, Nandam. Mohan Rao, Bhavana Grandhi et.al. Multiple cavernous hemangiomas in brain - a rare case report. *International Journal of Research and Review*. 2022; 9(5): 138-140. DOI: <https://doi.org/10.52403/ijrr.20220521>
