

An Interesting Case of Paraparesis

Badrinath. A.K¹, Sravya Nadhella², Karthik³

¹Professor and Unit Chief, ²Postgraduate Resident, ³Senior Resident,
Department of Medicine, Sri Manakula Vinayagar Medical College and Hospital, Pondicherry

Corresponding Author: Badrinath. A.K

DOI: <https://doi.org/10.52403/ijrr.20220437>

ABSTRACT

Carcinoma prostate is the second leading cause of cancer death in men.¹ Acinar adenocarcinoma comprises of 90 to 95% of the cases.² Majority of the patients are asymptomatic and detected by screening test such as PSA (Prostate specific antigen). Although prostate cancer is locally invasive, it can spread to bone without significant lymphadenopathy. It has a strong predilection for bone metastasis. Here we will discuss a case of prostate cancer presented to us as paraparesis.

Keywords: Prostate cancer, paraparesis, case report

INTRODUCTION

The risk of malignant disease of prostate increases with age. The risk increases by 2.5 fold with a positive first degree relative with a prostate cancer. It is the most common non cutaneous cancer in men. Majority of patients are asymptomatic but can present with symptoms of cancer as well as symptoms of local and distant spread. They include urinary urgency, urinary retention, back pain, hematuria, weight loss, anemia, pathological fracture, spinal cord compression can cause neurological deficit. The screening test available are prostate specific antigen (PSA), digital rectal examination (DRE) and transrectal ultrasonography (TRUS). Metastasis to spine occurs through Batson's venous plexus.

CASE DESCRIPTION

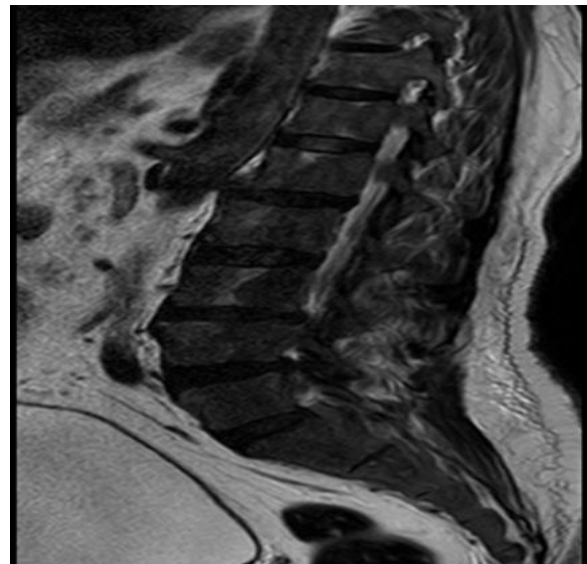


Figure 1: T2 sagittal dorsa lumbar spine showing diffuse altered marrow signal intensity with intervening areas of T1 and T2 high signal intensity suggestive of residual marrow

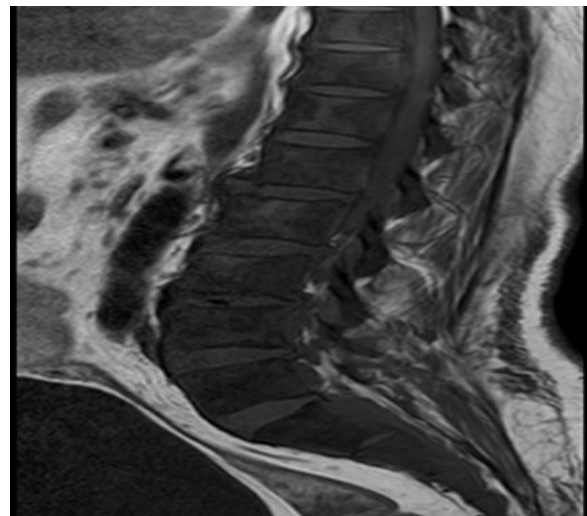


Figure 2: T1 sagittal section LS spine showing diffuse altered marrow signal intensity with intervening areas of T1 and T2 high signal intensity suggestive of residual marrow

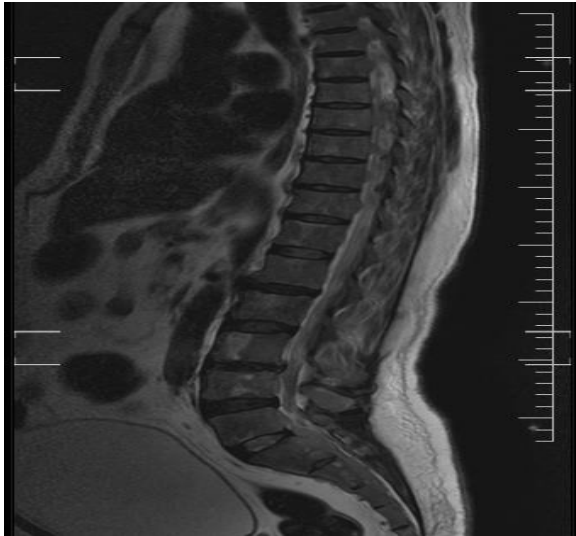


Figure 3: Sagittal section of dorso-lumbar spine showing diffuse altered marrow signal intensity with intervening areas of T1 and T2 high signal intensity suggestive of residual marrow

A 68 years old male came with complaints of low back pain with difficulty in squatting for the past 2 months. He was admitted and started on analgesics and investigated with lumbar X-ray and routine hematological investigations. His Lumbar X-ray showed features of osteoporosis. His blood investigation revealed a high alkaline phosphatase. His ultrasound showed enlarged and heterogenous prostate gland - Grade 1. On the next day he suddenly developed complete weakness of both lower limbs with sensory loss below hip joint with inability to void urine and pass stools. On examining him, he had hypotonia with power 1/5 and loss of abdominal, knee, ankle jerk bilaterally. He was suspected to have compressive myelopathy and MRI spine was taken (Fig 1-3 showing diffuse

altered marrow signal intensity in dorso lumbar and sacral spine) which came to be carcinoma prostate with vertebral and dural metastasis. His prostate specific antigen was elevated (>100 ng/ml). So he was diagnosed as carcinoma prostate with vertebral metastasis causing compressive myelopathy. He was referred to oncology unit for further management.

CONCLUSION

Hence lower limb weakness in elders should be evaluated for spine metastasis especially metastasis from prostate carcinoma in male sex.

Acknowledgement: None

Conflict of Interest: None

Source of Funding: None

REFERENCE

- 1 Kasper DL, Hauser SL, Jameson JL, Fauci AS, Longo DL, Loscalzo J. Harrison's principle of internal medicine. 20th ed. New York: The McGraw-Hill Companies. 2019: 623-629.
- 2 Shah, Rajal B, Ming Z. Histologic variants of carcinoma prostate. Prostate biopsy interpretation. 2019:69-95.

How to cite this article: Badrinath.A.K, Sravya Nadhella, Karthik. An interesting case of paraparesis. *International Journal of Research and Review*. 2022; 9(4): 315-316. DOI: <https://doi.org/10.52403/ijrr.20220437>
