

# Diagnostic Challenges and Management of Patients with Overlapping Rheumatoid Arthritis with Psoriatic Arthritis: A Case Report

Carissa Ayu Zebadiah Rau<sup>1</sup>, Gede Kambayana<sup>2</sup>

<sup>1,2</sup>Department of Internal Medicine, Faculty of Medicine Udayana University, Sanglah General Hospital, Bali, Indonesia

Corresponding Author: Carissa Ayu Zebadiah Rau ([carissaayuzebadiahrau@gmail.com](mailto:carissaayuzebadiahrau@gmail.com))

DOI: <https://doi.org/10.52403/ijrr.20220326>

## ABSTRACT

Rheumatoid arthritis (RA) and psoriatic arthritis (PsA) have key differences in clinical presentation, radiographic findings, and pathogenesis to distinguish between these common forms of chronic inflammatory arthritis. Several case reports report the occurrence of overlapping syndromes of RA with PsA. However, until now, the cases are still very rare.

We report A 33-year-old woman, complaining of pain in the joints of her fingers, toes, and her back since eight years ago. The patient also complained of red, silvery-white patches on the abdomen and spread all over the body. On the left hand, there is a swan neck deformity on the fifth finger of the left hand. On the right hand, there is a boutonniere deformity on the second and fourth fingers of the right hand and ulnar deviation of the first finger. On skin examination, it was found with multiple silvery-white erythematous plaques, varying in size, geographical shape, covered with fine white scales spread all over the body skin. The patient was diagnosed with Rheumatoid Arthritis based on the 2010 ACR/EULAR diagnostic criteria, overlapping with Psoriatic Arthritis syndrome based on the 2010 ASAS diagnostic criteria for spondyloarthritis 2006 CASPAR for PsA. The right diagnosis process speeds up the time for initiation of appropriate therapy to improve quality of life and improve disease prognosis.

**Keywords:** Rheumatoid arthritis, psoriatic arthritis, overlapping syndrome.

## BACKGROUND

Rheumatoid Arthritis (RA) and Psoriatic Arthritis (PsA) are chronic inflammatory diseases characterized by joint pain and swelling, each with significant systemic manifestations.<sup>1</sup> HLA gene is the one that induces joint and systemic autoimmune inflammatory processes. These two diseases are distinguished by how the diagnosis is made, where RA is confirmed by a positive RF examination, whereas in most cases of PsA, the RF is negative. Without proper treatment, these two diseases can cause joint destruction, leading to disability.<sup>2</sup> Several case reports report the occurrence of overlapping syndromes of RA with PsA. However, until now, the cases are still very rare.

We report a case of a patient with RA overlapping with PsA and the challenges of diagnosis and management of this patient.

## CASE ILLUSTRATION

A 33-year-old woman, a housewife, came to the Rheumatology Polyclinic of Sanglah Hospital complaining of pain in the joints of her fingers, toes, and her back since eight years ago. The pain is felt like a stabbing that feels heavy every morning when she wakes up. The pain improves with movement or with analgesics. In the last two years, the fingers have begun to change their shapes, making the patient is difficult to

carry out activities. Since ten years ago, the patient has complained of red, silvery-white patches on the abdomen and spread all over the body. These spots increase in number if the patient is tired or stressed. Family history with similar complaints was denied. History of chronic disease in the family was also denied.

The patient came conscious and alert, with vital signs within normal limits. On the left hand, there is a swan neck deformity on the fifth finger of the left hand. On the right hand, there is a boutonniere

deformity on the second and fourth fingers of the right hand and ulnar deviation of the first finger. Pitting nails are found on both hands. There was a deformity and hyperextension of the distal interphalangeal, first finger of the right foot, and on the second to the fifth finger on the left foot

On skin examination, it was found with multiple silvery-white erythematous plaques, varying in size, geographical shape, covered with fine white scales spread all over the body skin (Figure 1).

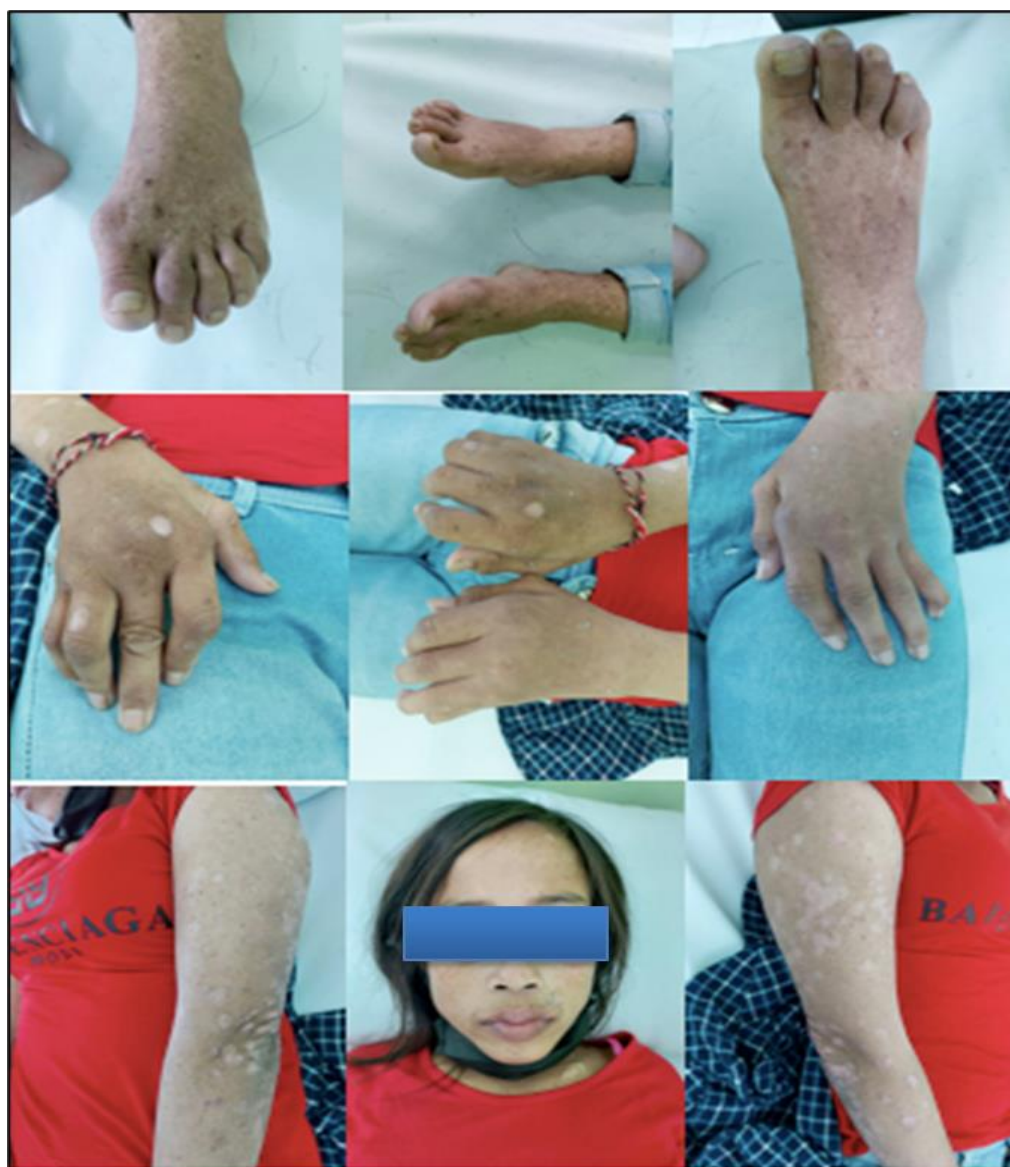

Fig. 1: Clinical photograph of the patient

Complete blood count showed normocytic anemia, hypochromic with Hemoglobin 9.91 g/dl, Hematocrit 33.74%,

with increased ESR 102.7 mm/hour, CRP 41.83 mg/L. Liver function and kidney function were within normal limits.

The AP/Lateral X-ray of the hand showed bilateral rheumatoid arthritis with swan neck deformity of the fifth finger of the left hand and Boutonniere deformity on the second and the fourth finger of the right hand (Fig. 2A). At the same time, the AP/Lateral foot X-ray also showed bilateral rheumatoid arthritis with hyperflexion deformity of proximal interphalangeal.

Furthermore, hyperextension of distal interphalangeal of the first finger of the left and the right foot. The extension of bilateral metatarsophalangeal of the fourth and fifth finger IV was seen (Figure 2B). The X-ray of genu showed bilateral grade III osteoarthritis with an osteophyte on the anteroinferior aspect of the bilateral patella (Fig. 2C).

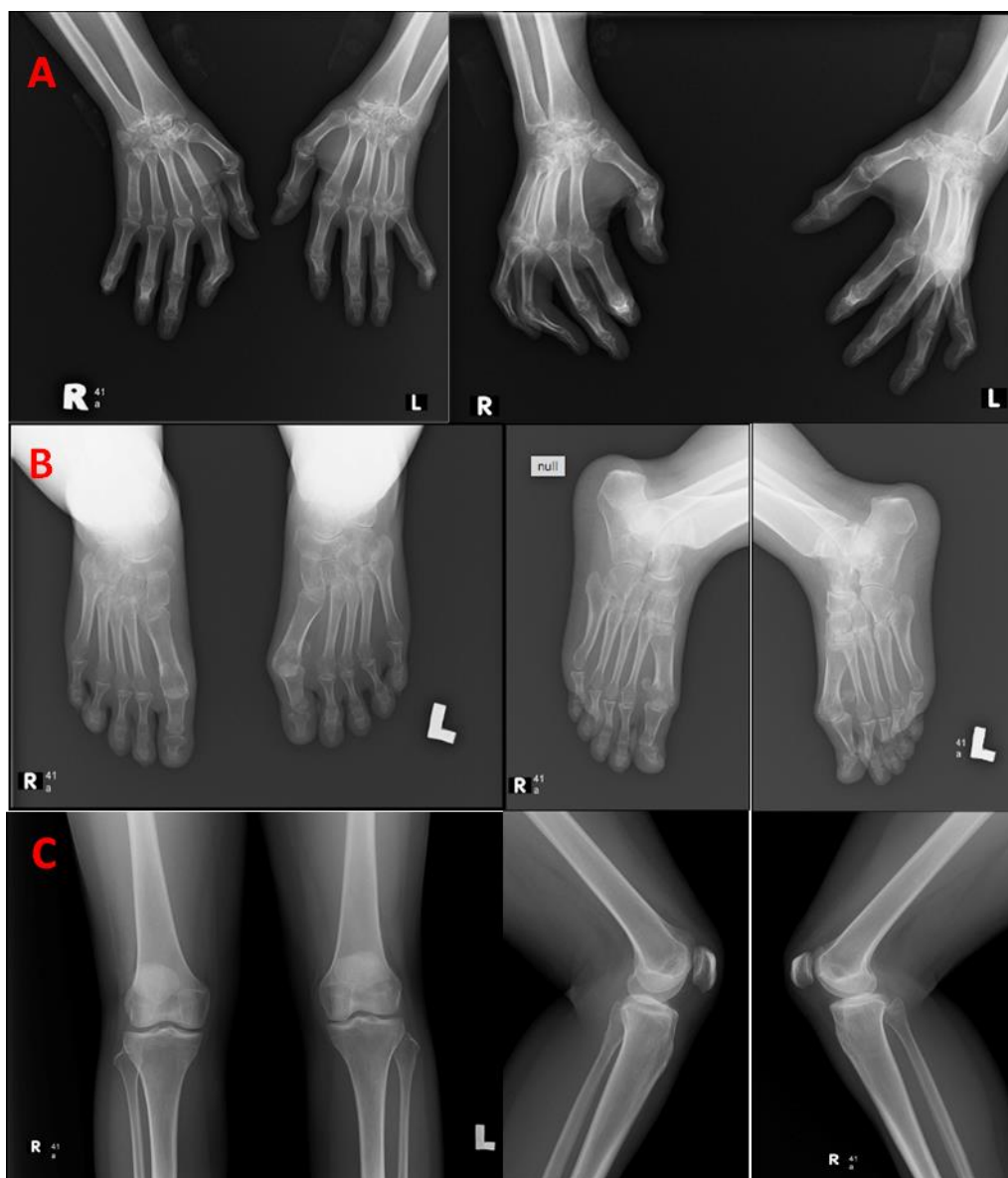


Figure: 2(A, B, C)

Skin biopsy of the abdominal region with Hematoxylin and Eosin staining showed a psoriasiform pattern in the form of basket wave (normal keratin), intact granule and focal vacuolar degeneration, with vertical alternating para-orthokeratosis, non-

thinning supra-papillary plate, dermal papillary containing tortuous dilated capillary vessels, visible also mild lymphocyte infiltration suggests Pityriasis Rubra pilaris (Fig. 3).



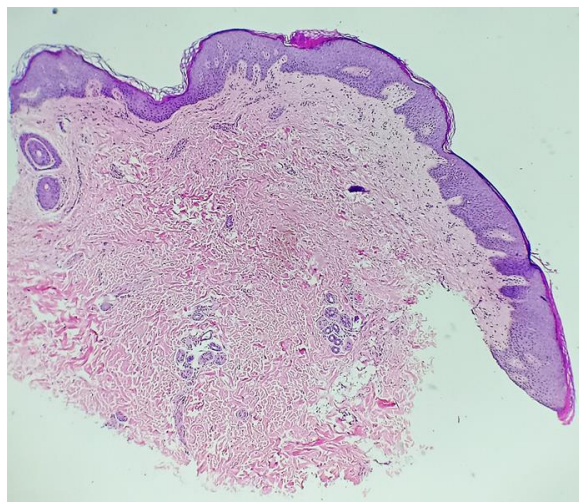


Figure 3

Lumbosacral plain X-ray examination showed malalignment, lumbar scoliosis with left convexity, and sclerosis with severe erosions and widening of the right sacroiliac joint space, suggesting grade III sacroiliitis and left sacroiliitis grade II. (Figure 4).

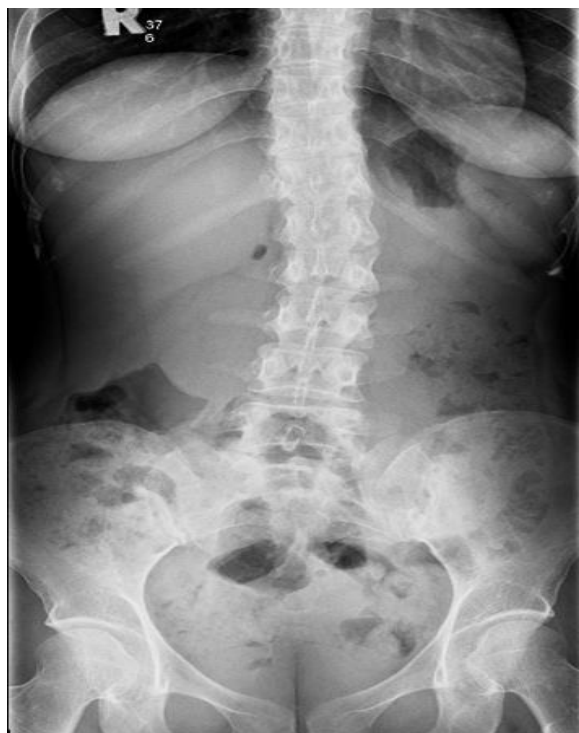

Figure 4

The patient was diagnosed with Rheumatoid Arthritis based on the 2010 ACR/EULAR diagnostic criteria, overlapping with Psoriatic Arthritis syndrome based on the 2010 ASAS

diagnostic criteria for spondyloarthropathy 2006 CASPAR for PsA. The patient has been treated with Methotrexate 12.5 mg orally every seven days, folic acid 5 mg every seven days orally, methylprednisolone 4 mg every 8 hours orally. The Dermatology department was diagnosed with severe psoriasis Vulgaris with additional vitamin B complex therapy one tablet every 24 hours orally, dexamethasone 25% ointment every 12 hours topically, CTM 4 mg tablets every 8 hours orally.

## DISCUSSION

Psoriatic Arthritis (PsA) is part of seronegative spondyloarthropathies that target the spine, peripheral joints, and periarticular structures.<sup>2</sup> Psoriasis, obesity, smoking, and alcohol are risk factors for PsA.<sup>3</sup> While Rheumatoid Arthritis (RA) is an autoimmune disease characterized by chronic and progressive systemic inflammation, the main target of the joints.<sup>4</sup> Female gender, older age, family history, smoking, environmental exposure, and obesity are risk factors for RA.<sup>5</sup>

In this case, according to the patient's risk factors, the patient was a 33-year-old female patient with a history of psoriasis accompanied by arthritis. The most common RA is symmetrical polyarthrititis of the small joints of the hands. On physical examination, rheumatoid nodules can be found in 20% of cases. A 'boutonniere' deformity and a swan neck may be found in more severe diseases. Clinically and biopsy-proven. Psoriasis symptoms are mostly found before the appearance of arthritis symptoms, but a small portion can appear with or even after arthritis.<sup>6</sup>

From laboratory tests, RA can be confirmed by RF serology and ACPA. RF serologic examination was positive in 75% of cases, while ACPA was positive in 50%. ESR and CRP examinations were often elevated as markers of the active phase of arthritis.<sup>7</sup> While PsA was not specific in laboratory tests.<sup>6</sup>

On Rontgen, Boutonniere deformity and swan neck are pathognomonic for RA.

In PsA, the appearance of bone and cartilage destruction with eccentric erosions and joint space narrowing, accompanied by new bone formation, is characteristic. Pencil-in-cup deformity can also be seen in severe PsA. On PsA MRI shows synovitis of bone and joint erosion, bone marrow edema, spondylitis, periarticular inflammation, active enthesitis. At the same time, Doppler ultrasound can reveal synovitis, increased blood flow, tenosynovitis, endophytes, and early phase of bone erosion.<sup>8</sup>

In this case, according to the 2010 American College of Rheumatology/European League Against Rheumatism (ACR/EULAR) criteria, this patient met the definitive criteria for RA with a total score of 7. Since the appearance of Psoriasis Vulgaris in the last six months and the presence of arthritis with multiple spondyloarthropathies, the patient met the Classification for Psoriatic Arthritis (CASPAR) 2006 for psoriatic arthritis with joint pain/arthritis accompanied by psoriasis, dactylitis, and pitting nails on both toes. Therefore, the patient was diagnosed with Rheumatoid Arthritis, overlapping syndrome with Psoriatic Arthritis, and Psoriasis Vulgaris.<sup>9</sup>

Patients treated with Methotrexate 12.5 mg every seven days orally, Methotrexate is one of the conventional synthetic disease-modifying anti-rheumatic drugs (DMARD) for the treatment of RA. Methotrexate reduces disease activity and improves the quality of life in RA and PsA patients. The patient was also given methylprednisolone 4 mg every 8 hours orally. Based on the analysis of Merola et al. in 2018, Corticosteroid administration is still recommended and has benefits in the management of both PsA and RA.<sup>10</sup> However, discontinuation is said to cause recurrence of severe psoriatic lesions, so a gradual dose reduction is recommended.

## CONCLUSION

Rheumatoid arthritis with the overlapping syndrome of psoriatic arthritis has a fairly similar clinical manifestation,

but the pathogenesis is different. Both involve presenting with arthritis symptoms. The right diagnosis process speeds up the time for initiation of appropriate therapy to improve quality of life and improve disease prognosis. The management of both conditions is the administration of both synthetic and biologic DMARDs. Methotrexate is the first line of therapy for PsA and RA. Corticosteroids are still the treatment of choice for both PsA and RA.

**Acknowledgement:** None

**Conflict of Interest:** None

**Source of Funding:** None

## REFERENCES

1. Merola, J. F., Espinoza, L. R. & Fleischmann, R. Distinguishing rheumatoid arthritis from psoriatic arthritis. *RMD Open* 4, e000656 (2018).
2. Albar, Z. Arthritis Psoriatic. in *Buku Ajar Ilmu Penyakit Dalam PAPDI 3173–3175* (Interna Publishing, 2014).
3. Suarjana, I. N. Arthritis Reumatoid. in *Buku Ajar Ilmu Penyakit Dalam PAPDI 3130–3150* (Interna Publishing, 2014).
4. Scotti, L., Franchi, M., Marchesoni, A. & Corrao, G. Prevalence and incidence of psoriatic arthritis: A systematic review and meta-analysis. *Seminars in Arthritis and Rheumatism* 48, 28–34 (2018).
5. Perhimpunan Reumatologi Indonesia. *Diagnosis dan Pengelolaan Arthritis Reumatoid*. (Perhimpunan Reumatologi Indonesia, 2014).
6. Perhimpunan Reumatologi Indonesia. *Rekomendasi Perhimpunan Reumatologi Indonesia (IRA) untuk Spondiloartropati*. (Perhimpunan Reumatologi Indonesia, 2014).
7. Safiri, S. et al. Global, regional and national burden of rheumatoid arthritis 1990–2017: a systematic analysis of the Global Burden of Disease study 2017. *Ann Rheum Dis* 78, 1463–1471 (2019).
8. Nainggolan, O. Prevalensi dan Determinan Penyakit Rematik di Indonesia. *Majalah Kedokteran Indonesia* 59, 588–594 (2009).
9. Ogdie, A. & Gelfand, J. M. Clinical Risk Factors for the Development of Psoriatic

- Arthritis Among Patients with Psoriasis: A Review of Available Evidence. *Curr Rheumatol Rep* 17, 64 (2015).
10. CDC. Rheumatoid Arthritis. CDC (2020).
  11. Coates, L. C., FitzGerald, O., Helliwell, P. S. & Paul, C. Psoriasis, psoriatic arthritis, and rheumatoid arthritis: Is all inflammation the same? *Seminars in Arthritis and Rheumatism* 46, 291–304 (2016).
  12. Chaugan, K., Jandu, J., Goyal, A., Bansal, P. & Al-Dhahir, M. A. Rheumatoid Arthritis. (StatPearls Publishing LLC, 2020).
  13. Ritchlin, C., Colbert, R. A. & Gladman, D. Psoriatic Arthritis. *N Engl J Med* 376, 957–970 (2017).
  14. Husni, M. E. Comorbidities in Psoriatic Arthritis. *Rheumatic Disease Clinics of North America* 41, 677–698 (2015).
- How to cite this article: Carissa Ayu Zebadiah Rau, Gede Kambayana. Diagnostic challenges and management of patients with overlapping rheumatoid arthritis with psoriatic arthritis: a case report. *International Journal of Research and Review*. 2022; 9(3): 222-227. DOI: <https://doi.org/10.52403/ijrr.20220326>

\*\*\*\*\*