

# Remodeling and Reverse Repositioning of the Septal Cartilage in Cases of Secondary Atrophic Rhinitis due to Deviated Nasal Septum

Sumit Sharma<sup>1</sup>, Suvarna Sharma<sup>2</sup>

<sup>1</sup>Associate Professor, Department of E.N.T., Mayo Institute of Medical Sciences, Barabanki.

<sup>2</sup>MBBS 3rd Year Student, KMC, Manipal.

Corresponding Author: Sumit Sharma

## ABSTRACT

**Background:** Atrophic Rhinitis is sometimes referred to as coryza foetida is a chronic disease of the nose which is characterized by progressive atrophy of the nasal mucosa and underlying bone of the turbinates and the presence of a viscid secretion which emits a characteristic foul odor sometimes called ozaena (a stench). A special condition of secondary atrophic rhinitis is gross deviation of nasal septum which causes excessive airflow on the opposite side of the deviation resulting in unilateral Atrophic Rhinitis is being discussed in the present study.

**Method:** In the present study a new method of treatment was used in which the removed cartilage after doing mucosal resection operation of the nasal septum was remodeled and repositioned in the nose.

**Results:** The standard line of therapy in such cases is to do the Sub mucosal resection operation of the nasal septum and follow up the patients with standard postoperative medical therapy of Atrophic Rhinitis. The postoperative rehabilitation time is significantly large (more than a year) which is sometimes not possible due to compliance and the disease persists even after surgery. We remodeled and placed the cartilage back in the septum in reverse position (convexity to opposite side) and found good results in recovery of regeneration of the mucosa.

**Conclusion:** Removal of the septal cartilage after doing mucosal resection operation of the nasal septum, remodeling and repositioned in the nose improves results of the operation and helps in recovery of secondary Atrophic Rhinitis faster than if not done so.

**Keywords:** Atrophic Rhinitis, Secondary Atrophic Rhinitis, cartilage Repositioning

## INTRODUCTION

Atrophic Rhinitis is a chronic disease of the nose which is characterized by progressive atrophy of the nasal mucosa and underlying bone of the turbinates and the presence of a viscid secretion which emits a characteristic foul odour sometimes called ozaena (a stench). There is an abnormal patency of the nasal passages. It was known to the ancient Greek, Indians and Egyptian civilizations. Now a days because of the improved socioeconomic conditions, its incidence in western countries has declined whereas in Asia, Africa, Eastern Europe, Egypt, Greece, Hungary, Yugoslavia, India, Malaysia and Philippines<sup>1,2</sup>

Atrophic Rhinitis is sometimes referred to as coryza foetida, atrophic catarrh, rhinitis atrophicans, acute necrotizing rhinitis or rhinitis chronica foetida.<sup>3,4</sup> The primary form of the disease is also known as 'ozaena' (a stench) because of the characteristic foul smell emanating from the nasal passage. The incidence varies from 0.3-7.8% of otolaryngology outpatients<sup>5</sup>

Traditionally Atrophic Rhinitis has been divided into Primary where the etiology remains unknown but factors like Hereditary, Endocrine imbalance, Racial factors, Nutritional deficiencies, and Autoimmune conditions play a role and

**SECONDARY** where conditions like trauma, surgery, granulomatous diseases like syphilis / leprosy / rhinoscleroma, Infections like chronic sinusitis, and radiation exposure and are directly related to the cause of the disease.

A special condition of secondary atrophic rhinitis is gross deviation of nasal septum which causes excessive airflow on the opposite side of the deviation resulting in unilateral Atrophic Rhinitis is being discussed in the present study.

## MATERIAL AND METHOD

**Study type** – Innovative surgical procedure for Secondary Atrophic Rhinitis

**Study place** - Department of Otorhinolaryngology of Mayo Institute of Medical Sciences, Gadia, Barabanki

**Study Period** - January 2015 to January 2017

**Ethical approval** - The study is approved by the Institutional Ethical Committee

**Statistical analysis** – Standard Statistical analysis was done

**Selection criteria of the patients** - Patients with Unilateral Secondary Atrophic Rhinitis due to excessive deviation of the nasal septum were considered in the study. All other causes of unilateral secondary atrophic rhinitis like trauma, surgery, granulomatous diseases like syphilis / leprosy / rhinoscleroma, Infections like chronic sinusitis, and radiation exposure were eliminated and were not considered. No patients of primary atrophic rhinitis and bilateral atrophic rhinitis was taken in the study.

## Procedure

After proper investigations, all the patients were operated under general anesthesia endoscopically.

**Surgical steps: Group A patients:** A classical Sub mucous resection operation was done in all the cases taking precaution to remove the septal cartilage as a single block. Other portions of the deviated nasal septum like the bony parts and the maxillary crest were corrected as and when needed.

The removed septal cartilage after smoothing and remodeling was replaced back in the nose inversely (If initially the convexity was to the left side and atrophic rhinitis towards right side, the repositioned septal cartilage will now have a slight convexity towards right side and vice versa) as described below.

**Group B patients:** everything remained the same except the removed cartilage was not placed back in the septum.

All the patients were evaluated clinically for Presence or absence of Fetor, crusting and atrophy of the mucosa, mucosal regeneration endoscopically and sinus opacity on radiology. Patients were followed up for 1 year and observations were made at 3 months, and 6 months interval.

All the patients of both the group were put on standard postoperative therapy of Atrophic Rhinitis like Alkaline nasal solution douching, 25% glucose with glycerine intermittent packing, intranasal application of Kemicetine antiozaena solution (containing chloromycetin), and nutritional supplements were also given.

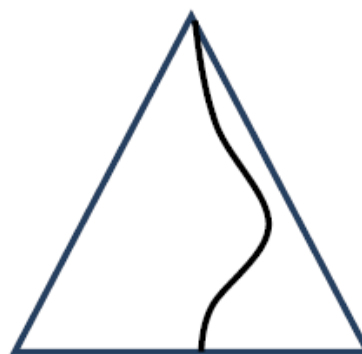


Fig-1: DNS towards left with atrophic rhinitis to the right cartilage

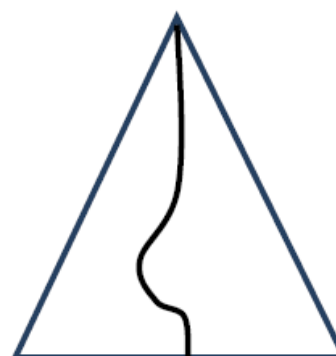

Fig-2: Removal and inverse repositioning of the side

## OBSERVATIONS

**Table – 1: Evaluation after 3 Months**

Criteria	GROUP A (n=20)	GROUP B (n=20)
Fetor	Present but Reduced(N=18)	Present but Reduced (N=8)
Crusting	Present but Reduced (N=15)	Present But Reduced (N= 8)
Atrophy	Present but Reduced (N=12)	Present but Reduced (N=6)
Endoscopic Findings	Mucosal Regeneration Appreciated (N=10)	Mucosal Regeneration Appreciated (N= 3)
Radiology (X-Ray)	Sinus Opacity Reduced. (N=14)	Sinus Opacity Reduced. (N=6)

**Table – 2: Evaluation after 6 Months**

Criteria	GROUP A (n=20)	GROUP B.(n=20)
Fetor	Absent (n=20)	Present but Reduced (n=12)
Crusting	Present but Reduced (n=18)	Present but Reduced (n=12)
Atrophy	Present but Reduced (n=15)	Present but Reduced (n=12)
Endoscopic Findings	Mucosal Regeneration Appreciated (n=15)	Mucosal Regeneration Appreciated (n=8)
Radiology(X-Ray)	Sinus Opacity Reduced (n=18)	Sinus Opacity Present (n=10)

## DISCUSSION

Atrophic Rhinitis is a chronic debilitating disease of the nasals mucosa in which the nasal mucosa is replaced with squamous epithelium. It remains a challenge for the specialist to treat the condition as the medical and surgical therapy have limited response moreover surgeries are also sometimes disfiguring. Atrophic rhinitis is a disease known since biblical times. AR is usually seen between the age group of first decade to sixth decade of life and is common in females<sup>5</sup>. In the present study we discuss a special situation of secondary atrophic rhinitis which is caused by Deviated nasal septum and is always unilateral to the opposite side of the deviation of the septum. The standard line of therapy in such cases is to do the Sub mucosal resection operation of the nasal septum and follow up the patients with standard postoperative medical therapy of Atrophic Rhinitis. The postoperative rehabilitation time is significantly large (more than a year) which is sometimes not possible due to compliance and the disease persists even after surgery. In the present study we remodeled the excised septal cartilage to reduce the extent of deviation present in it and repositioned it in the septum, this produces slight deviation towards the side of the Atrophic Rhinitis in the nose which significantly reduces the airflow from the side of atrophy which is said to be the primary cause of atrophy in such cases. Remodeling of the excised septum is essential as we should not create a

roomy cavity on the opposite side as this may cause development of atrophic rhinitis on the healthy side. Following criteria's we adopted to evaluate the response to therapy - Presence or absence of Fetor, crusting and atrophy of the mucosa, mucosal regeneration endoscopically and sinus opacity on radiology and observations were made after 3 months and 6 months.

**After 3 months:** In group A patients Fetor was reduced in 90% patients, crusting was reduced in 75% patients, atrophy was reduced in 60% patients, mucosal regeneration was seen in 50% patients and radiologically sinus and nasal opacity was reduced in 70% cases. Where as in Group B patients Fetor was reduced in 40% patients, crusting was reduced in 40% patients, atrophy was reduced in 30% patients, mucosal regeneration was seen in 15% patients and radiologically sinus and nasal opacity was reduced in 30% cases only.

**After 6 months:** In group A patients Fetor was reduced in 100% patients, crusting was reduced in 90% patients, atrophy was reduced in 75% patients, mucosal regeneration was seen in 75% patients and radiologically sinus and nasal opacity was reduced in 90% cases. Where as in Group B patients Fetor was reduced in 60% patients, crusting was reduced in 60% patients, atrophy was reduced in 60% patients, mucosal regeneration was seen in 40% patients and radiologically sinus and nasal opacity was reduced in 50% cases only.

Thus it becomes evident that if we reduce the airflow on the side of atrophic rhinitis in cases of unilateral secondary atrophic rhinitis which is caused by Deviated nasal septum the recovery of the nasal atrophy is much faster and is recommended. Most of the surgeries of atrophic rhinitis are aimed at reducing the airflow to the nasal cavity on the effected side to allow time to eliminate infection and recovery of the nasal mucosa which has been replaced by squamous epithelium as we have seen that if we change the environment then mucosal regeneration occurs, and in this situation of secondary atrophic rhinitis which is caused by Deviated nasal septum this appears to be the most legitimate alternative to hasten recovery.

Although no such study is known to the author so far, hence the present research cannot be compared to any such previous study for the results.

#### **Limitation of the Study**

The procedure has shown good results in our study but long term results and a study on a greater number of patients needs to be done.

#### **CONCLUSION**

Correction of the Deviation remains a standard treatment for unilateral atrophic rhinitis caused by excessive deviation of the nasal septum. This procedure alone just stabilizes the airflow between the two nasal cavities and the time taken for the recovery of the nasal mucosa and other structures is very long after the procedure, hence we have observed that if we place the removed deviated segment of the septal cartilage back in the nasal cavity after modulation an inversely i.e. if initially the convexity was to

the left side and atrophic rhinitis towards right side, the repositioned septal cartilage will now have a slight convexity towards right side and vice versa) the recovery time of the atrophic side is much faster as compared to if do not do so. This reduces the airflow on the atrophic side thus fastens the recovery. The modulation (resizing the removed cartilage) is important so that we do not cause atrophic rhinitis on the healthy side.

#### **Declaration**

**Funding:** None

**Conflict of interest:** None declared

#### **BIBLIOGRAPHY**

1. Goodman WS, De Souza FM (1973) Atrophic rhinitis. *OtolaryngolClin North Am* 6: 773-782.
2. Goodman WS, D'souza FM (1989) Atrophic Rhinitis. *Gerald M English Pub Lippincott* 2: 14
3. Loch WE, Loch WE, Reiriz HM. Acute necrotizing rhinitis in man. *Rhinology* 1978; 16:235-42
4. Nielsen BC, Olander-Nielsen AM, Malmberg AS. Successful treatment of ozena with ciprofloxacin. *Rhinology* 1995; 33:57-60
5. Suja S Sreedharan, Vishnu Prasad\*, Vijendra S Shenoy and Panduranga M Kamath - A Clinical Study on Atrophic Rhinitis, Its Management and Surgical Outcome - *International Journal of Research In Medical Sciences - Volume 3 • Issue 1 • 155*

How to cite this article: Sharma S, Sharma S. Remodeling and reverse repositioning of the septal cartilage in cases of secondary atrophic rhinitis due to deviated nasal septum. *International Journal of Research and Review*. 2021; 8(2): 446-449.

\*\*\*\*\*