

# Cadaveric Study of Anatomical Variations of Renal Arteries

Pitta Venkata Chandrika<sup>1</sup>, Lakshmi Durga Jakka<sup>2</sup>

<sup>1,2</sup>Assistant Professor, Department of Anatomy, Siddhartha Medical College, Vijayawada.

Corresponding Author: Pitta Venkata Chandrika

## ABSTRACT

**Introduction:** Anatomical variations of renal artery are important to prevent complications during renal transplant surgery or renal angiography. Of this additional renal artery is the most common.

**Materials and methods:** The present study was conducted in 80 kidneys of 40 adult human cadavers in Department of Anatomy, Siddhartha Medical College, Vijayawada over a period of 4 years (2017 to 2021) during educational dissections.

**Results:** Accessory renal arteries are observed in the present study. Origins of these accessory renal arteries are noted along with their entry point into the kidneys. These results were compared with previous studies.

**Conclusion:** Prior knowledge of these variations is important to prevent complications during surgical and angiographic interventions.

**Keywords:** Renal arteries, Accessory renal artery, Aberrant renal artery, Upper pole, Lower pole, Hilum

## INTRODUCTION

Blood supply to the kidneys is characterized by more frequent presence of variations in arteries and veins supplying them. In view of these variations of arteries supplying to the kidneys it is necessary to have prior knowledge of them as now a day's more number of patients is undergoing renal transplants or angiography procedures. The knowledge of these variations is also useful for treatment of renal trauma and tumors. Normally each kidney is supplied by single renal artery and

drained by single vein. Frequently seen anatomical variation is additional renal artery. Additional renal artery can be accessory or aberrant renal artery. An accessory renal artery is accessory to the main renal artery, usually arising from the abdominal aorta and entering the kidney through hilum and aberrant renal artery is the one which enters the kidney through either pole whether it is derived from main renal artery, aorta or a branch of abdominal aorta. Branching of main renal artery into anterior and posterior divisions proximal to the hilum is called early division.

## MATERIALS AND METHOD

The present study was conducted in 40 embalmed adult human cadavers dissected during regular academic dissection classes in the Department of Anatomy, Siddhartha Medical College (Govt.), Vijayawada over a period of 4 years (2017 to 2021). Abdomen is dissected as per Cunningham's manual and kidneys were exposed. Renal arteries and veins were identified and traced entirely from their origin. Anomalies like additional renal arteries and abnormal branching of these arteries were observed carefully and recorded.

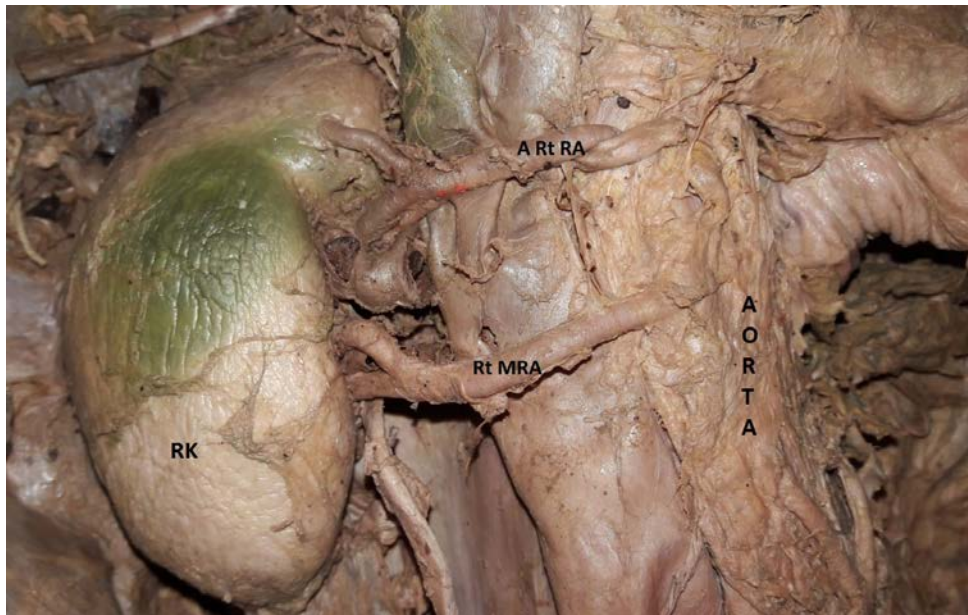
## RESULT

Among the 36 adult human cadavers (72 kidneys) which were dissected, 52 (72.2%) kidneys show normal single renal artery. Remaining 20 (27.7%) kidneys show additional renal arteries, either accessory or

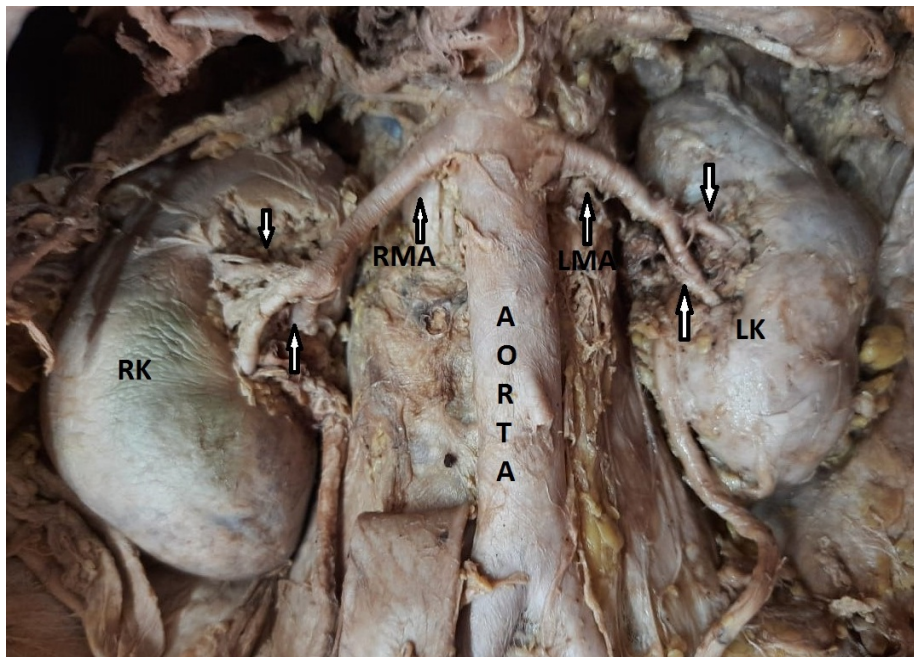
aberrant renal arteries. 16 kidneys show unilateral additional renal arteries, out of which 7 are right sided and 9 are left sided.

Only 2 cadavers (4 kidneys) show bilateral additional renal arteries.

Early or prehilum division of main renal artery noted in 9 kidneys (12.5%).



**Figure 1: Shows accessory renal artery arising from aorta on right side.**  
 RK : Right Kidney, Rt MRA : Right Main Renal Artery, A Rt RA : Accessory, Right Renal Artery



**Figure 2: Shows bilateral prehilum division of main renal arteries.**  
 RK: Right Kidney, RMA: Right Main Renal Artery, LK: Left Kidney, LMA: Left Main Renal Artery

**Table 1: Table showing number of accessory renal arteries**

Total no. of specimens	Total no. of specimens showing single renal arteries	Total no. of specimens showing accessory renal arteries
72	52 (72.2%)	20 (27.7%)

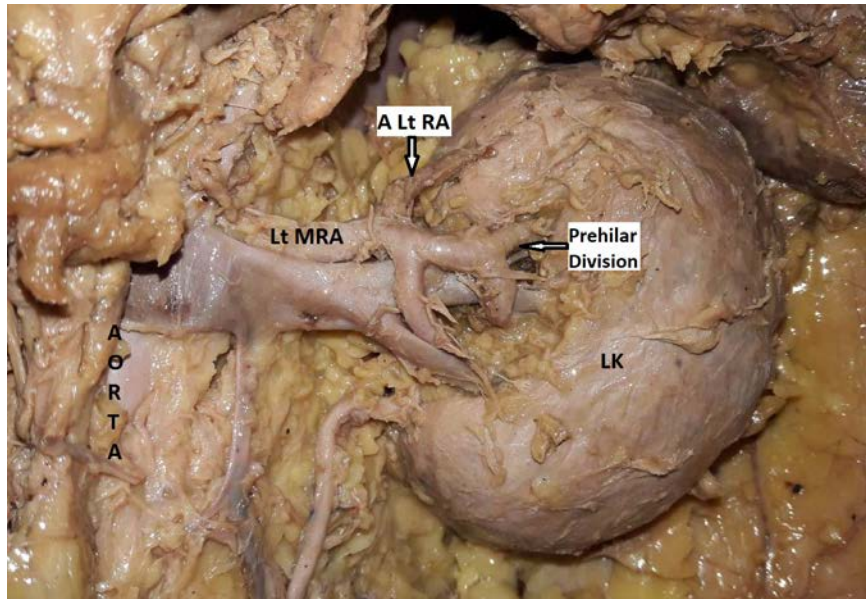


Figure 3: Shows aberrant renal artery arising from left main renal artery and entering superior pole of left kidney along with prehilum division of left main renal artery.

LK: Left Kidney, A Lt RA: Aberrant Left Renal Artery, Lt MRA: Left Main Renal Artery,

Table 2: Table showing number of renal artery variations

No of additional renal arteries	Origin of additional renal arteries		Branching pattern		
	From aorta	From main renal artery	Towards hilum (accessory)	Towards upper pole (aberrant)	Towards lower pole (aberrant)
Right (9)	8	1	5	2	2
Left (11)	10	1	8	1	2

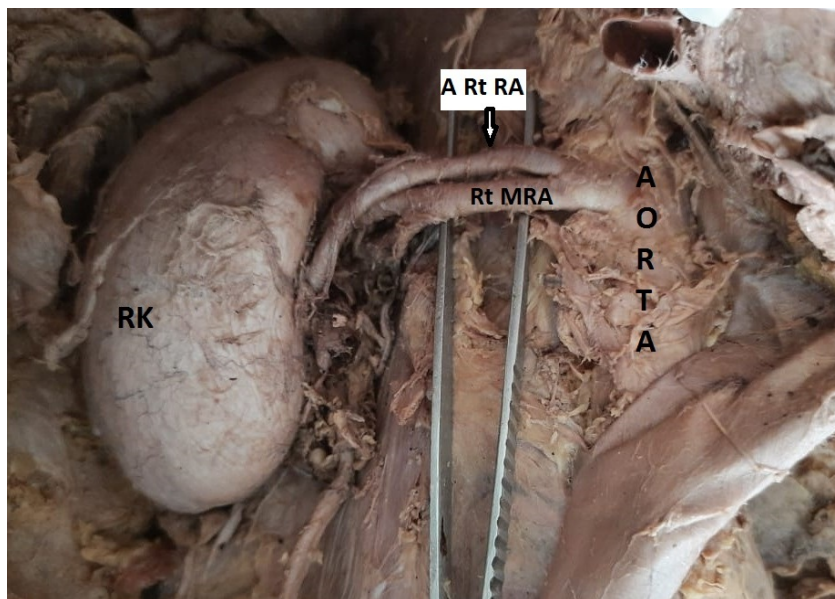
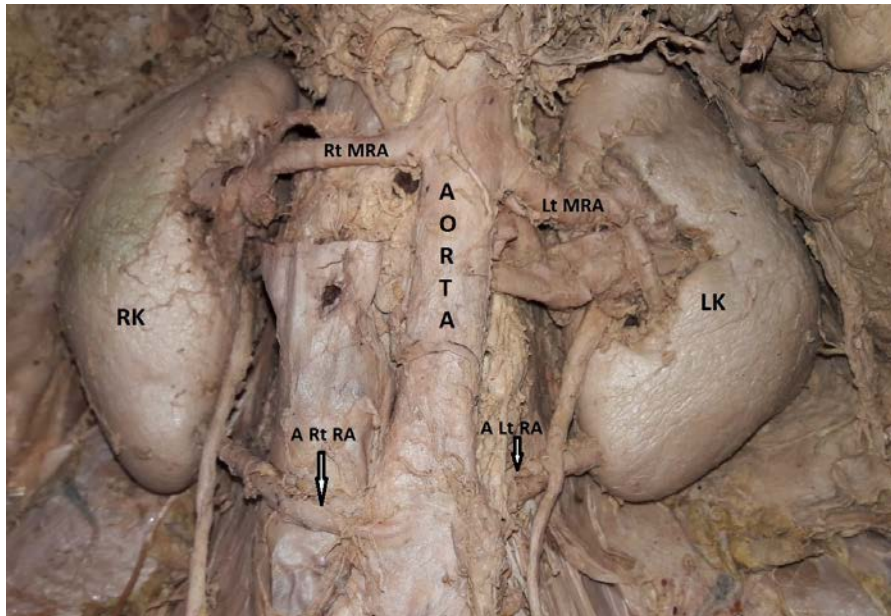


Figure 3: Shows accessory renal artery arising from right main renal artery and entering hilum of right kidney.

RK : Right Kidney, Rt MRA: Right Main, Renal Artery, A Rt RA: Accessory Right Renal Artery

Out of the total 20 specimens showing additional renal arteries noted in this study 18 (25%) are noted originating from aorta directly and 2 (2.8%) are noted arising from main renal artery. In this study 3 (4.16%) aberrant renal arteries are noted

entering the kidney at upper pole region, 13 (18.1%) accessory renal arteries are noted entering at hilum and 4 (5.6%) aberrant renal arteries are noted entering at lower pole region.



**Figure 5: Shows bilateral aberrant renal arteries arising from aorta and entering lower poles of both kidneys.**

*RK: Right Kidney, LK :Left Kidney, Rt MRA: Right Main Renal Artery, A Rt RA: Aberrant Right Renal Artery, Lt MRA: Left Main Renal Artery, A Lt RA: Aberrant Left Renal Artery.*

## DISCUSSION

There are many studies published in the literature describing morphological and anatomical variations of the renal artery. Accessory renal arteries were first described by Eustachius in 1552 (1) on copper plates as published by Lancisi in 1714 (2). Each kidney is supplied by single renal artery in 70% of individuals which arises from abdominal aorta laterally at the level of L1-L2 intervertebral disc and accessory renal arteries are noted in 30% of individuals (3).

Merklin and Michels (4) classified supernumerary arteries or additional renal arteries based on the origin as

1. Supernumerary renal arteries originating from aorta
2. Supernumerary renal arteries originating from main renal arteries
3. Supernumerary renal arteries originating from other sources

Felix (5) gave embryological explanation to these variations. During fetal period when embryo is 18 mm in length the developing mesonephros, metanephros, supra renal glands and gonads are supplied by nine pairs of lateral mesonephric arteries of dorsal aorta origin. According to Felix the 1<sup>st</sup> and 2<sup>nd</sup> arteries are grouped as cranial, 3<sup>rd</sup> to 5<sup>th</sup> as middle and the 6<sup>th</sup> to 9<sup>th</sup>

as caudal group. The middle group arteries later develop into renal arteries. Accessory renal arteries result from the persistence of more than single artery from middle group.

There are many studies published in the literature describing morphological and anatomical variations of the renal artery. Various studies illustrate accessory renal arteries are noted in addition to main renal artery with variable site of origin and variable entry site into renal parenchyma. According to Gumus et al accessory renal artery is predominant in males, but other studies published showed no sex preference. Accessory renal arteries are frequently noted on left side. Accessory renal artery is the most common anatomical variation followed by early bifurcation (6). Accessory renal artery is most commonly originated from abdominal aorta at level L1 & L2. (7)

According to Ramesh Rao et al study renal artery variations occur in 30% of population (8). According to Lippert et al. study, accessory renal arteries are reported in 26% of individuals. (9). Accessory renal artery is noted in 12 kidneys (24%) out of 25 cadavers according to study done by R Chitra (10). According to study done by Archana Srivastava et al (11) accessory renal arteries were observed in 25% of

kidney specimens and is same in both sexes. These are seen in 26% kidneys on right side and 24% on left side. In this study single renal artery was found in 71.5% and two accessory renal arteries in 3.5% of kidneys. Saldarriaga et al (12) in their study noted single accessory renal artery in 22.3% and two accessory renal arteries in 2.6% of kidneys. Talovic et al (13) reported accessory renal arteries arising from aorta in 30.76% cases and from renal arteries in 12.82% in their study. According to study done by Virendra Budhiraja et al (6) supernumerary renal arteries were present in 62.2% cases (48.6% of aortic origin and 13.5% of renal origin) on right side and 56.8% cases (45.9% of aortic origin and 10.8% of renal origin) on left side. Occurrence of triple renal arteries is rare and reported in 2% cadavers in study done by Ogengo et al. In the study done by Lama CP et al (14) main single renal artery arising from abdominal aorta is noted in 80% on both sides, additional renal arteries were noted in 20%, either from main renal artery (66.66%) or from abdominal aorta (33.33%) and early division of main renal arteries were noted in 16.66% on both sides. Ankolekar et al reported 6.67% occurrence of bilateral supernumerary arteries in their study.

According to Mustafa et al (15) accessory renal arteries enter the kidneys at upper pole in 15.3%, at lower pole in 58.9% and at hilum in 23% on right side where as on left side it enters at upper pole in 29.2%, at lower pole in 55.3% and at hilum in 13.8%.

Pre hilar division of renal artery is noted in 75% of kidneys according to Sarfraz et al study (16), in 81.6% according to Daescu E et al study (17) and in 47.5% according to Budhiraja V et al study (6).

Presence of more than two accessory renal arteries is considered as contraindication in donor transplant surgery (18). Transplantation of kidney with accessory renal artery is difficult and complication rate is more compared to kidney with single renal artery. The course

of upper polar and lower polar aberrant renal arteries originating from renal artery will have a more vertical course compared to those arising from aorta. This can cause polar infarction during intraoperative kidney mobilization due to injury of these accessory arteries (19). In addition, lower polar accessory renal arteries can cause ureteropelvic junction obstruction due to its abnormal course (20).

## CONCLUSION

Normally each kidney is supplied by single renal artery. Accessory renal artery is the most common anatomical variation of renal artery. Thorough prior knowledge of this anatomical variation is necessary to prevent damage to the kidney during transplantation, angiographic procedures and during renal surgeries.

**Acknowledgement:** None

**Conflict of Interest:** None

**Source of Funding:** None

## REFERENCES

1. Eustachiaius B. The aberrant renal arteries. *Journal of Anatomy*. 1552; 90:553-558.
2. Lancisi. An unusual anomalous blood vessel connecting the renal and internal spermatic arteries. *Anatomical record*. 1724; 102:205-210.
3. Standring S (Editors). *Gray's anatomy: The Anatomical basis of clinical practice*. 40<sup>th</sup> edition. Churchill Livingstone. 2008, pg 1225-1244.
4. Merklin RJ, Michels NA. The variant renal and suprarenal blood supply with data on the inferior phrenic, ureteral and gonadal arteries: a statistical analysis based on 185 dissections and review of literature. *The journal of international college of surgeon*. 1958; 29-1: 41-76.
5. Felix WN. *Manual of human embryology*. Kiebel and Mall. 1912; 2<sup>nd</sup> ed; 883
6. Budhiraja V, Rastogi R, Vaibhav Anjankar et al. Anatomical variations of renal artery and its clinical correlations: a cadaveric study from central India. *Journal of*

- Morphological sciences. 2013; Vol. 30 (4), p 228-233
7. Peter B J, Shamir OC, Sundeep DS et al. Accessory renal arteries in Caribbean population : a computed tomography based study. Springer 2013; 2:443
  8. Ramesh Rao T, Rachana. Aberrant renal arteries and its clinical significance: A case report. International journal of anatomical variations. 2011; 4:37-39.
  9. Lippert H, Pabst R. Arterial variations in man, classifications and frequency. Springer Vrerlag; 1985: Munich.
  10. R Chitra. A study of various types of accessory renal arteries. International journal of anatomy and research. 2016; Vol4(3):2522-2525
  11. Archana Srivastava, Jyoti Chopra, Garima Sehgal et al. ERA's journal of medical research; DOI:10.24041/ejmr2018.74
  12. Saldarriaga B, Perez SA, Ballesteros LE, et al. A direct anatomical study of additional renal arteries in Colombian Mestizo population. Folia Morphologica (Warsz) 2008; 67: 129-34.
  13. Talovic E, Kulenovic A, Voljevica A, Kapur. Review of supernumerary arteries by dissection methods. Acta Medica Academica. 2007; vo.36 p 56-69.
  14. Lama CP, Pradhan A. Variations of renal artery in cadavers. Nepal medical college journal. 2019; 21(3):214-219).
  15. Mustafa AbdulMonamZainel, Suhelmawloodalnajjar. Incidence and variations of aberrant renal arteries in kidney donor cases. DOI Number:10.37506/v20/il/2020/mlu/194361.
  16. Sarfraz R, Tahir M, Sami W. Presegmental arterial pattern of human kidneys in local population. Annals of Pakistan institute of Medical sciences. 2008; Vol 4(2) p 212-215.
  17. Daescu E, Zahoi DE, Motoc A et al. Morphological variability of renal artery branching pattern: a brief review and anatomical study. Romanian journal of Morphology and Embryology. 2012; Vol 53 (2) p 287-291.
  18. Sebastia C, Peri L, Salvador R et al. Multidetector CT of living donors: lesson learned from surgeon. Radiographics. 2010; 30(7): 1873-90.
  19. Sampaio FJ and Passos MA. Renal arteries: Anatomic study for surgical and radiological practice. Surgical and Radiological anatomy. 1992; Vol. 14(2) p 113-117.
  20. Shoja MM, Tubbs RS, Shakeri A et al. Asymptomatic bilateral ureteropelvic junction obstruction due to supernumerary renal arteries. Saudi journal of kidney disease and transplantation. 2008; Vol. 19(5) p 806-808.

How to cite this article: Pitta Venkata Chandrika, Lakshmi Durga Jakka. Cadaveric study of anatomical variations of renal arteries. *International Journal of Research and Review*. 2021; 8(12): 418-423. DOI: <https://doi.org/10.52403/ijrr.20211251>

\*\*\*\*\*