

# Branchial Sinus with Cyst - Two Case Reports with Review of Literature

Ashoka Nand Thakur<sup>1</sup>, Priyambada<sup>2</sup>

<sup>1</sup>M.B.B.S., M.S. (Surgery), M.Ch. (Paediatric Surgery), <sup>2</sup>M.B.B.S., M.D.(Pathology),  
Assistant Professor & Head of Department, Department of Paediatric Surgery,  
Patna Medical College & Hospital, Patna, Bihar

Corresponding Author: Ashoka Nand Thakur

## ABSTRACT

Branchial cleft anomalies are well described, with the second arch anomaly being the commonest. Remains of cervical sinus of His may persist as a branchial cyst. A branchial sinus is formed when 2nd branchial arch fails to meet the 5th pharyngeal arch.

Peak age for presentation of branchial cysts is in the third decade and that of the congenital sinuses and fistulae is at birth. The association of a branchial cyst with branchial sinus is very rare. We are presenting two cases had branchial cyst along with branchial sinus. It was managed successfully with complete excision. Histopathological examination confirmed the association.

**Key Words:** Branchial Sinus, Branchial cyst

## INTRODUCTION

Ten year old male child presented with swelling in left upper cervical region. It was soft cystic swelling and was gradually increasing in size. There was small sinus opening in lower part of same side of neck also from which there was intermittent discharge. After doing routine hematological examination, Ultrasonography of neck was done. This was showing a linear tract communicating to a cystic lesion. Elliptical incision was taken around sinus opening. The dissection was carried out proximally. It was communicating with a cyst. The sinus tract along with cyst was excised completely.

Another patient of five year old boy had small sinus over lower third of neck anterior to sternomastoid. There was no cystic lump on palpation. The child was operated and again Sinus tract connecting to a cyst and was excised.

## CASE REPORT

**Case 1--** Ten year old boy presented with swelling in left cervical region. It was soft cystic swelling (size 3x3 cm) and was gradually increasing in size. There was history of intermittent discharge from a sinus opening in lower part of left side of neck. The sinogram was attempted but not get completed as the opening was very tiny. The ultrasonography revealed cystic swelling in upper part of neck. Routine blood investigations were within normal limit. The patient was taken for planned surgery. Elliptical incision was taken around sinus opening. Tract was traced and dissection was carried out close to sinus tract. Sinus tract was connected to cyst in the upper part of neck. Dissection was done up to left tonsillar fossa. Sinus tract along with cyst was completely removed. Histopathology showed lining epithelium of squamous cells. The postoperative period was uneventful. Patient is on regular follow up for the last two years without any complications.

**Case 2--** Five year old boy presented with very small discharging sinus at lower part of left side of neck over the anterior border of

sternomastoid. There was no history of fever or cough. The discharge was small in amount and whitish in colour. The Haemogram was within normal limit. Sinogram was not successful. Sonography of neck was not done as there was no palpable lump. Patient was operated in view of branchial sinus but surprisingly there was small cyst at the end of sinus tract. The sinus tract along with cyst was completely excised.

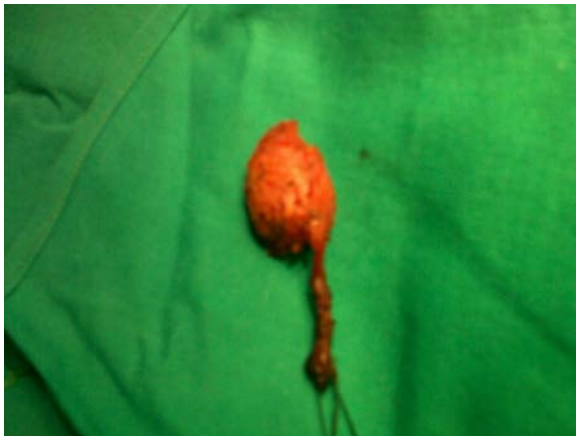

FIGURE LEGEND—1. BRANCHIAL SINUS TRACT WITH CYST

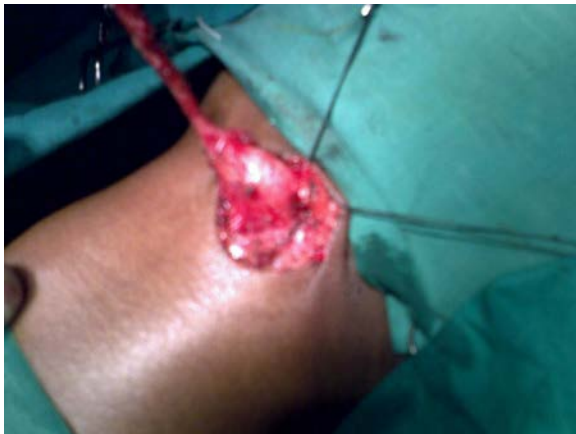

FIGURE LEGEND—2. SINUS TRACT COMMUNICATING WITH CYST

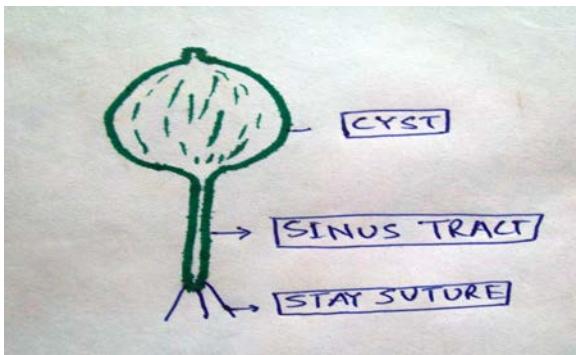


FIGURE LEGEND---3. SCHEMATIC DIAGRAM OF BRANCHIAL SINUS WITH CYST

## DISCUSSION

During development of the neck, the second branchial arch grows caudally and covering the third, fourth and sixth arches and meeting skin caudally to these arches. The growth of second arch is much faster than that of the arches below. So that it soon overhangs them forming a deep groove – the cervical sinus. Normally it disappears completely. When a part of space persists, it forms branchial cyst.

Branchial sinus results from incomplete obliteration of precervical sinus. Normally the small opening of the sinus lies over the anterior border of lower third of sternocleidomastoid. The tract is separated from the pharynx by a septum which represents the remains of cleft membrane. The membrane usually breaks due to its tenacious nature and forms branchial fistula. It extends from the skin to an internal opening in the tonsillar fossa. (2) It passes between external and internal carotid arteries.

The presentation of second branchial cleft anomalies varies. It may be bilateral that ranges from 2-10% (3). The unusual presentation of second branchial anomalies include stridor, pharyngeal cyst causing sore throat, feeling of fullness in the throat, hypo nasal speech, dysphagia or odynophagia, a cold nodule on thyroid scan.(1). It may present as multiple cranial nerve palsy. (4)

Embryologically it is very difficult to describe the association of cyst with sinus. We presume that it may be due to persistence of cervical sinus along with incomplete obliteration of precervical sinus.

## CONCLUSION

Branchial sinus along with cyst is very rare. Embryologically it cannot be defined clearly. Ultrasound of neck should be done in every case as sonogram is not successful due to tiny opening of sinus. The treatment of Branchial sinus and cyst is surgical excision.

**Acknowledgement:** None

**Conflict of Interest:** None

**Source of Funding:** None

#### REFERENCES

1. Sonnino RE, Spigland N, Laberge JM et al: Unusual patterns of congenital neck masses in children. J Pediatric Surgery 1989;24:966
2. Lee McGregor's synopsis of Surgical anatomy- Third Indian reprint 1999, page 177
3. Gatti WM, Zimm J : bilateral branchial cleft fistula: Diagnosis and management of two cases: Ear Nose Throat J 1988;67:256

4. Durrant TJ, Servick RJ,Lauryssen C, MacRae ME:Parapharyngeal branchial cleft cyst presenting with cranial nerve palsies. Can Assoc RadiolJ 1994;45:134

How to cite this article: Thakur AN, Priyambada. Branchial sinus with cyst - two case reports with review of literature. *International Journal of Research and Review*. 2021; 8(11): 375-377. DOI: <https://doi.org/10.52403/ijrr.20211147>

\*\*\*\*\*