

# Osteoid Osteoma of Proximal Phalanx of Right Great Toe: A Rare Entity

B. Syam Sundara Rao<sup>1</sup>, Vissa Shanthi<sup>1</sup>, Nandam Mohan Rao<sup>2</sup>,  
Bhavana Grandhi<sup>2</sup>, Sujitha<sup>3</sup>, Divya Tejaswi Gopidesi<sup>4</sup>

<sup>1</sup>Professor, <sup>2</sup>Associate Professor, <sup>3</sup>Assistant Professor, <sup>4</sup>Tutor,  
Department of Pathology, Narayana Medical College, Nellore (A.P), India

Corresponding Author: B. Syam Sundara Rao

## ABSTRACT

Osteoid osteoma is a benign bone tumor rarely seen in the foot and predominantly affects males in second and third decade of life. This tumor mainly occurs in long bones of lower extremities such as femur and Tibia but hand and foot are considered rare and uncommon sites. We present a 24 year old male with osteoid osteoma involving right great toe who presented with swelling and pain over right great toe.

**Key words:** Osteoid osteoma, benign tumor, great toe

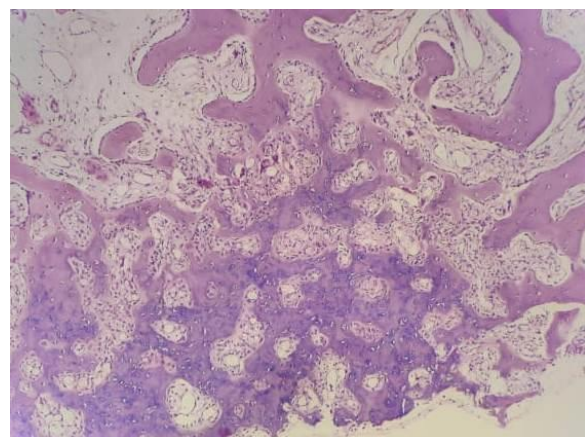
## INTRODUCTION

Osteoid osteoma is a osteoblastic benign bone tumor that was originally described by Bergstrand in 1930. <sup>(1)</sup> Jafee later described that unique entity as benign bone tumor in 1935. <sup>(2)</sup> Males are commonly affected than females in the 2nd and 3<sup>rd</sup> decades of life <sup>(3)</sup> with worsening of pain at night and relieved by NSAIDS. <sup>(4,5)</sup> Osteoid osteomas comprise 10% of benign bone tumors <sup>(6)</sup> with more than 50% of cases involving the tibia or femur. Involvement of foot and hand is rare with phalangeal lesions of foot accounting to 2% of all lesions. <sup>(2)</sup> Few cases have been reported according to literature. Osteoblastoma, Osteosarcoma, osteomyelitis are all in the differential diagnosis of osteoid osteoma in the toes. <sup>(6)</sup> We present a case of osteoid osteoma of great toe in a 23 year old male patient who

had presented with swelling and pain over right great toe.

## CASE REPORT

A 24 year old male patient came to orthopaedics department with complaints of pain and swelling over right great toe for past 2 months. Patient had history of trauma 4 years ago over great toe. Pain was dull aching type, progressive in nature, non radiating associated with night pain and relieved on taking rest and medication. On examination swelling of size 1x1x0.5cm present over dorsomedial aspect of right great toe with immobile, bony consistency. Tenderness present over the swelling on dorsomedial aspect of right great toe on proximal phalanx region.



**Fig-1:** Microscopic examination shows nidus, composed of anastomosing irregular bony trabeculae with frequent osteoclasts and osteoblastic rimming. Nidus surrounded by thick sclerotic bone with intervening fibrovascular stroma.

Basic haematological investigations were unremarkable. Radiographic work up

included plain X ray of the foot and MRI scan. MRI scan revealed well defined T1 hypointense T2 and STIR hyper intense lesion measuring 6x4mm in the dorsal aspect of the proximal phalynx of great toe with adjacent fat stranding. Imaging features suggesting possibility of osteoid osteoma of proximal phalynx of right great toe. Clinical diagnosis based on imaging features made was osteoid osteoma. The patient underwent surgery and excised mass was sent to department of pathology for histopathology examination. Macroscopically shows

multiple grey white bony bits altogether measuring 1x1 cm. Microscopic examination shows lesion composed of irregular mature bony trabeculae with immature bone which is rimmed by osteoblasts. Intervening stroma shows fibroblasts and many congested blood vessels. A final diagnosis of osteoid osteoma was made based on histopathological features. Patient was uneventful and showed good recovery after two months.

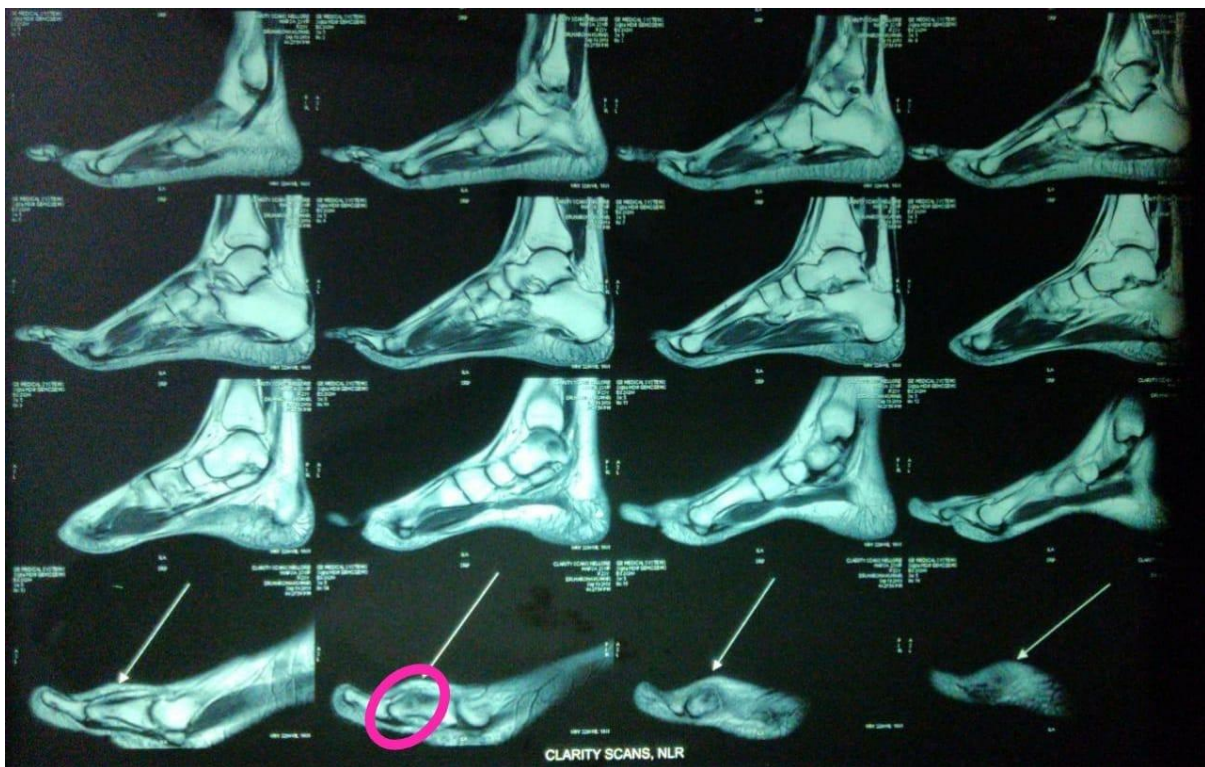

Fig-2: MRI image shows T1 Hypointense, T2 and STIR hyperintense Lesion in the dorsal aspect of the proximal phalanx of the great toe... Suggest the possibility of Osteoid osteoma.

## DISCUSSION

The commonest locations of osteoid osteoma are diaphyseal and metaphyseal regions of long tubular bones comprising 50% of all reported cases. (7) The foot is very rarely involved. Jackson found an incidence of osteoid osteoma to be less than 4% in the foot according to a review of series of 860 cases of osteoid osteoma. (8) Few cases have been reported according to literature. (8) In 1930 osteoid osteoma was first described by the German physicians Dr Bergstrand and it was described as benign

tumor by Dr Henry Jaffe in 1935. This benign bone tumor represents 10-12% of all benign bone tumors with male predominance.

Majority of the cases affected age group between the ages of 5 to 25 yrs. Commonly affecting the long bones of the lower extremities (>50%), other common areas are the posterior vertebral elements and upper extremities. (9) The incidence is 2-11% in the ankle and foot (6) with talus being most commonly affected bone in the foot. (6) First case of osteoid osteoma reported by

Jaffe et al (2) occurred in the middle toe of right foot in his first publication. Most characteristic clinical features of osteoid osteoma in the phalynx of toes are swelling and dull aching pain at night time and that is relieved by use of NSAIDS. Radiologically the typical osteoid osteoma lesion has distinctive lucent nidus usually <1-1.5cms surrounded by sclerotic bone reaction. Microscopically the nidus is composed of interlacing network of osteoblast lined trabeculae with intertrabecular stroma rich with vascular tissue and surrounded by reactive sclerotic bone. Surgical excision of the lesion has been the gold standard of the treatment of osteoid osteoma. (6)

Microscopic examination of osteoid osteoma shows mature bony trabeculae with thin osteoblastic rimming and adjoining foci of immature thin bony trabeculae with increased density of osteoclasts? Intervening stroma shows fibroblasts and many congested blood vessels. Occasional foci of osteoclast type giant cells are noted. Microscopic examination of osteomyelitis shows mature bony trabeculae with osteoblastic rimming. Intervening stroma shows congested blood vessels and marrow elements. Dead bone spicules are seen in many foci. Dense acute inflammatory cell collection and areas of necrosis is seen in some foci. Presence of dead bone spicules, acute inflammatory cell collections and areas of necrosis differentiates this entity from osteoid osteoma.

Microscopic examination of osteoblastoma shows mature bony trabeculae with plump osteoblastic rimming. Intervening stroma shows congested blood vessels. Occasionally osteoclast type giant cells are noted. Adjacent foci showing areas of haemorrhages congested blood vessels and mature bony trabeculae. Presence of plump osteoblastic rimming and less number of osteoclasts helps to differentiate osteoblastoma from osteoid osteoma.

Microscopic examination of Osteosarcoma shows mature woven bone with intervening stroma showing tumor cells which are round to oval with

hyperchromatic pleomorphic nuclei with moderate amount of cytoplasm. Some of these tumor cells are showing plasmacytoid and some are epithelioid. Many foci showing tumor giant cells are noted. Stroma showing eosinophilic lace like osteoid formation. Absence of tumor cells with lace like osteoid formation and necrosis can differentiate osteosarcoma from osteoid osteoma.

A combination of medical history, clinical suspicion, radiological examination and histological examination leads the clinician to the diagnosis. Surgical total resection of the lesion was the method of treatment. In our case it resulted in complete resolution of the patients' symptoms and signs with no recurrence noted in follow up.

## CONCLUSION

Osteoid osteoma is a benign tumor should be considered in the differential diagnosis when a patient presents with pain and swelling in the great toe and improvement of pain with use of NSAIDS. Histopathological examination is sufficient for the confirmatory diagnosis.

## REFERENCES

1. Bergstrand H (1930) Ubereineeigenartige ,wars cheinlichbishernicht be schrie beneos teoblaastische Krakheit in den langen Knochen in der Hand und des Fusses. Acta Radiol 11:596-613.
2. Henry L Jaffe (1935) Osteoid osteoma. A bening osteoblastic tumor composed of osteoid and atypical bone. Arch Surg 31(5):709-728.
3. De Souza Diaz L, Frost HM. Osteoid osteoma –osteoblastoma. Cancer 1974; 33(4): 1075-81.
4. Braca F , Acciaro AL, Recchioni MD. Osteoid osteoma of the phalynx : enlargement of the toe—two case reports. Foot Ankle Int 1998;19 (6): 388-93.
5. Laurence N, Epleman M, Markowitz RI, Jaimes C, Jaramillo D, Chauvin NA. Osteoid osteoma: a pain in the night diagnosis. Pediatr Radiol 2012; 42 (12) : 1490-501.
6. Latifa Al Manaee, Amani Joudeh, Ahmed Mohamed Aly and Emad Al Absi . Osteoid

- osteoma of the Big Toe Mimicking Epidermal Inclusion Cyst, A Case Report And Review of The Literature. Ortho and Rheumatology open access journal; 5(4): 1-4.
7. Szendroi M, Kollo K, Antal I, Lakatos J, Szoke G. Intraarticular osteoid osteoma : clinical features, imaging results and comparison with extraarticular localization. J rheumatol 2004;31:957-64.
  8. Jackson RP, Reckling FW, Mantz FA. Osteoid osteoma and osteoblastoma . similar histological lesions with different natural histories. Clin Orthop Relat Res 1977;128: 303-13.
  9. Orthopedic knowledge Update: Musculoskeletal Tumors 3, Editor L Sybil Biermann, MD AAOS (chapter 11).

How to cite this article: Rao BSS, Shanthi V, Rao NM et.al. Osteoid osteoma of proximal phalanx of right great toe: a rare entity. International Journal of Research and Review. 2020; 7(5): 207-210.

\*\*\*\*\*