

## Massive Vascular Malformation in Head and Neck Region- A Rare Case Report with Review of Literature

Ramhari Sathawane<sup>1</sup>, Kshitija Bhakte<sup>2</sup>, Hemant Thakur<sup>3</sup>, Kanchan Patil<sup>4</sup>,  
Rakhi Chandak<sup>5</sup>, Ashish Lanjekar<sup>5</sup>, Lajri Bagde<sup>2</sup>

<sup>1</sup>Professor and HOD, <sup>2</sup>Post Graduate student, <sup>5</sup>Reader,  
Department of Oral Medicine and Radiology, Swargiya Dadasaheb Kalmegh Smruti Dental College and  
Hospital, Nagpur

<sup>3</sup>Consultant Radiologist, New Era Hospital, Nagpur

<sup>4</sup>Associate Professor, Department of Dentistry and Plastic surgery, Government Medical College and Hospital,  
Nagpur

Corresponding Author: Kshitija Bhakte

### ABSTRACT

Vascular Malformations are rare anomalies occurring in the Head and Neck region and rarest to be found intraorally. They are usually unnoticed in initial stages of life but may be progressive in later stages of life. Venous malformation is the most common type of vascular malformation affecting 1-4% of individuals worldwide. We present a very rare case of 37 year old adult male with massive venous malformation involving tongue, soft palate, retromolar region, nasopharynx, larynx and respiratory tract. Since the lesion is involving respiratory tract and larynx, there is every possibility of respiratory wall collapse and distress and loss of voice after sclerotherapy. Therefore it was decided to keep the patient is kept under regular observation/follow-up. This case is being reported because of its peculiar clinical presentation with involvement of vital organs.

**Key Words:** Massive Vascular Malformation, Venous Malformation, Sclerotherapy, Respiratory collapse.

### INTRODUCTION

Birthmarks are a heterogeneous group of congenital blood vessel disorders also known as vascular anomalies. They are most commonly seen in infants and may or may not fade away with the age. They are broadly classified into tumors and malformations based on clinical

presentation, histopathologic features and biological behavior<sup>1</sup>. They are mostly due to proliferation of capillaries.<sup>1</sup> These anomalies are being originally divided by Mulliken & Glowacki in 1928.<sup>2</sup> The most widely used classification nowadays is given by International society for study of vascular anomalies (ISSVA) in April 2014 for proper diagnosis and treatment.

The significant difference between the tumors and malformations is, tumors manifest in early age and are superficial, whereas malformation do occur in early age but appears in later stages of life and are deep seated. Amongst all the vascular malformation the head and neck region comprises of only 7%.<sup>3</sup>

### CASE REPORT

A 35 year old male reported to the Department of Oral Medicine and Radiology for replacement of missing teeth. On general examination patient's vital signs and systems were within normal limits. On extraoral examination face was bilaterally symmetrical with sunken cheeks and wrinkled appearance (Fig.1).

Diffuse swelling was present on right side of neck just below inferior border and angle of mandible upto 2cm above acromial end of clavicle & anteroposteriorly from midline of neck to Sternocleidomastoid muscle. Skin over the

swelling- bluish in colour with multiple red spots over the region.

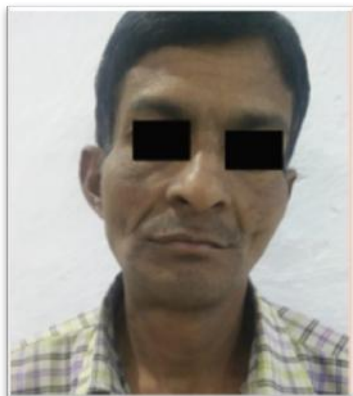

Fig 1: Extraoral examination of face- bilaterally symmetrical with sunken cheeks and wrinkled appearance.

All inspectory findings were confirmed on palpation. Swelling was soft in consistency, nontender and compressible. Local temperature was not raised. Turkey wattle sign<sup>4</sup> and Valsalva maneuver were positive (Fig.2).

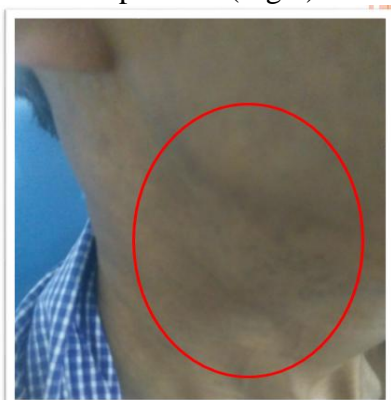

Fig 2: Turkey wattle sign<sup>4</sup> and valsalvamanuever were positive

There was no pulsation, bruit, thrill felt on auscultation. TMJ and muscles of mastication revealed no abnormality. No lymph node was palpable.

On intraoral examination teeth 18 and 38 were present.

Soft Tissue Examination revealed multiple swellings seen on ventral and dorsal surface of tongue, which were lobulated and diffused, and bluish-reddish in color, with fine granular surface (Fig.3).

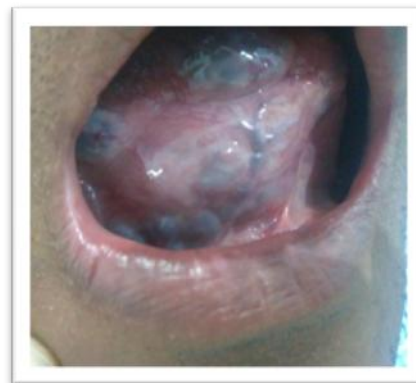

Fig 3: Multiple swellings seen on ventral and dorsal surface of tongue, which were lobulated and diffused, and bluish-reddish in color, with fine granular surface.

The swelling was further extending into the retromolar region, soft palate and the pharynx (Fig.4).

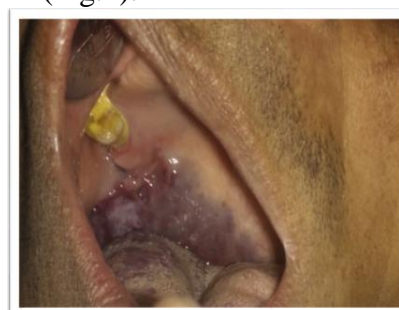


Fig 4: The swelling was further extending into the retromolar region, soft palate and the pharynx.

Swelling was soft in consistency, compressible and non-tender. Diascopy test was positive.

From the clinical features and chairside investigations, the provisional diagnosis of vascular malformation involving tongue, soft palate, retromolar region and nasopharynx extending into neck was made.

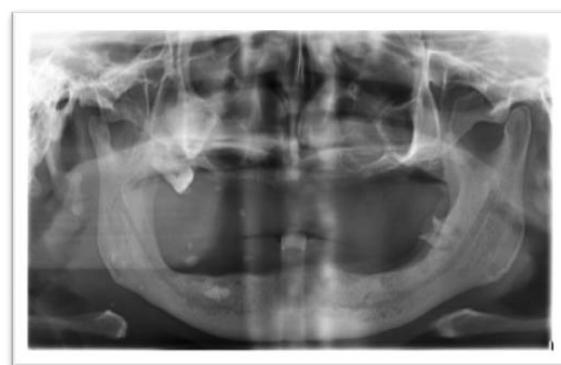


Fig.5: Orthopantomogram revealed multiple, smooth, circular tiny calcifications called as phleboliths.

Cone beam computed tomography (CBCT) was also done as additional investigation in which the constellations of phleboliths were seen on the three-dimensional (3D) image resemble a cluster of pearls of varying size, thus constituting the “shining pearls sign”<sup>5</sup> (Fig.6).

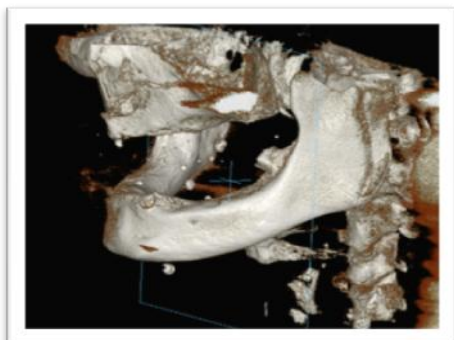


Fig 6: CBCT showing phleboliths with shining pearls sign.

As the lesion was very massive and deep seated, Magnetic Resonance Imaging (MRI) was advised to know its exact extent. The MRI showed large ill-defined infiltrating lobulated septate delayed enhancing altered signal intensity lesion appearing isointense on T1WI images and hyperintense on T2WI images & STIR was noted with its epicenter in the right half of tongue, involving upper and lower gingivobuccal sulcus, anteriorly involving muscles of tongue, superiorly extending into nasopharynx and posteriorly it was extending to retropharyngeal space, right parotid space, right parapharyngeal space and prevertebral space reaching upto T1 vertebra, also involving epiglottis, vocal cords & thyroid cartilage (Fig.7).

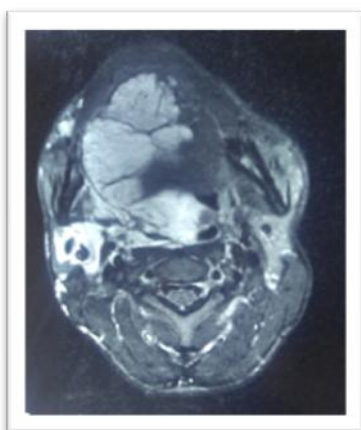


Fig 7: MRI showing extent of the lesion till T1 vertebra.

The final diagnosis of massive venous malformation of head and neck was made from clinical and radiographic features. Owing to the size and extension of the lesion the patient was referred to Interventional Radiologist for further management by staged sclerotherapy. But sclerotherapy could not be undertaken due to extensive involvement of respiratory tract and larynx as the sclerosing agents could lead to extensive respiratory wall collapse, respiratory distress and loss of voice. He was kept under observation and was advised to not to chew and swallow hard food stuffs and avoid trauma to the affected area.

Patient was also referred to department of Prosthodontics where flexidentures was fabricated for the patient and since then the patient is on regular follow up.

## DISCUSSION

Due to the common embryological origin of single endothelial cell lining, vascular malformation are grouped together, where developmental errors during embryogenesis include abnormal signaling process that control apoptosis, maturation and growth of cells and thus these errors lead to the persistence of vascular plexus cells with a certain degree of differentiation.<sup>6</sup> The vascular malformation are divided into two broader categories depending on their flow characteristics. Slow-flow malformations includes capillary malformation, venous malformation, lymphatic malformation and fast-flow includes arteriovenous malformation.<sup>7</sup> The history and clinical examination of the lesion allow the physician to make a sound diagnosis when co-related with other imaging features on Color Doppler or Spectral Doppler tracings or Magnetic Resonance Imaging (MRI). The imaging modalities assist in confining particular attributions of the lesion defining anatomic locations and proper resection or surgical intervention.<sup>8</sup>

Venous malformations (VMs), are the malformations which are present at

birth and appear in later stages of life. The overall incidence of vascular malformation is 1 in 10000.<sup>9</sup> VMs are also the most common type of vascular malformation affecting 1-4% of individuals. Clinically they appear as bluish, soft, compressible lesions typically found on face, limbs and trunk.<sup>10</sup> Venous malformations are composed of small veins and venules of different dimensions mostly lined by single endothelial epithelium layer. They mostly tend to grow as the age advances with puberty, hormonal factors or any other underlying infections.<sup>11</sup> They mostly show predisposition to thrombosis, later forming phleboliths which are peculiar features of this pathology and are very well seen on diagnostic radiographs. Intralesional calcifications are formed as a result of venous stasis and inflammation.

Modalities such as diagnostic Ultrasound and color Doppler are first line, after clinical examination, that show slow flow lesions with phleboliths.<sup>12</sup> But MRI is the most useful in defining extent of malformation. Angiography is also useful when identifying lesion to be deep or small VM, as in intralesional sinus pericranii of GIT as MRI/MRA are not as sensitive in identifying them.<sup>13</sup> The hematological investigations also play a vital role, as it is sometimes important to know about the coagulation profile of the patient as there is risk of localized intravascular coagulopathy.<sup>14</sup>

Massive venous malformations may rarely be associated with syndrome Blue Rubber Bleb nevus Syndrome(BRBNS) also known as Bean Syndrome,<sup>15</sup> in which small malformations occurs on upper arm and trunk and is generalized. The malformations are of typically bluish color, soft and easily compressible. Histologically cavernous space is lined by a single layer of endothelial cells separated by varying amounts of collagenous and fibrous tissues.<sup>16</sup> There is also involvement of GI System, where occasionally intestinal bleeding also occurs resulting in anaemia and also life threatening conditions such as

DIC. Cases of CNS involvement have also been noted, where focal seizures or other neurological symptoms are a result of compression of lesion. The cases of BRBNS are sporadic, also some familial cases of chromosome 9p that end on receptor tyrosine kinase believe to be involved in vascular malformation have also been noted.<sup>17</sup> There has been no association of syndrome in the present case. Review of literature revealed that so far only one such case of extensive involvement has been reported in literature by Y.T. Lakkashetty et al.<sup>18</sup>

Treatment options for VM depend on the size, extent and location. In patients where esthetic is prime concern the initiation therapy must be delivered. Interventional Radiology can deliver primary treatment such as staged sclerotherapy and embolization. Sclerotherapy with absolute ethanol is effective for treatment of large, extensive VMs but should be used with caution as large, extensive VMs can damage nerves causing skin necrosis and induce systemic toxicity. Sclerosants such as 3% sodium tetradecyl sulfate and bleomycin are most common.<sup>19</sup> Surgery is rarely a first line therapy but can be considered in following situations:

- 1) To ligate efferent veins to improve results with sclerotherapy,
- 2) Remove residual VM,
- 3) Lesion resistant to sclerosing agent and
- 4) Lesion amenable to complete excision.

The surgeon must consider about all the operative risks and then proceed.<sup>20</sup>

## CONCLUSION

Venous Malformations are a different entity of lesions as compared to other variants of Vascular Malformations occurring elsewhere in body. They need to be treated initially with a conservative approach and then proceed with surgical interventions. We report here a very rare case of massive vascular malformations involving oral cavity and neck.



## REFERENCES

1. Mulliken JB Vascular malformations of the head and neck. In: Mulliken JB, Burrows PE, Fishman SJ (eds) Vascular anomalies: Hemangiomas and malformations, 2nd edn. Oxford University Press, New York, 2013 pp 839–871.
2. Heink KD et al (2002) Venous malformations of skeletal muscle. *Plast Reconstr Surg*, 2002, 110(7):1625–1635
3. Mulliken JB et al. Vascular anomalies. *CurrProblSurg* 2000,37(8):517–584.
4. Saeed WR et al. The 'turkey wattle' sign revisited: diagnosing parotid vascular malformations in the adult. *Br J Plast Surg*. 1997 Jan,50(1):43-6.
5. Venkatraman Bhat et al, Shining Pearls Sign: A New Identity for Venous Malformations on Computed Tomographic Imaging, *Int J Angiol* 2016,25:e21–e24.
6. Cohen MM Jr. Vascular update: morphogenesis, tumors, malformations, and molecular dimensions. *Am J Med Genet A* 2006,140(19):2013–2038.
7. Lowe LH et al. Vascular malformations: classification and terminology the radiologist needs to know. *Semin Roentgenol* 2012,47(2):106–117
8. LucíaFlors et al MR Imaging of Soft-Tissue Vascular Malformations: Diagnosis, Classification, and Therapy Follow-up, *RadioGraphics* 2011, 31:1321–1340
9. Buckmiller LM et al. Diagnosis and management of hemangiomas and vascular malformations of the head and neck. *Oral Dis*. 2010,16:405–18.
10. Cox JA et al. Vascular malformations: A review. *SeminPlastSurg* 2014,28:58-63.
11. Lee BB et al. Diagnosis and treatment of venous malformations. Consensus document of the International Union of Phlebology (IUP): Updated 2013. *Int Angiol* 2015,34:97-149.
12. Wassef M et al. Vascular anomalies classification: Recommendations from the international society for the study of vascular anomalies. *Pediatrics* 2015,136:e203-14
13. Tomlinson FH et al. Angiographically occult vascular malformations: a correlative study of features on magnetic resonance imaging and histological examination. *Neurosurgery* 1994,34(5):792–799.
14. HochmanMet et al. Current knowledge and management of vascular anomalies, II: malformations. *ArchFacialPlastSurg* 2011, 13(6): 425–433
15. Bean WB. Blue rubber bleb nevi of the skin and gastrointestinal tract. In: *Vascular Spiders and Related Lesions of the Skin*. Springfield, IL: Charles C. Thomas, 1958,178–185
16. Kunishige M et al. Interferon alpha-2a therapy for disseminated intravascular coagulation in a patient with blue rubber bleb nevus syndrome. A case report. *Angiology* 1997,48(3):273–277
17. Waybright EA et al. Blue rubber bleb nevus syndrome with CNS involvement and thrombosis of a vein of Galen malformation. *Ann Neurol* 1978,3(5):464–467
18. Yogesh T Lakkasetty Multiple vascular malformations in head and neck - Rare case report. *J Oral MaxillofacPathol*. 2014 Jan-Apr, 18(1): 137–142.
19. LeeBBetal. Management of arteriovenous malformations: a multidisciplinary approach. *J VascSurg* 2004,39(3):590–600
20. VisserA et al. Surgical management of arteriovenous malformation. *J Plast Reconstr AesthetSurg* 2011, 64(3): 283–291

How to cite this article: Sathawane R, Bhakte K, Thakur H. Massive vascular malformation in head and neck region- a rare case report with review of literature. *International Journal of Research and Review*. 2020; 7(2): 268-272.

\*\*\*\*\*