

Stuck Mitral Valve Thrombosis Presenting as Embolic Stroke Following Thrombolysis- A Case Report

Uthaya Sankar M. K¹, Rangarajan D.V², Louis Ferdin Zeno. J³

¹Professor and Unit Chief, ^{2,3}Postgraduate residents,
Department of General Medicine, Sri Manakula Vinayagar Medical College and Hospital, Puducherry 605107,
India

Corresponding Author: Uthaya Sankar M. K

ABSTRACT

Prosthetic valve thrombosis is one of the major causes of primary valve failure, which can be life-threatening. Although surgery is the first-line treatment modality in symptomatic Prosthetic valve thrombosis, thrombolytic therapy has recently evolved as an effective substitute to surgery. Cerebral embolism can occur in 5-6% of left sided valve thrombus and this is a case of Prosthetic mitral valve thrombosis presenting as acute ischaemic stroke after Thrombolysis due to Thromboembolism.

Keywords: Prosthetic valve Thrombosis, Thrombo-embolism, Acute Ischaemic Stroke

INTRODUCTION

Prosthetic valve thrombosis (PVT) is a rare but serious complication of valve replacement, most often encountered with Mechanical prosthesis.^[2] PVT is an obstruction of a prosthesis by noninfective thrombotic material. The most common cause of PVT is inadequate anticoagulant therapy. Unfortunately, vitamin K antagonists are still the only approved oral anticoagulants in patients with heart valve prostheses. Even with the use of Vitamin K Antagonists, the risk of thromboembolism is 1%–2% per year, but the risk is considerably higher without or inadequate treatment with warfarin.^[3] Significant morbidity and mortality associated with this condition warrants rapid diagnostic tests. The different therapeutic modalities

available for Prosthetic Valve Thrombosis (Heparin treatment, fibrinolysis, surgery) will be largely influenced by the presence of valvular obstruction, by valve location (Left- or right-sided), and by clinical status.^[2]

CASE REPORT

This is a case of 23 years old female who is a K/C/O Mitral valve prolapse for which Mitral valve replacement (St. Jude's valve) done, 4 years ago, presented with chief complaints of difficulty in breathing for 3 days, Class III-IV NYHA, with orthopnea and history of cough with Expectoration. No history of fever, chest pain, limb swelling present. She was on irregular Oral anticoagulation medications. No other comorbidities. General examination was normal. Vitals - Pulse Rate- 110 bpm, BP- 80/50mmHg, RR- 32/min, SPO₂- 92% at Room Air. Cardiovascular system examination - S1, S2 heard and Valve click not heard in mitral area. Respiratory system examination revealed Fine end Inspiratory Crepitations in Bilateral Infra-Axillary and Infra-Scapular areas. Central nervous System revealed No Focal Neurological deficit. Abdomen examination – Soft, non-tender, No organomegaly.

Investigations showed PT INR value of 1.5. Chest X-ray revealed Cardiomegaly with ill defined homogenous opacities present in Bilateral lung fields(fig1-thin

black arrows) and prosthetic mitral valve noted (fig1-thick white arrow) along with Sternal sutures, suggestive of Pulmonary edema. ECG showed Sinus Tachycardia with no Acute ST-T changes. ECHO revealed Prosthetic valve thrombosis (fig2-thick white arrow), Valve gradient of 47mm/hg, Severe Pulmonary Hypertension and RVSP 44mmHg with Ejection Fraction of 60%. Thus, diagnosis was made as Mechanical Mitral valve Thrombosis with Acute Pulmonary Edema.

Patient initially was treated with Inj. Streptokinase 2.5 Lakhs IU over 1 hour followed by 1 Lakh IU/hour over 24 hours and Heparin. After 3 hours, she developed aphasia, weakness of right upper and lower limb (Power- 1/5) with both Plantar Extensor. Heparin was stopped. Streptokinase was stopped and Emergency NCCT Brain was done and revealed Acute ischaemic stroke Lt side > Rt side MCA territory without haemorrhagic transformation (fig3-thick white arrow). So thrombolysis was continued in view of ischemic stroke. After which patient's INR improved to 2.8. Patient showed gradual improvement in the next 5 days with power of the limbs improving from 1 to 4/5.

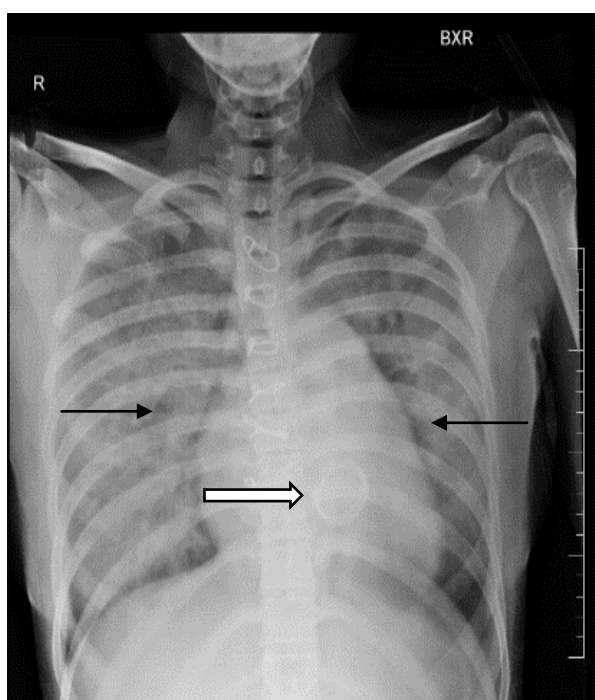


Figure1: Chest X-ray PA view

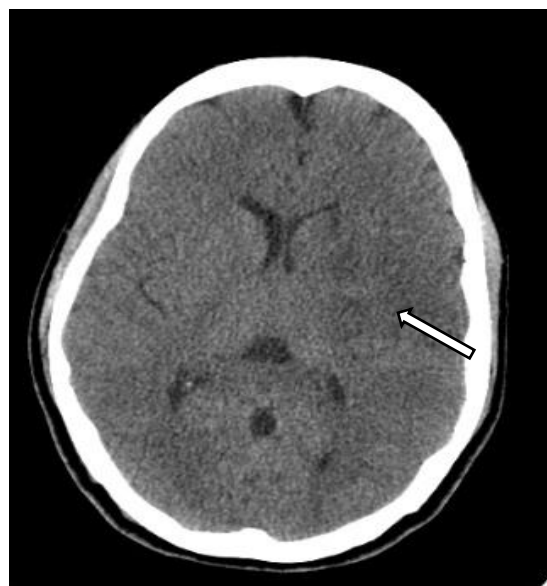

Figure 2: Plain CT Brain Axial view

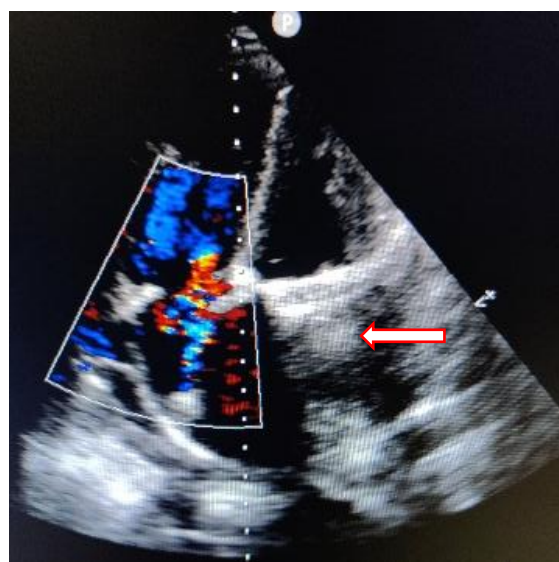

Figure 3: 2D Echo Heart

DISCUSSION

Pulmonary valve thrombosis is more common in Mitral and Tricuspid valves than aortic valve prosthesis. Cine fluoroscopy (for mechanical valves) and transthoracic and transoesophageal echocardiography represent the main diagnostic procedures.^[2] Two-dimensional (2-D) transesophageal echocardiography (TEE; 2-D TEE) is limited in evaluating structural abnormalities of prosthetic valves due to attenuation and acoustic shadowing; therefore, further TEE examination is usually required.^[4]

As for as treatment options concerned, Low-dose slow infusion of t-PA

repeated as needed without a bolus provides effective and safe thrombolysis in patients with prosthetic valve thrombosis.^[1] In this case, Ischemic stroke developed due to thrombolysis is a major complication. The recommended t-PA dose for acute ischemic stroke regarding to current guidelines is 0.9 mg/kg (maximum dose 90 mg) over 60 minutes with 10% of the dose given as a bolus over 1 minute with the caveat that IV t-PA has been associated with lower recanalization rates. Acute ischemic stroke may be managed with intravenous thrombolysis, combination of thrombolytics with other anti-aggregants like glycoprotein IIb/ IIIa inhibitors, intra-arterial thrombolysis and other catheter based approaches such as mechanical thrombectomy.^[2]

REFERENCES

1. Özkan M, Gündüz S, Biteker M, Astarcioglu MA, Çevik C, Kaynak et al. Comparison of different TEE-guided thrombolytic regimens for prosthetic valve thrombolysis: the TROIA trial. *JACC Cardiovasc Imaging*. 2013 Feb;6(2):206-16.
2. Özkan M et al. Management of acute ischemic stroke occurred during thrombolytic treatment of a patient with prosthetic mitral valve thrombosis: Continuing thrombolysis on top of thrombolysis. *Anatol J Cardiol* 12, 689–690 (2012).
3. Roudaut R, Serri K, Lafitte S. Thrombosis of prosthetic heart valves: diagnosis and therapeutic considerations *Heart* 2007; 93: 137-142.
4. Gürsoy MO, Kalçık M, Yesin M, Karakoyun S, Bayam E, Gündüz S, Özkan M. A global perspective on mechanical prosthetic heart valve thrombosis: Diagnostic and therapeutic challenges. *Anatol J Cardiol*. 2016 Dec;16(12):980-989.

How to cite this article: Uthaya Sankar M. K, Rangarajan D.V, Louis Ferdin Zeno.J. Stuck mitral valve thrombosis presenting as embolic stroke following thrombolysis- a case report. *International Journal of Research and Review*. 2020; 7(12): 271-273.
