

# A Prospective Study of Adnexal Masses with Its Evaluation by Risk of Malignancy Index among Patients Attending Tertiary Care Hospital

Shireen Prince

Department of Pharmacy Practice, Malla Reddy Pharmacy College, Dhullapally, Secunderabad -500100  
Telangana, India.

## ABSTRACT

**Objective:** The aim of this study was to evaluate clinical profile of patients with adnexal masses in tertiary care hospital.

**Method:** A hospital based observational, prospective study was conducted on patients with adnexal masses for 6 months in gynaecology department. Based on diagnosis, 102 patients were enrolled into the study and interviewed to record their age, symptoms, risk factors, diagnosis with laboratory parameters and treatment. Risk of malignancy index (RMI) was calculated and SAS was used for analysis.

**Results and Discussion:** Most of the patients (30%) admitted were in the age group of 41-50 years. Abdominal pain was the most common symptom. The most common risk factor was hypothyroidism (67.5%) among patient profiles recorded. Uterine fibroid and ovarian cyst were the most common adnexal masses. On histopathological examination, the most common finding was benign leiomyoma (34.31%). Hysterectomy and salpingectomy were the most frequent type of surgery performed in our study. 7 out of 102 patients reported complications like ovarian torsion (57.14%), infertility (28.57%) and rupture (14.28%). Based on RMI scoring patients were distributed into 3 groups out of which 5 cases reported RMI above 200 and had positive correlation with the histopathological reports.

**Conclusion:** An organized approach of thorough history with evaluation of symptoms, risk factors, detailed clinical examination and correct interpretation of diagnostic modalities, RMI scoring to alert risk of malignancy is required for analysis and management of adnexal masses.

**Keywords:** Adnexal mass, Malignancy, Postmenopausal, RMI.

## INTRODUCTION

Uterine adnexa consist of ovaries, fallopian tube and the uterine ligament. The prevalence of adnexal masses is 0.17% to 5.9% in asymptomatic and 7.1% to 12% in symptomatic patients. [1] The definition of an abnormal structure on radiological imaging is also quite variable.

These are the 3 main clinical routes by which an adnexal mass may be detected:

1. Women with symptoms may have an adnexal mass detected as part of their evaluation for those symptoms, either by physical examination or radiological imaging.
2. The mass may be detected as part of a routine health maintenance examination.
3. It is possible that an asymptomatic mass could be detected during imaging done for another indication. [2]

Most frequently, adnexal masses refer to the ovarian masses or cysts; however, paratubal cysts, hydrosalpinx, and other non ovarian masses are also included. [3] Proper oncological treatment of patients with adnexal masses depends on appropriate preoperative discrimination between benign and malignant ovarian tumors. [4] Malignant ovarian tumors are associated with highest mortality rate of all gynaecological cancers. [5] Sixty per cent of women are diagnosed at an advanced stage, which has a 5-year survival as low as 10%. On the other hand early diagnosis provides

the 5-year survival of up to 90%.<sup>[6]</sup> However, it may be difficult to preoperatively determine the nature of adnexal tumours especially by a single diagnostic tool. There are suggestions that appropriate malignancy risk estimation could be achieved by RMI index scoring.

Asymptomatic, small, well-characterized adnexal masses are observed with regular pelvic examinations and radiologic evaluations. A surgical approach should be used if growth occurs in these masses and if the patient becomes symptomatic, or if the cyst develops more concerning features, such as solid components. The suspicion for a malignancy is increased in prepubescent and postmenopausal women.

Observational studies in women taking higher-dose, “early-generation” oral contraceptive pills suggested a lower incidence of functional and benign epithelial ovarian cysts. In postmenopausal patients, cyst aspiration is not advised. In benign cysts, cyst wall removal is necessary to prevent recurrence and aspiration has little therapeutic benefit.<sup>[7]</sup>

Cytology doesn't have 100% sensitivity for detection of cancer. Spillage of cyst fluid may induce peritoneal seeding of malignancy. It is known that cyst rupture decreases overall survival in stage 1 ovarian cancer patients when compared to intact tumors. Additionally, there are case reports of recurrence of malignancy along the aspiration needle tract.<sup>[8]</sup>

When an epithelial ovarian malignancy is encountered, a complete staging protocol must be performed. This commonly includes complete exploration of the abdomen, hysterectomy, bilateral salpingo-oophorectomy, omentectomy, pelvic and para-aortic lymph node dissections, biopsies of the undersurface of the right and left diaphragms and biopsies of the colic gutters followed by a maximal resection of the intra-abdominal tumor.<sup>[9]</sup> In select cases involving women with limited, early stage, low-grade ovarian cancers, a

fertility sparing procedure may be considered.<sup>[10]</sup>

Among women undergoing minimally invasive resection of adnexal masses, a transvaginal approach for specimen removal is associated with less postoperative pain than a transumbilical approach.<sup>[11]</sup> If a mass has observed features for a malignancy, care should be taken to remove the mass intact. Intraoperative tumor rupture is significantly more common during minimally invasive removal of adnexal masses as compared to an open approach.<sup>[12]</sup>

### Risk of Malignancy Index

The discrimination between benign and malignant adnexal masses is central to decisions regarding clinical management and surgical planning in such patients. Risk of malignancy index (RMI) is a reliable tool in differentiating benign from malignant adnexal mass.<sup>[13]</sup> Risk of malignancy index (RMI) is a combined parameter which is simple, practical and highly sensitive, and more specific.<sup>[14]</sup> RMI is calculated with a simplified regression equation obtained from the product of Menopausal status score (M), Ultrasonography score (U), and absolute value of serum CA-125 as in Figure 1. The most common threshold for probability of malignancy is greater than 200. Jacobs et al<sup>[15]</sup> developed the RMI in 1990s known as RMI 1. Later version of RMI in 1996 by Tingulstad et al<sup>[16]</sup> is termed as RMI 2 and modification of same in 1999 is known as RMI 3. Yamamoto et al<sup>[17]</sup> added tumor size as parameter to RMI and termed it RMI 4.

#### RMI = U x M x CA 125

Ultrasound characteristics:

- Bilateral lesions
- Evidence of metastases
- Evidence of solid areas
- Multilocular cyst
- Presence of ascites

If none of these characteristics are found, U=0

If one, U=1

If two or more, U=3

Menopausal Status

- If premenopausal, M=1
- If Postmenopausal, M=3

Serum CA 125 level (U per ml)

Figure 1 : Risk of Malignancy Index

## MATERIALS AND METHODS

A prospective observational study was conducted in tertiary care hospital for 6 months in gynaecology department. We obtained informed, written voluntary consent from all patients before enrolment. 102 patients who met the study criteria were enrolled into the study.

### Inclusion criteria:

- Female patients who are diagnosed with gynaecological adnexal mass.
- Patients with or without surgical intervention.
- Patients above 10 years of age.
- Patients who can co-operate for study.

### Exclusion Criteria:

- Patients with uncontrolled infections.
- Patients who are unable to cooperate.
- Pregnant and lactating women.
- Immuno-compromised patients.

The following information was collected: patient demographics, presenting complaints, past medical history, past medication history, family history, along with its risk factors, complications, treatment choice and associated co-morbidities. Laboratory reports such as complete blood picture, PAP smear, CA 125 test, thyroid profile and ultrasound (transvaginal) are also assessed. Using the reports of ultrasound, CA 125 and patient's menopausal status, Risk of Malignancy Index (RMI) was calculated. The data collected manually was reviewed and entered into Microsoft Excel database.

Risk of malignancy index (RMI 1 Jacobs et al <sup>[15]</sup>) was calculated using the formula:  $RMI = U \times M \times CA-125$ . Ultrasound score (U) was calculated based on five features – one point each for multilocular tumor, bilateral tumor, presence of solid parts in the tumor, presence of metastasis, and ascites; U = “1” if none or one feature is present, U = “2” if two or more than two features are present. Menopausal status (M) was marked “1” for premenopausal and “3” for postmenopausal

women. Patients with amenorrhea for more than a year or who had hysterectomy and age older than 50 years were considered as postmenopausal women. Value of CA-125 was calculated directly into the equation. 15 patient profiles fulfilled the criteria for RMI calculation. Based on RMI, the patients were stratified into three groups (RMI <25 = low risk; RMI 25–200 = intermediate risk; RMI >200 = high risk).

## RESULTS

In our study 102 patients were enrolled as per our study criteria. The roles of several factors were studied were assessed in the study to help clinicians in decision making.

Most of the patients (30%) admitted were in the age group of 41-50 years as illustrated in Figure 2. Among 102 patients, abdominal pain was the most common symptom (32.87%) as shown in Figure 3. The most common risk factor observed was hypothyroidism (67.5%) followed by obesity (10%), infertility (7.5%), infection (7.5%), and history of adnexal mass (7.5%) among patient profiles recorded. Uterine fibroid and cyst were the most common adnexal masses. Their distribution according to age is depicted in Table 1. On histopathological examination, the most common finding was benign leiomyoma (34.31%), followed by serous cyst adenoma of ovary (9.8%). 4 cases of papillary cyst adenocarcinoma and 1 rare case of leiomyosarcoma were confirmed to be malignant (Table 2). 48.03 % of the patients were operated for adnexal mass while 50% of patients were treated with drugs and 2% with both drugs and surgery. Hysterectomy and Salpingectomy were the most frequent type of surgery performed in our study as shown in Table 3. 7 out of 102 patients reported complications like ovarian torsion (57.14%), infertility (28.57%) and rupture (14.28%). Out of 102 patients 5 patients reported RMI above 200 score (Table 4) which had positive correlation with the histopathological reports.

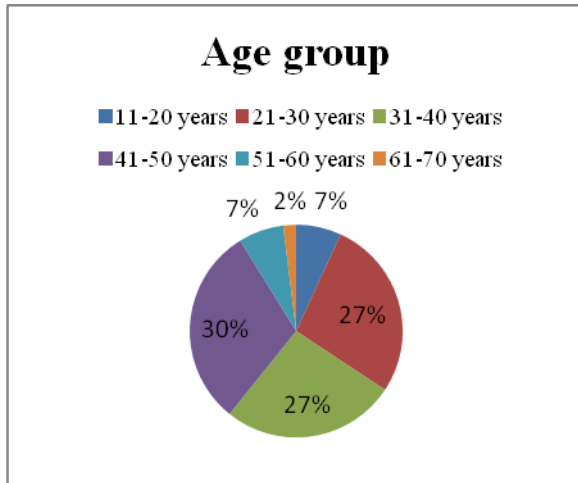


Figure 2: Distribution of patients according to age

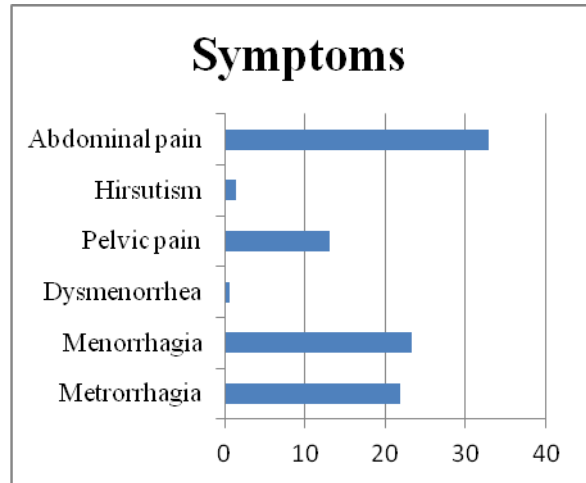


Figure 3 : Distribution of patients according to symptoms

Table 1: Distribution of patients according to adnexal mass and age

ADNEXAL MASS	AGE (YRS)						TOTAL
	<=20	21-30	31-40	41-50	51-60	61-70	
Uterine Fibroids (leiomyomas)	1(2.12)	3(6.38)	16(34.04)	25 (53.19)	2(4.25)	0	47
Ovarian cyst	5 (10.63)	19(40.42)	12(25.53)	5(10.63)	4(8.51)	2(4.25)	47
Polyp	0	0	2(50)	1(25)	1(25)	0	4
Poly cystic ovaries	1(11.11)	6(66.66)	2(22.2)	0	0	0	9

Table 2: Distribution of patients according to histopathological diagnosis of adnexal mass

Histopathological diagnosis	No. of patients	Percentage (%)
Serous cyst adenoma of ovary	10	9.80
Mucinous cyst adenoma of ovary	4	3.92
Hydrosalpinx	1	0.98
Papillary serous cyst adenocarcinoma	4	3.92
Leiomyoma (Benign)	35	34.31
Uterine Leiomyosarcoma	1	0.98
Ovarian torsion	4	3.98
Haemorrhagic cyst	1	0.98

Table 3: Distribution of patients according to type of surgery

Type of surgery	No. of patients	Percentage (%)
Salpingectomy	23	25.27
Polypectomy	3	3.29
Myomectomy	1	1.09
Hysterectomy	23	25.27
Cystectomy	17	18.68
Laparoscopy	9	9.89
Oophorectomy	15	16.48

Table 4: Distribution of patients in 3 groups according to rmi scoring

RMI <25	RMI 200-250	RMI >200
4.5	25	204
4.5	26	209.64
5.6	35	322
12.9	36	212.6
17.7	68	209

## DISCUSSION

In our study the prevalence of adnexal mass was seen more in the age group between 41-50yrs (30.39%) followed by the age group between 21-30 yrs

(27.45%). Satyabhama et al [18] reported that 41.26% of the patients were in the age group of 21-30 years.

Among 102 patients enrolled, 48 patients (32.87%) had abdominal pain. It reveals that strong relationship exists between adnexal mass and abdominal pain as reported in other studies by Suksham Sharma et al [19] and Balci O et al . [20]

67.5% of patients reported hypothyroidism in their medical history which shows its potential as risk factor but further studies are required to prove it.

Out of 102 cases, histopathological examination was done for 60 cases and majority were confirmed to be benign leiomyoma (34.31%) followed by serous cyst adenoma(9.8%) .The youngest patient was 11 years old with simple ovarian cyst and oldest was 70 years old with mucinous cyst adenoma. Mukherjee et al [21] had reported 20.5% as benign serous and 31.5% as mucinous benign tumour whereas Maheswari et al [22] reported 32.46% as benign serous and 14.53% as mucinous benign tumors.

Ovarian torsion was seen in 4 patients (57.14%) out of which 3 patients had a history of adnexal mass. Chih-Feng Yen M.D et al [23] in a similar study reported

around 14% of patients with ovarian torsion as complication.

Out of 102 patients enrolled, 10 patients were in intermediate and high risk groups. All patients with RMI >200 were considered highly suspicious for malignancy, and they were operated by the gynecologic-oncologist. All 5 malignant cases were patients of age above 50 years and were post menopausal with high RMI. Similar results were depicted in studies by Rojna Rai et al [24] and Badkur P et al. [2] The ROMA (Risk of ovarian malignancy algorithm) is a modification of RMI by Moore RG et al which includes CA 125, HE 4 and menopausal status, used to detect ovarian malignancies. [25]

## CONCLUSION

Evaluation of adnexal masses is always the need of the hour to eliminate risk of malignancy which can lead to further complications, morbidity and mortality. Our study was based on a methodological approach of collecting data, calculating RMI and alerting any risk of malignancy in clinical profiles of patients recorded.

The main limitations of the study were its hospital-based nature which predisposes to referral bias and absence of control group.

## ACKNOWLEDGMENTS

We would like to thank the doctors of gynaecology department for their immense support and our faculty members for advice regarding this paper.

## REFERENCES

1. D.K. Edmonds, Benign Diseases of the Vagina, Cervix and Ovary, in: Dewhurst's Textb. Obstet. Gynaecol., John Wiley & Sons, Ltd, Chichester, UK, 2018: pp. 811–822. <https://doi.org/10.1002/9781119211457.ch58>.
2. Clinico-pathological Correlation Of Adnexal Masses In Tertiary Care Centre, IJSR - International Journal of Scientific Research(IJSR), IJSR | World Wide Journals, (n.d.). <https://www.worldwidejournals.com/interna>

tional-journal-of-scientific-research-(IJSR)/article/clinicoandndash-pathological-correlation-of-adnexal-masses-in-tertiary-care-centre/Nzg2OQ==/?is=1&b1=385&k=97 (accessed July 3, 2020).

3. S. Campbell, Ovarian cancer: Role of ultrasound in preoperative diagnosis and population screening, *Ultrasound Obstet. Gynecol.* 40 (2012) 245–254. <https://doi.org/10.1002/uog.12281>.
4. Evaluation of Adnexal Masses: Correlation Between Clinical, Ultrasound and Histopathological Findings - PubMed, (n.d.). <https://pubmed.ncbi.nlm.nih.gov/22165752/> (accessed July 3, 2020).
5. L. Valentin, D. Jurkovic, B. Van Calster, A. Testa, C. Van Holsbeke, T. Bourne, I. Vergote, S. Van Huffel, D. Timmerman, Adding a single CA 125 measurement to ultrasound imaging performed by an experienced examiner does not improve preoperative discrimination between benign and malignant adnexal masses, *Ultrasound Obstet. Gynecol.* 34 (2009) 345–354. <https://doi.org/10.1002/uog.6415>.
6. J. Yazbek, S.K. Raju, J. Ben-Nagi, T.K. Holland, K. Hillaby, D. Jurkovic, Effect of quality of gynaecological ultrasonography on management of patients with suspected ovarian cancer: a randomised controlled trial, *Lancet Oncol.* 9 (2008) 124–131. [https://doi.org/10.1016/S1470-2045\(08\)70005-6](https://doi.org/10.1016/S1470-2045(08)70005-6).
7. Adnexal Tumors Treatment & Management: Medical Therapy, Surgical Therapy, Preoperative Details, (n.d.). <https://emedicine.medscape.com/article/258044-treatment> (accessed July 4, 2020).
8. R. Eskander, M. Berman, L. Keder, *Practice Bulletin No. 174, Obstet. Gynecol.* 128 (2016) e210–e226. <https://doi.org/10.1097/AOG.0000000000001768>.
9. Einhorn N, Ovarian cancer, *Acta Oncol.* 1996. 35 Suppl 7 86-92. (accessed July 3, 2020).
10. J.M. Schilder, A.M. Thompson, P.D. DePriest, F.R. Ueland, M.L. Cibull, R.J. Kryscio, S.C. Modesitt, K.H. Lu, J.P. Geisler, R. V. Higgins, P.M. Magtibay, D.E. Cohn, M.A. Powell, C. Chu, F.B. Stehman, J. Van Nagell, Outcome of reproductive age women with stage IA or IC invasive epithelial ovarian cancer treated with

- fertility-sparing therapy, *Gynecol. Oncol.* 87 (2002)1–7.  
<https://doi.org/10.1006/gyno.2002.6805>.
11. F. Ghezzi, A. Cromi, S. Uccella, G. Bogani, M. Serati, P. Bolis, Transumbilical versus transvaginal retrieval of surgical specimens at laparoscopy: A randomized trial, *Am. J. Obstet. Gynecol.* 207 (2012) 112.e1-112.e6. <https://doi.org/10.1016/j.ajog.2012.05.016>.
  12. A.L. Covens, J.E. Dodge, C. Lacchetti, L.M. Elit, T. Le, M. Devries-Aboud, M. Fung-Kee-Fung, Surgical management of a suspicious adnexal mass: A systematic review, *Gynecol. Oncol.* 126 (2012) 149–156. <https://doi.org/10.1016/j.ygyno.2012.04.018>.
  13. W.S. Biggs, S.T. Marks, *Diagnosis and Management of Adnexal Masses*, 2016.
  14. C.A. Hartman, C.R.T. Juliato, L.O. Sarian, M.C. Toledo, R.M. Jales, S.S. Morais, D.D. Pitta, E.F. Marussi, S. Derchain, Ultrasound criteria and CA 125 as predictive variables of ovarian cancer in women with adnexal tumors, *Ultrasound Obstet. Gynecol.* 40 (2012) 360–366. <https://doi.org/10.1002/uog.11201>.
  15. I. JACOBS, D. ORAM, J. FAIRBANKS, J. TURNER, C. FROST, J.G. GRUDZINSKAS, A risk of malignancy index incorporating CA 125, ultrasound and menopausal status for the accurate preoperative diagnosis of ovarian cancer, *BJOG An Int. J. Obstet. Gynaecol.* 97 (1990)922–929. <https://doi.org/10.1111/j.1471-0528.1990.tb02448.x>.
  16. The Risk-Of-Malignancy Index to Evaluate Potential Ovarian Cancers in Local Hospitals - PubMed, (n.d.). <https://pubmed.ncbi.nlm.nih.gov/10074998/> (accessed July 4, 2020).
  17. Y. Yamamoto, R. Yamada, H. Oguri, N. Maeda, T. Fukaya, Comparison of four malignancy risk indices in the preoperative evaluation of patients with pelvic masses, *Eur. J. Obstet. Gynecol. Reprod. Biol.* 144 (2009)163–167. <https://doi.org/10.1016/j.ejogrb.2009.02.048>.
  18. Clinicopathological analysis of adnexal masses in women, (n.d.). <http://jmscr.igmpublication.org/home/index.php/archive/155-volume-06-issue-10-october-2018/5876-clinicopathological-analysis-of-adnexal-masses-in-women> (accessed July 3, 2020).
  19. G. Sharma, Clinical profile of patients with pelvic adnexal masses, *Int J Reprod Contracept Obs. Gynecol.* 7 (2018) 4684–4687. <https://doi.org/10.18203/2320-1770.ijrcog20184530>.
  20. O. Balci, M.S. Icen, A.S. Mahmoud, M. Capar, M.C. Colakoglu, Management and outcomes of adnexal torsion: A 5-year experience, *Arch. Gynecol. Obstet.* 284 (2011) 643–646. <https://doi.org/10.1007/s00404-010-1702-z>.
  21. Ovarian Tumours - A Ten Years Study, (n.d.). <https://www.jogi.co.in/articles/view.php?id=NjA3Ng==> (accessed July 3, 2020).
  22. Surface Epithelial Tumours of the Ovary - PubMed, (n.d.). <https://pubmed.ncbi.nlm.nih.gov/8088904/> (accessed July 3, 2020).
  23. C.-F. Yen, S.-L. Lin, W. Murk, C.-J. Wang, C.-L. Lee, Y.-K. Soong, M. Phil, A. Arici, Risk analysis of torsion and malignancy for adnexal masses during pregnancy, (n.d.). <https://doi.org/10.1016/j.fertnstert.2008.02.014>.
  24. R. Rai, P. Bhutia, U. Tshomo, Clinicopathological profile of adnexal masses presenting to a tertiary-care hospital in Bhutan, *South Asian J. Cancer.* 8 (2019) 168. [https://doi.org/10.4103/sajc.sajc\\_303\\_18](https://doi.org/10.4103/sajc.sajc_303_18).
  25. R.G. Moore, D.S. McMeekin, A.K. Brown, P. DiSilvestro, M.C. Miller, W.J. Allard, W. Gajewski, R. Kurman, R.C. Bast, S.J. Skates, A novel multiple marker bioassay utilizing HE4 and CA125 for the prediction of ovarian cancer in patients with a pelvic mass, *Gynecol. Oncol.* 112 (2009) 40–46. <https://doi.org/10.1016/j.ygyno.2008.08.031>

How to cite this article: Prince S. A prospective study of adnexal masses with its evaluation by risk of malignancy index among patients attending tertiary care hospital. *International Journal of Research and Review.* 2020; 7(12): 194-199.

\*\*\*\*\*