

A Deviant Manifestation of Sarcoidosis: Bilateral Inguinal Lymphadenopathy

Uthaya Sankar M K¹, Swapna U S², Sivaram A³, Mythreini B S⁴

¹Professor, ^{2,3,4}Post graduate residents, Department of General Medicine, Sri Manakula Vinayagar Medical College and Hospital, Puducherry 605107.

Corresponding Author: Swapna U S

ABSTRACT

Background: Sarcoidosis is a systemic granulomatous disorder, characterized by involvement of multisystem, frequently involves pulmonary system. Sarcoidosis can have varied presentations. The clinical presentation of sarcoidosis ranges from asymptomatic to organ failure. It is unclear how often sarcoidosis is asymptomatic. Lymph node involvement is found rarely in isolation.

Case Report: A 63-year-old asymptomatic male presented with bilateral pelvic and inguinal lymphadenopathy. An ultrasonogram scan of the abdomen, and pelvis revealed bilateral deep pelvic and inguinal bulky lymphadenopathy. Excision biopsy revealed sarcoidosis. He responded to six months of oral steroid treatment.

Conclusion: This case illustrates the different presentation of sarcoidosis and the difficulty in diagnosing sarcoidosis in its initial stages. A high suspicion and excision biopsy is the key in diagnosing this condition.

Keywords: Sarcoidosis, Lymph nodes, Biopsy

INTRODUCTION

Sarcoidosis is a global disease of unknown etiology. It is an inflammatory disease characterized by the presence of non caseating granuloma with varied presentations thus leading to confusion whether asymptomatic individuals with suspected diagnosis of sarcoidosis should be investigated further. This disease is often multisystem and requires the presence of involvement in two or more organs for the specific diagnosis¹. The clinical presentation

of sarcoidosis varies from asymptomatic to complicated sarcoidosis. Respiratory involvement (> 90 %) is most common¹, but it is non specific in nature with non specific constitutional symptoms. Typical pulmonary manifestations are easily identified.

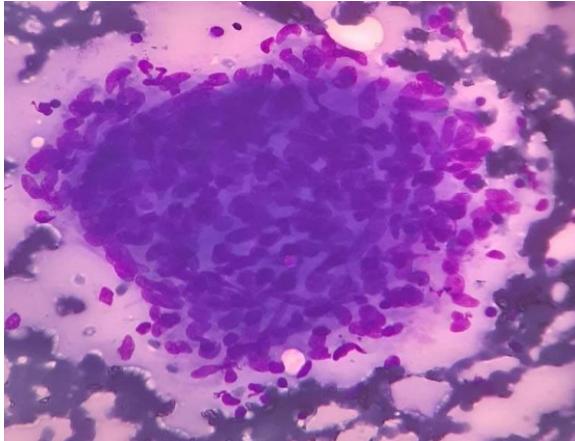
The typical manifestations of this disease include bilateral hilar lymphadenopathy and pulmonary reticular opacities². The clinical presentation of sarcoidosis depends as age, sex, and race, the duration of the disease and the sites of involvement. Frequency of common organ involvement is lung (90%), skin (24%), eye (12%), extra thoracic lymphnode (15%), liver (12%), Spleen (7%), neurological (5%), cardiac (2%) with Constitutional symptoms like fatigue, fever, night sweats and weight loss¹. Diagnosis of asymptomatic presentations in sarcoidosis remains a challenge as it can influence prognosis.

CASE REPORT

A 63 year old male presented with swelling over the bilateral inguinal region since 3 months, multiple in number and was non tender, non discharging. History of yellowish discolouration of urine for 7 days, 2 months back. For which patient took native treatment. History of generalized fatigability and weight loss present. Besides he was a smoker and quit smoking 3 years back.

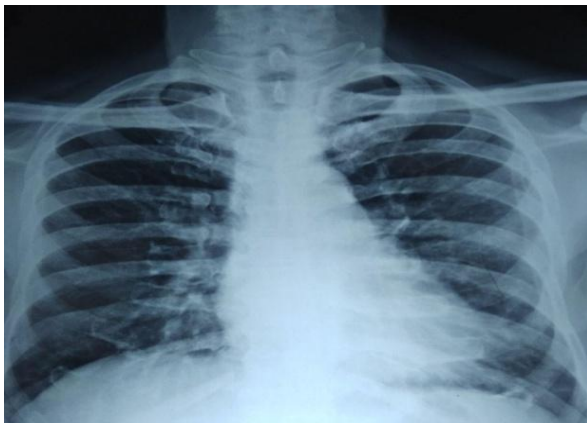
The vital signs were stable. In physical examination three non tender

lymphnodes were present over the right inguinal region, largest measuring 3*3 and two non tender lymphnodes were present over the left inguinal region, largest measuring 2.5*2. Hepatomegaly was present.

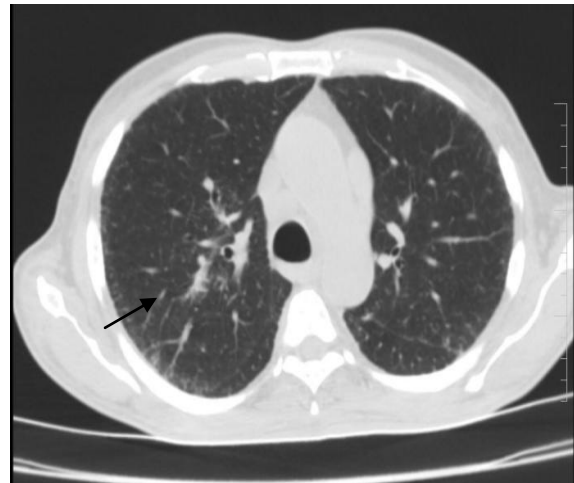


Lymph node biopsy – high power view of epithelioid granuloma with hemorrhagic background s/o granulomatous lymphadenitis [figure 1]

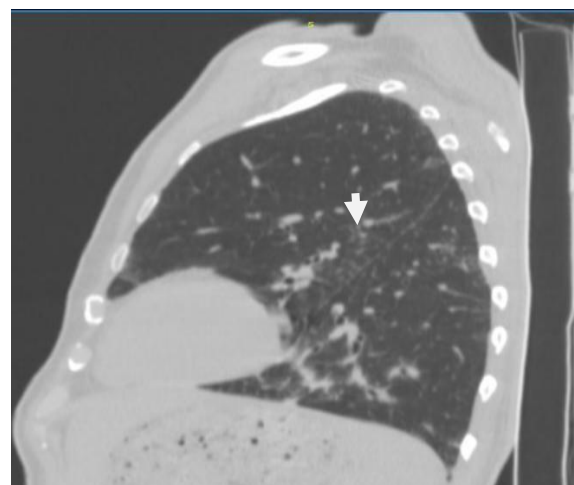
Test results were as follows: Hemoglobin: 11.4g/dL, Erythrocyte sedimentation rate: 40 mm/h, Alanine aminotransferase: 51 U/L, Aspartate aminotransferase: 78 U/L, Alkaline phosphatase: 391, GGT: 798 U/L, Total bilirubin: 1.2mg/dL, bilirubin (direct): 0.26mg/dL. Angiotensin-converting enzyme (ACE) level : 163 U/L, and coagulation tests were within the normal limit. In the initial stage suspected lymphomas and tuberculous etiology. Patient underwent Lymph node biopsy which shows: Granuloma with hemorrhagic background suggestive of granulomatous lymphadenitis indicating sarcoidosis (figure 1). Biopsy CBNAAT was negative.



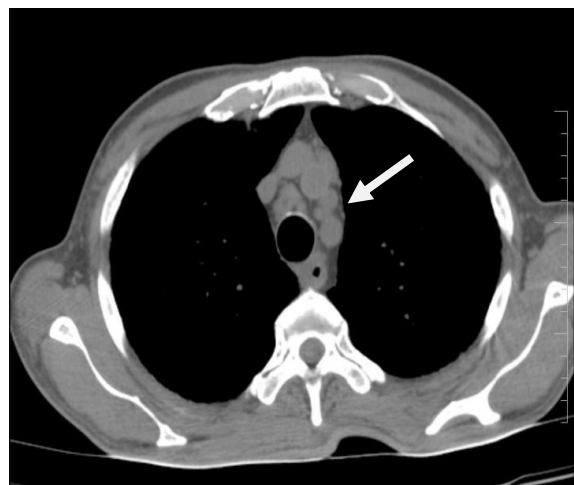Chest x-ray of patient [figure 2]



CT thorax -Sub pleural interlobular septal thickening over bilateral lung peripheries. [figure 3]



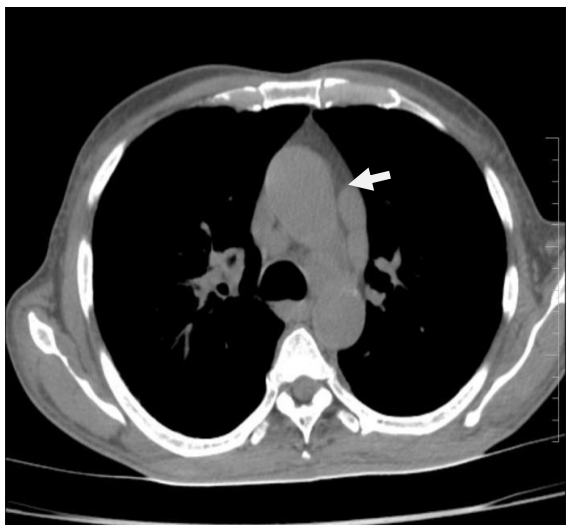
CT thorax -Multiple fissural nodules of size about 1 mm [figure 4]



CT thorax -Peri tracheal lymphnode[figure5]

Chest X-ray was normal (figure 2). Abdominal and pelvic ultrasound shows pelvic lymphnodes. For additional investigations CT thorax was taken showed multiple fissural nodules of size about 1mm,

para tracheal and perivascular lymphnodes. (figure3,4,5).



CT thorax -Perivascular lymph nodes [figure6]

DISCUSSION

The patient presented with bilateral inguinal swelling with weight loss. Findings from patients' examination revealed elevated levels of liver enzymes. After histological examination of lymphnode biopsy showed extra pulmonary sarcoidosis (showed epithelioid granuloma with hemorrhagic background suggestive of granulomatous lymphadenopathy) which is uncommon in the absence of pulmonary involvement. Retrospective investigation like CT thorax showed lymphadenopathy. ACE level increased suggestive of sarcoidosis. ACE normally increased by 20-30% in sarcoidosis patients^{3,4}.

Isolated peripheral lymphadenopathy is the uncommon presentation, particularly involving the cervical, axillary, epitrochlear, and inguinal nodes. Important differential diagnosis include Crohn's disease, lymphoma, and vasculitis, retroviral infection should be excluded. In our case, inguinal lymph node biopsy. There is no laboratory test that will diagnose sarcoidosis for certain. Diagnosis of sarcoidosis requires both compatible clinical and

pathologic findings such as of non-caseating epithelioid-cell granulomas.. Early diagnosis is the key to prevent the potentially damaging effects of sarcoidosis. Many people with sarcoidosis may not require any treatment, and self-resolution of sarcoidosis might occur after several years without causing serious complications. The appropriate therapy for sarcoidosis is based on symptoms and presence of organ failure. <10% patient requires no systemic therapy, in the other cases, treatment with corticosteroids is needed.

CONCLUSION

For asymptomatic inguinal lymphadenopathy one should consider the differential diagnosis of sarcoidosis

REFERENCES

1. Kasper DL, Hauser SL, Jameson JL, Fauci AS, Longo DL, Loscalzo J, Harrison's principle of internal medicine .20th ed. New York. The McGraw Hill Companies; 2015. p2600-2601
2. Criado E, Sanchez M , Ramirez J ,Arguis P ,de Caralt TM ,Perea RJ,et al. Pulmonary sarcoidosis: typical and atypical manifestations at high resolution CT with pathologic correlation. Radiographics 2010; 30(6):1567-1586
3. Keici B, Toros AB, Bayraktar L, Dervisoglu A. Sarcoidosis Incidentally diagnosed: a case report. Case rep Pulmonol 2014; 2014:702868
4. Belhomme N, Jouneau S, Bouzille G, Decaux O, Lederlin M, Guillot S, et al. Role of serum immunoglobulins for predicting sarcoidosis outcome: A cohort study. PLoS One 2018; 13(4):e0193122

How to cite this article: Uthaya Sankar MK, Swapna US, Sivaram A et.al. A deviant manifestation of sarcoidosis: bilateral inguinal lymphadenopathy. International Journal of Research and Review. 2020; 7(11): 605-607.
