

# Prevalence of Origination and Course of Anomalies of Right Coronary Artery in Indian Patients

Sudheer Venkata Bolinera, Srinivas Soma, Sanivarapu Srinivasa Reddy, Vijaya Pamidimukkala, Michael Naronha, Deepti Gali, Vikas Somnath Khamkar, Muralibaburao Rachaputi, Anurag Polavarapu, Naren Polavarapu, Sirichandana Gangasani, Sravanthi Byrapaneni, Meghana Chilukuri, Raghava Sarma Polavarapu

Lalitha Super Specialities Hospital, Guntur, Andhra Pradesh, India

Corresponding Author: Raghava Sarma Polavarapu

## ABSTRACT

**Background:** The right coronary artery (RCA) arises from the left sinus in an anomalous manner is an infrequent condition. Even though, many reports have centered on coronary artery anomalies, pattern of the anomalous origin of the right coronary artery (AORCA) has not well established. As far as literature is concerned, this is the first study that shed a light on the prevalence of origination and course of anomalies of RCA in the Indian population.

**Materials and methods:** This retrospective, observational study was conducted in tertiary healthcare center of India during the period of June 2018 to June 2020. A total of 8021 patients with suspicious or presumed development of coronary artery disease were enrolled in the study. Data regarding baseline demographics, past medical history, and origin of the anomalous RCA were collected from medical records.

**Results:** AORCA was more common in males (68%) than females (32%). The events of AORCA were present in 3.8% of total cases. Diabetes mellitus (43%) was the most common risk factor associated with the progression of anomalies of RCA, followed by hypertension (38%) and smoking (18%). RCA anomalies with very high origin were present in 1.15% of total cases, followed by low origin in 1.03%, and posterior origin in 0.93%.

**Conclusion:** The prevalence of AORCA among the Indian population has been higher than that reported in other parts of the world. Patients with the anomalies of RCA from the left sinus suffer from syncope, cardiac arrhythmias, and

myocardial ischemia and infarction. In terms of origin and clinical significance, proper understanding in regards to the anomalies of RCA is crucial for making the correct diagnosis, and further planning for treatment.

**Key words:** Anomalous, coronary vessel anomalies, prevalence, right coronary artery

## INTRODUCTION

Coronary artery anomalies are a diverse group of congenital disorders with multiple clinical presentations and pathophysiological mechanisms. Despite being rare, coronary artery anomalies are a major cause of sudden cardiac deaths globally.<sup>[1]</sup> The incidence of these anomalies have been varied according to geographical regions<sup>[2]</sup>; its reported prevalence had been 95% in Indian population<sup>[3]</sup>. Angeliet al.<sup>[4]</sup> has broadly classified coronary artery anomalies into four groups: 1) anomalies of origination and course, 2) anomalies of intrinsic coronary arterial anatomy, 3) anomalies of coronary termination or 4) anomalous collateral vessels. With regards to anomalies of origination and course, following origins are involved: a) absent left main trunk, b) anomalous location of coronary ostium within aortic root or near proper aortic sinus of Valsalva: high, low, commissural, c) anomalous location of coronary ostium outside normal "coronary" aortic sinuses, d) anomalous origination of

the coronary ostium from opposite, facing "coronary" sinus; its variants include anomalous origin of right coronary artery (RCA) from the left anterior sinus, anomalous origin of the left anterior descending coronary artery from the right anterior sinus, anomalous origin of the circumflex artery from the right anterior sinus, and anomalous origin of the left coronary artery from the right anterior sinus, or e) single coronary artery. Unlike other origins of anomaly, the anomalous origin of right coronary artery (AORCA) is a rare congenital disorder<sup>[5]</sup>, and it was firstly introduced by White and Edwards in 1948<sup>[6]</sup>. This anomaly of RCA develops either from left coronary sinus or from the aortic wall above the coronary sinus.<sup>[7]</sup> In literature, the estimated prevalence of AORCA has been just under 1%.<sup>[8]</sup> Generally, many of these anomalies are clinically benign, however few anomalies are linked to serious morbidity.<sup>[9]</sup> Like the diagnosis of any other coronary anomalies, conventional coronary angiography is the gold standard for the detection of AORCA as well, and it is readily available. Up to now, far too little attention has been paid to the prevalence of origination and course of anomalies of RCA, and little published data is available mainly in case report form; no comprehensive research on this topic has been reported from India as well as other parts of world. This paper is a preliminary attempt to retrospectively evaluate the prevalence of origination and course of anomalies of RCA among Indian patients, who underwent diagnostic coronary angiography for the assessment of coronary artery anomalies.

## MATERIALS AND METHODS

This retrospective, observational study comprises 8021 patients, who were referred to the tertiary health care center of India between June 2018 and June 2020. Patients with suspicious (atypical chest pain, angina like symptoms or several risk factors for cardiovascular disease) or presumed development of coronary artery

disease was a primary inclusion criteria for the study. All patients underwent coronary angiography as per a standard procedure. For all included patients, a retrospective chart review was done to gain data regarding demographics details, past medical history, and origin and course of the anomalous RCA. Patients with any other origin apart from RCA were completely excluded from the study. Patients were managed with percutaneous coronary procedures performed via either transfemoral or transradial approach. The ethics committee of the institute approved this study. The purpose of study was explained to the patients, and their written informed consent was obtained according to the Declaration of Helsinki. Continuous data are expressed as mean and standard deviation, and categorical data are expressed as frequency.

## RESULTS

In total, 8021 patients were included in the study in order to determine the events of anomalies of RCA. Out of 8021 patients, the incidence of AORCA was observed in 3.8% of cases. The majority of patients were male (68%) in our study population (Figure 1). The risk factors associated with cardiovascular diseases that may further develop anomalies of RCA are compiled in Table 1. Diabetes mellitus (43%) was the most common risk factor associated with the progression of anomalies of RCA, followed by hypertension (38%) and smoking (18%). With regards to coronary angiographic findings, anomalies of RCA with very high origin were present in 1.15% of total cases, followed by low origin in 1.03%, and posterior origin in 0.93%. Anomalies of RCA with non-coronary cusp was less frequent in our study population, and this figure was 0.06% (Figure 2).

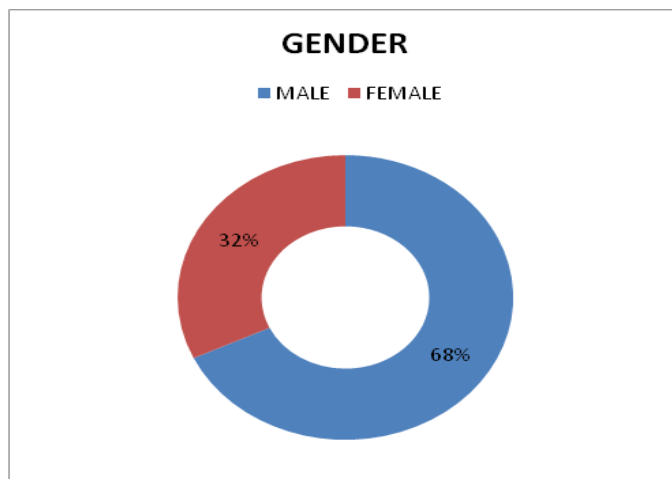
Table 1: Risk factors associated with the development of anomalies of RCA (n=8021)

Risk Factors	%
Hypertension	38
Diabetes mellitus	43
Smoking	18

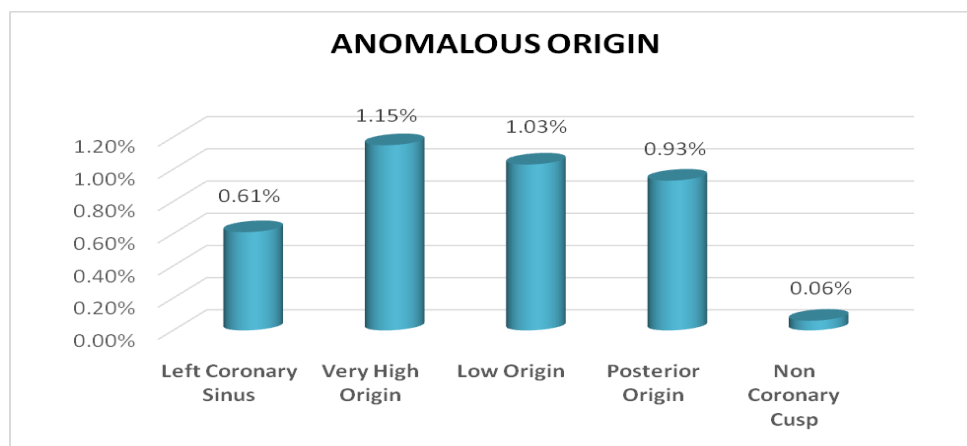
**Table 2: Prevalence of anomalies of RCA in earlier reported studies**

Author, publication year	Prevalence (%)	AORCA	Imaging modality	Country
Kakuet al. <sup>[10]</sup> , 1996	78.6 (44 of 56 with anomalous origin of coronary artery )	AORCA from LSV	CAG	Japan
Garg et al. <sup>[3]</sup> , 2000	0.46 (19 of 4,100)	AORCA from LSV/NAS	CAG	India
Fujimoto et al. <sup>[11]</sup> , 2011	0.46 (27 of 5,869)	AORCA from LSV	64MDCT	Japan
Erolet al. <sup>[12]</sup> , 2011	0.43 (9 of 2,096 )	AORCA from LSV	64MDCT	Turkey
Xu et al. <sup>[13]</sup> , 2012	0.42 (51 of 12,145)	AORCA from LSV	DSCT-CA	China

‡ LSV, Left sinus of valsalva; NAS, Non-facing aortic sinus; CAG, Coronary angiography; CTA, 64-Multi detector computed tomography angiography; DSCT-CA, Dual-source multi slice computed coronary angiography; AORCA, anomalous origin of right coronary artery



**Figure 1: Gender-wise distribution of subjects**



**Figure 2: Anomalous origin of right coronary arteries in our study subjects (n=8021)**

## DISCUSSION

The AORCA is an infrequent condition, and can be asymptomatic or may present with angina pectoris, myocardial infarction or sudden death. The mechanism of myocardial ischemia is mainly dynamic and not atherosclerotic plaques. The potential etiologies of obstruction to the blood flow are: ostial obstruction due to slit like coronary orifice, compression of RCA between aorta and pulmonary artery, stretching of the RCA with aortic/pulmonary artery distension.<sup>[9]</sup>

As mentioned earlier, ethnicity dominantly influences the prevalence of origination and course of anomalies of RCA. Table 2 summarizes the prevalence of anomalies of RCA reported in previous studies. Our researchers have arrived at the conclusion that the anomalies of RCA were significantly higher among Indian population (3.8%) than other world population. These inconsistencies of prevalence might be due to referral bias and undefined diagnostic criteria, which both are

primary requirements to define the actual prevalence of the entire population.

The current study does not support previous research that claimed that anomalies of RCA originated from the left sinus of Valsalva were also the most common coronary anomaly. In fact, contrary to what was previously thought, we found that RCA anomalies originated from very high origin were the most frequent followed by low origin, and posterior origin.<sup>[3,10-13]</sup> A high origin (or high take-off) for coronary arteries has been delineated as having ostia arises between 5 and 10 mm above the sinotubular junction. It is a very rare condition, represents 0.1% of the RCA abnormalities. It has been reported that the height of the origin of the vessel is a most vital parameter as a high ostium associated with reduced coronary perfusion.<sup>[14]</sup> However, high take-off positions without any haemodynamic significance are well tolerated and asymptomatic in some cases. Occasionally, orifices are engaged with these positions, and may further contribute to unexpected angiographic consequences. Note that high take-off can excellently view on angiogram or volume-rendered reformatted images.<sup>[15]</sup> Importantly, all cardiologists should be aware of these anomalies as during cardiac bypass surgery when the aorta is cross-clamped, high cannulation is required to prevent accidental cross-clamping or transection of the RCA. Generally, the coronary ostia is located in the lowest part of the aortic sinus implied as “low region” or “low take-off”. On the other hand, the RCA originates from mid third of the sinus is referred as posterior origin. Our findings claimed that males (68%) have been more likely to develop anomalies of RCA than females (32%). Likewise, many published data postulated that male have been more affected with coronary artery anomalies, however, no data exist that specifically focus on male predominance in AORCA.

We aware that our research may have some limitations. First, our study is a descriptive one as it has not possible to

compare the findings with those achieved using other modalities. Finally, it is a single center study; hence the findings might not be actual representation of the entire Indian population.

## CONCLUSIONS

From the outcome of our investigation it is possible to conclude that AORCA has been highly prevalent in India. The most common risk factor associated with the progression of anomalies of RCA was diabetes mellitus. The origin of RCA from very high origin was most frequent in Indian population.

## REFERENCES

1. Angelini P. Coronary Artery Anomalies. *Circulation*. 2007;115(10):1296-305.
2. Diwan Y, Diwan D, Chauhan R, Negi P. Coronary artery anomalies in North Indian population: a conventional coronary angiographic study. *National Journal of Clinical Anatomy*. 2017;06:250-7.
3. Garg N, Tewari S, Kapoor A, Gupta DK, Sinha N. Primary congenital anomalies of the coronary arteries: a coronary: arteriographic study. *Int J Cardiol*. 2000; 74(1):39-46.
4. Angeli E, Napoleone CP, Oppido G, Martín-Suàrez S, Gargiulo G. Anomalous origin of additional coronary artery arising from the pulmonary artery in complex congenital heart disease. *Cardiovascular Pathology*. 2008;17(3):190-1.
5. Tavaf-Motamen H, Bannister SP, Corcoran PC, Stewart RW, Mulligan CR, DeVries WC. Repair of anomalous origin of right coronary artery from the left sinus of Valsalva. *Ann Thorac Surg*. 2008;85(6): 2135-6.
6. White NK, Edwards JE. Anomalies of the coronary arteries; report of four cases. *Arch Pathol*. 1948;45(6):766-71.
7. Man-Hong J, Siu C-W, Hee-Hwa H. Anomalous origin of the right coronary artery from the left coronary sinus is associated with early development of coronary artery disease. *J Invasive Cardiol*. 2004;16:466-8.
8. Llerena L, Mendoza-Rodriguez V, Olivares-Aquiles E. Aberrant origin of right coronary artery from left coronary sinus and course

- between the great arteries diagnosed by 64-slice computed tomography. *The Internet J Cardiol.* 2009;7:15-22.
9. Ho JS, Strickman NE. Anomalous origin of the right coronary artery from the left coronary sinus: case report and literature review. *Tex Heart Inst J.* 2002;29(1):37-9.
  10. Kaku B, Shimizu M, Yoshio H, Ino H, Mizuno S, Kanaya H, et al. Clinical features of prognosis of Japanese patients with anomalous origin of the coronary artery. *Jpn Circ J.* 1996;60(10):731-41.
  11. Fujimoto S, Kondo T, Orihara T, Sugiyama J, Kondo M, Kodama T, et al. Prevalence of anomalous origin of coronary artery detected by multi-detector computed tomography at one center. *J Cardiol.* 2011; 57(1):69-76.
  12. Erol C, Seker M. Coronary artery anomalies: the prevalence of origination, course, and termination anomalies of coronary arteries detected by 64-detector computed tomography coronary angiography. *J Comput Assist Tomogr.* 2011; 35(5):618-24.
  13. Xu H, Zhu Y, Zhu X, Tang L, Xu Y. Anomalous coronary arteries: depiction at dual-source computed tomographic coronary angiography. *J Thorac Cardiovasc Surg.* 2012;143(6):1286-91.
  14. Ogino H, Miki S, Ueda Y, Tahata T, Morioka K. High origin of the right coronary artery with congenital heart disease. *Ann Thorac Surg.* 1999;67(2):558-9.
  15. Dodd JD, Ferencik M, Liberthson RR, Cury RC, Hoffmann U, Brady TJ, et al. Congenital anomalies of coronary artery origin in adults: 64-MDCT appearance. *American Journal of Roentgenology.* 2007;188(2):W138-W46.
- How to cite this article: Bolinera SV, Soma S, Reddy SS et.al. Prevalence of origination and course of anomalies of right coronary artery in Indian patients. *International Journal of Research and Review.* 2020; 7(10): 258-262.

\*\*\*\*\*