

Efficacy of Toric Intraocular Lens versus Opposite Clear Corneal Incision on Astigmatism Correction in Cataract Surgery

Dr Neebha Anand¹, Dr A K Khurana², Dr Kamal Garg³

¹Professor, ²Senior Professor,
Regional Institute of Ophthalmology, PGIMS, Rohtak, Haryana, India
³Resident, PGIMS, Rohtak

Corresponding Author: Dr Neebha Anand

ABSTRACT

Aim: To study the role of opposite clear corneal incision (OCCI) and toric IOL in correcting pre-existing astigmatism and to compare their efficacy for correcting pre-existing astigmatism in phacoemulsification in cataract surgery.

Material and Methods: The study was a prospective study conducted in a tertiary care hospital in North India and included 50 eyes of 50 patients of age >40 years with visually significant cataract and pre-existing regular corneal astigmatism from 1.0 D to 3.0 D divided into two groups of 25 each. Group 1 had toric IOL implantation and Group 2 underwent paired 3.20 mm OCCIs on the steep axis with spherical IOL implantation. UCVA & BCVA, refraction and toric IOL axis rotation were measured postoperatively on day 1, day 7, 1 month, 2 month and 3 month.

Results: In our analysis 84% and 76% eyes in gp 1 and gp 2, resp., had uncorrected visual acuity (UCVA) of 6/9 or better .96% eyes in both the groups attained 6/9 or better best corrected visual acuity (BCVA) at 3 month post-operatively. Mean refractive cylinder decreased significantly from preop to postop, 2.19 ± 0.45 D to 0.26 ± 0.36 D in group 1 (Toric) and 1.58 ± 0.45 D to 0.43 ± 0.38 D in group 2 (OCCI). The mean reduction in refractive cylinder was 1.93D in the toric IOL group and 1.15D in OCCI group. There was statistically significant difference in correcting astigmatism in the two groups.

Conclusion- Toric IOL implantation achieved an enhanced effect over OCCIs in treating pre existing astigmatism in patients undergoing cataract surgery. No significant toric IOL axis rotation was noted in any eye.

Key Words: Toric, OCCI (Opposite clear corneal incision), SIA (Surgical induced astigmatism), UCVA, BCVA.

INTRODUCTION

Present day cataract surgery aims at not only cataract removal but also correction of pre-existing spherical as well as cylindrical component of refraction, and so is rightly called 'refractive cataract surgery'. The spherical refractive error can be eliminated through a meticulously performed accurate IOL power calculation, while control of final postoperative

astigmatism during cataract surgery involves management of pre-existing astigmatism (PEA) and minimising surgically induced astigmatism (SIA). [1] It has been estimated that 15-29% of patients with cataract have more than 1.5 D of pre-existing astigmatism. [2] In a general cataract population, approximately 10% of patients have astigmatism with greater than 2 D of cylinder, 20% have between 1 and 2 D, and

70% have less than 1D. [3-6] Intraoperative management of corneal astigmatism include on axis corneal incision (OCI), limbal relaxing incision (LRI), opposite clear corneal incision (OCCI), toric IOL and two-stage procedure with excimer laser ablation. [7]

A clear corneal incision (CCI) flattens the meridian in which it is placed, with a coupling effect that steepens the perpendicular meridian 90 degree away. [8] Clear corneal incision of 4.0 to 5.0 mm will create hemimeridional change. If, however, the CCI is repeated diametrically opposite the initial incision and if both incisions are placed on the steep meridian, symmetry will occur in the flattening of the steep meridian. This is the concept of OCCI proposed by Lever and Dahan. [9]

Toric IOL implantation, another option for astigmatism correction in cataract patients. The first toric IOL was devised by Shimizu et al in 1992. [10] In 2005, the one-piece acrylic Acrysof Toric IOL got FDA approval. The lens was noted to have excellent rotational stability with less than 4° of rotation reported at 1 year. [11] Toric IOLs are considered for patients with more than 1.0D of regular corneal astigmatism. Literature has various studies comparing the toric lenses versus OCCI to correct astigmatism during cataract surgery. However, only a few studies on Indian population. Further, many patients can not afford toric IOL. Keeping in view the above fact, the present study was planned to perform a comparative evaluation of the effect of OCCI versus toric IOL implantation in correction of preexisting astigmatism after phacoemulsification.

MATERIAL AND METHODS

After ethical clearance from the ethical board, the present prospective study was conducted on 50 eyes of 50 patients age >40 years with pre-existing regular corneal astigmatism from 1.0 D to 3.0 D reporting to the OPD of a tertiary care health institute in North India for undergoing cataract surgery. Patients with previous corneal or

intraocular surgery, preoperative regular corneal astigmatism greater than 3.0 D, history of corneal disease, pterygium, abnormal iris, pupil deformation, macular degeneration, retinopathy, neuroophthalmic disease, previous ocular inflammation, oblique/irregular astigmatism like keratoconus were excluded from the study. Informed consent was taken from all the enrolled patients. Detailed history to exclude any ocular pathology or history of any systemic disease like hypertension, cardiovascular disease and diabetes mellitus was taken. All surgeries were performed by a single surgeon. Patients were randomized into two groups. Group I underwent phacoemulsification with Toric IOL and OCCI was done in group II patients. In the Toric group preoperative keratometry and biometry data, incision location, and the surgeon's estimated surgically induced corneal astigmatism were used to determine the appropriate toric IOL power, spherical equivalent (SE) lens power, and axis of placement in the eye. The determination of model of toric IOL to be implanted and the axis at which it should be placed with an aim of minimum residual cylinder were calculated using online calculator program available at www.caregroupindia.com. Precise reference marking of the cornea done with the patient upright and looking forward in a sitting position so as to avoid cyclotorsion. Using a sterile marker, the 3, 6 and 9 o'clock points were marked at the corneal edge. Next, with the patient lying on the surgical table, the steep axis of cornea was marked before implantation of IOL. After phacoemulsification, a foldable toric IOL was implanted in the capsular bag. The IOL was rotated to align the cylinder axis with the marked steep corneal meridian. Viscoelastic removed from anterior and posterior to IOL to avoid post operative IOL rotation. In the OCCI group before surgery, the steep axis of the cornea was marked as in the toric group. A self-sealing 2.75 to 3.20mm CCI was created 1.00mm anterior to the limbus using a keratome. Phacoemulsification was performed and the

IOL was inserted. A second CCI was made 180 degrees from the first incision after IOL implantation and before irrigation/aspiration of the viscoelastic. Size of the OCCI was finalized according to the nomogram described by Lal. [12] In cases with a vertical steep axis, phacoemulsification was done through the superior approach and with a horizontal steep axis, the temporal approach was used. Patients were examined postoperatively on day 1, day 7, 1st month, 2nd month and 3rd month. Uncorrected visual acuity (UCVA) and best corrected visual acuity (BCVA) was assessed and residual refractive error including astigmatism recorded in all patients. Slit lamp examination on all visits to assess the position of IOL was done after pupillary dilation. At the end of study, the data was compiled and statistically analysed.

Statistical Analysis

The data was analysed using IBM SPSS Statistics software (subscription version).

The quantitative variables were represented as mean and standard deviation and the qualitative variables were represented as proportions. The statistical difference between the two groups for quantitative variables was detected by using Independent t-test whereas for qualitative variables was detected by using Chi-square test. For detecting statistical difference in same group over the period of time during follow ups, repeated measures ANOVA test was used with paired-test as post-hoc test for detecting difference between any two points of time. P-value of <0.05 was considered to be statistically significant.

RESULT

The mean age of the study population in group 1 was 64.04 ± 10.97 year and group 2 was 63.52 ± 7.97 year. The majority of the patients in both the groups were between 56-65 years of age (group I- 40.0% and group II – 48.0%) as depicted in Figure 1.

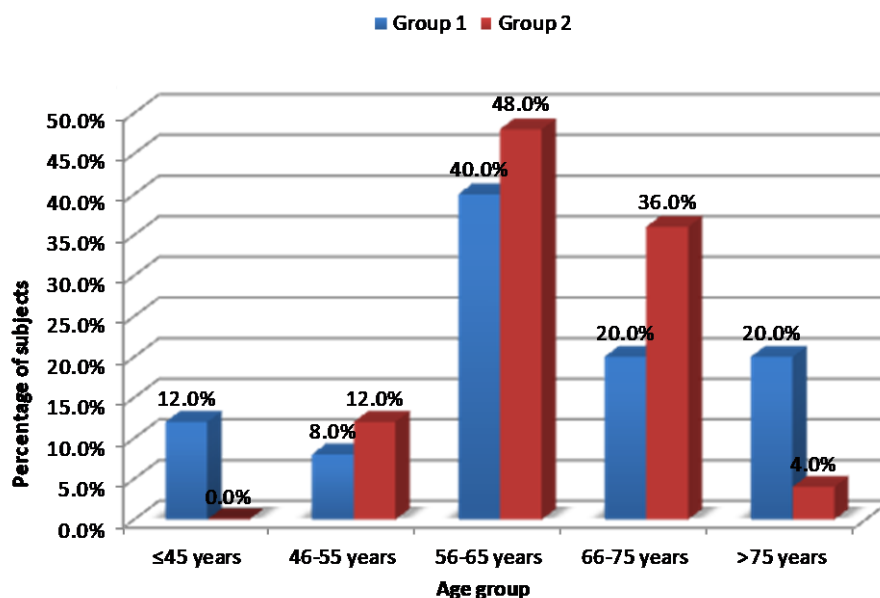


Figure 1: Distribution of subjects according to age in Group 1 and 2 (n=50)

The mean corneal astigmatism measured pre-operatively in the study patients in group I was 2.05 ± 0.51 dioptres and the mean in group II was 1.42 ± 0.47 dioptres as shown in Table 1.

Table 1: Pre-operative mean corneal astigmatism in Group 1 and 2 (n=50).

Characteristic	Group 1 (n=25)	Group 2 (n=25)	Significance
Mean corneal astigmatism (±S.D.)	$2.05 \pm 0.51D$	$1.42 \pm 0.47D$	$p < 0.001$

The mean preoperative refractive spherical was 0.89 ± 1.08 and 0.27 ± 0.53 in group 1 and group 2 and mean preoperative refractive cylinder was 2.19 ± 0.45 and 1.58 ± 0.45 in group 1 and group 2 respectively as shown in Table 2.

Table 2: Pre-operative mean refractive error findings in Group 1 and 2 (n=50)

Characteristic	Group 1 (n=25)	Group 2 (n=25)	Significance
Mean spherical error (\pm S.D.)	0.89 ± 1.08	0.27 ± 0.53	p=0.014
Mean cylindrical error (\pm S.D.)	2.19 ± 0.45	1.58 ± 0.45	p<0.001

Post-operatively after 1 week, 56% eyes in both the groups had uncorrected visual acuity of 6/9 or better whereas 84% and 76% eyes in group 1 and group 2, respectively had uncorrected visual acuity of 6/9 or better at last follow-up). Only two patients in group 1 had corneal edema 1 week post cataract extraction as shown in Table 3.

Table 3: Distribution of subjects according to post-operative un-corrected visual acuity (UCVA) findings in Group 1 and 2 on various follow up visits (n=50)

UCVA (LogMar)	After 1 week		After 4 weeks		After 8 weeks		After 12 weeks	
	Group 1 (n=25)	Group 2 (n=25)	Group 1 (n=25)	Group 2 (n=25)	Group 1 (n=25)	Group 2 (n=25)	Group 1 (n=25)	Group 2 (n=25)
>6/9 (0.1761)	14 (56.0%)	14 (56.0%)	21 (84.0%)	18 (72.0%)	21 (84.0%)	18 (72.0%)	21 (84.0%)	19 (76.0%)
6/12 (0.3010)	8 (32.0%)	7 (28.0%)	4 (16.0%)	5 (20.0%)	4 (16.0%)	7 (28.0%)	4 (16.0%)	6 (24.0%)
6/18 (0.4771)	1 (4.0%)	3 (12.0%)	0 (0.0%)	2 (8.0%)	-	-	-	-
6/24 (0.6021)	0 (0.0%)	1 (4.0%)	-	-	-	-	-	-
Complaint of edema	2 (8.0%)	0 (0.0%)	-	-	-	-	-	-
Significance*	p=0.388		p=0.403		p=0.434		p=0.356	
Mean UCVA (\pm S.D.)	0.2250 (\pm 0.0933)	0.2431 (\pm 0.1505)	0.1468 (\pm 0.1037)	0.1970 (\pm 0.1246)	0.1115 (\pm 0.1173)	0.1547 (\pm 0.1200)	0.1045 (\pm 0.1186)	0.1497 (\pm 0.1162)
Significance	p=0.622		p=0.128		p=0.205		p=0.180	

In both the groups 96% eyes attained 6/9 or better, best corrected distance visual acuity at last follow-up (after 12 wks) as shown in Table 4.

Table 4: Distribution of subjects according to post-operative best-corrected visual acuity (BCVA) findings in Group 1 and 2 on various follow up visits (n=50)

BCVA (LogMar)	After 1 week		After 4 weeks		After 8 weeks		After 12 weeks	
	Group 1 (n=25)	Group 2 (n=25)	Group 1 (n=25)	Group 2 (n=25)	Group 1 (n=25)	Group 2 (n=25)	Group 1 (n=25)	Group 2 (n=25)
>6/9 (0.1761)	20 (80.0%)	18 (72.0%)	24 (96.0%)	23 (92.0%)	24 (96.0%)	24 (96.0%)	24 (96.0%)	24 (96.0%)
6/12 (0.3010)	2 (8.0%)	7 (28.0%)	1 (4.0%)	2 (8.0%)	1 (4.0%)	1 (4.0%)	1 (4.0%)	1 (4.0%)
6/18 (0.4771)	1 (4.0%)	0 (0.0%)	-	-	-	-	-	-
Complaint of edema	2 (8.0%)	0 (0.0%)	-	-	-	-	-	-
Significance	p=0.279		p=0.217		p=0.118		p=0.356	
Mean BCVA (\pm S.D.)	0.1618 (\pm 0.1112)	0.1759 (\pm 0.1049)	0.0895 (\pm 0.0982)	0.1368 (\pm 0.0935)	0.0543 (\pm 0.0920)	0.1036 (\pm 0.0969)	0.0543 (\pm 0.0920)	0.1036 (\pm 0.0969)
Significance	p=0.622		p=0.128		p=0.205		p=0.180	

The minor difference in the mean value between the groups was not statistically significant. Mean residual cylindrical refractive error at 1 week follow-up visit in group 1 was 0.30 ± 0.37 D which changed to 0.27 ± 0.36 D at 12 weeks and in group 2 was 0.51 ± 0.44 D and 0.43 ± 0.38 D, respectively. The change in the refractive error was mostly seen in 1 week post cataract extraction after that it remained almost constant (Figure 2).

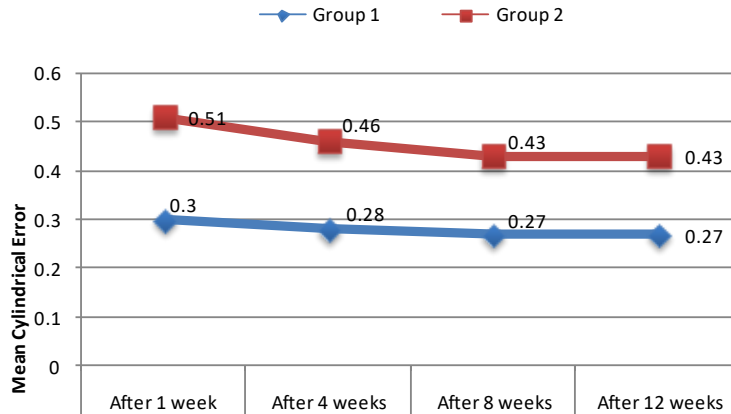


Figure 2: Post-operative mean cylindrical refractive error in Group 1 and 2 on various follow up visits (n=50)

There was a significant improvement in mean UCVA from 0.83 to 0.10 and 0.92 to 0.14 and the mean BCVA from pre-operatively to post-operatively from 0.75 to 0.05 and 0.83 to 0.10 in group 1 and 2 patients respectively as shown in Table 5.

Table 5: Comparison between preoperative and 3 months postoperative visual acuity in Group 1 and 2 (n=50)

Characteristic	Group 1 (n=25)			Group 2 (n=25)		
	Pre-operative	Post-operative	Significance	Pre-operative	Post-operative	Significance
Mean UCVA(Log MAR) (±S.D.)	0.8383 (±0.1302)	0.1045 (±0.1186)	p<0.001	0.9208 (±0.1609)	0.1497 (±0.1162)	p<0.001
Mean BCVA(Log MAR) (±S.D.)	0.7535 (±0.1446)	0.0543 (±0.0920)	p<0.001	0.8323 (±0.1953)	0.1036 (±0.0969)	p<0.001

Mean refractive cylinder decreased significantly preoperatively to postoperatively 2.19 (±0.45)D to 0.26 (±0.36)D in group 1 (Toric) and 1.58 (±0.45)D to 0.43(±0.38)D in group 2 (OCCI) as shown in Table 6 and Figure 3

Table 6: Comparison between preoperative and 3 months postoperative manifest refraction in Group 1 and 2 (n=50)

Characteristic	Group 1 (n=25)			Group 2 (n=25)		
	Pre-operative	Post-operative	Significance	Pre-operative	Post-operative	Significance
Mean spherical error (±S.D.)	0.89 (±1.08)	0.15 (±0.37)	p=0.004	0.27 (±0.53)	0.05 (±0.20)	p=0.069
Mean cylindrical error (±S.D.)	2.19 (±0.45)	0.26 (±0.36)	p<0.001	1.58 (±0.45)	0.43 (±0.38)	p<0.001

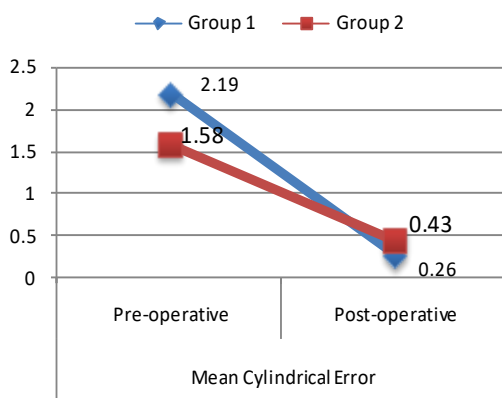


Figure 3: Comparison between preoperative and 3 months postoperative cylindrical refractive error in Group 1 and 2 (n=50)

The position of the IOL was noted at each follow-up visit under full dilation of pupils. The axis of IOL was measured with the reticule on slit lamp. No eye had secondary surgery to reposition the IOL axis within the 3-month postoperative period. There was no significant IOL rotation (<10 degree) in any eye. The mean toric IOL axis rotation was 0.92 ± 2.53 . Only two eyes had IOL rotation of 9 degree, rotation was less than 5 degree in all other eyes (Table 7).

Table 7: The Degree of IOL rotation at various follow-up visits in Group 1 patients

Group 1	Number of patients		
	< 5 ⁰	6 - 10 ⁰	> 10 ⁰
1 Week	25	2	0
1 Month	25	2	0
2 Month	25	2	0
3 Month	25	2	0

DISCUSSION

In the present study the mean age of the patients of group 1 was 64.04 ± 10.97 years ranging from 40-83 years. The above age is comparable with the age group of patients as reported by Ivanka Petric and colleagues [13] (46-78years) who implanted the AT TORBI 709 model toric IOL and the mean age in their study was 64 years. The mean age of the patients in group 2 was 63.52 ± 7.97 . Reports in the literature show wide variability in age groups of patients undergoing phacoemulsification and toric IOL implantation. Visser et al [14] analysed 40 eyes that underwent toric IOL implantation with a mean age of $52.3 + 19.1$ years. In a similar study carried out by Venkataraman et al [15] in South India the average age of 77 patients undergoing toric IOL implantation was $56 + 13.88$ years. The decrease in the mean age of the patients undergoing phacoemulsification and toric IOL implantation in recent studies can be attributed to an increased safety and reliability of modern day phacoemulsification techniques and thus patients opting for early surgery. The mean corneal astigmatism measured pre-operatively in group I (Toric) was 2.05 ± 0.51 dioptres and the mean in group II (OCCI) was 1.42 ± 0.47 dioptres. The mean

corneal astigmatism in a study conducted by Ferreira et al [16] who implanted Prezicontoric intra ocular lens in 51 eyes of 39 patients was 1.98 ± 0.72 dioptres.

In our analysis 84% and 76% eyes in group 1 and group 2, respectively, had UCVA of 6/9 or better and 96% eyes in both the groups attained 6/9 or better BCVA 3 month post-operatively. There was a significant improvement in mean logMAR UCVA from 0.83 to 0.10 and 0.92 to 0.14 pre-operatively to 3 month post-operatively and the mean logMAR BCVA from 0.75 to 0.05 and 0.83 to 0.10 in group 1 and 2 patients, respectively. The above results were comparable with the observation of Hoffmann et al [17] who reported an improvement of meanlog MARUCVA from 0.93 to 0.20and the mean logMAR BCVA from 0.41 to 0.09.

The mean refractive cylinder decreased significantly from preoperatively to 3 month postoperatively $2.19 \pm 0.45D$ to $0.26 \pm 0.36D$ in group 1 (Toric) and $1.58 \pm 0.45D$ to $0.43 \pm 0.38D$ in group 2 (OCCI). The mean reduction in refractive cylinder was 1.93D in the toric IOL group and 1.15D in OCCI group. Our results are better compared to those reported by Mendicute et al, [18] where 40 eyes of 40 patients were evaluated and mean refractive cylinder decreased significantly preoperatively to postoperatively 1.75 ± 0.71 to $0.62 \pm 0.46 D$ in the toric group; 1.61 ± 0.67 to $0.97 \pm 0.51 D$ in OCCI group and the mean reduction was 1.13D in the toric group and 0.64D in OCCI group.

Table 8. The reported residual refractive cylinder rates in literature and present study.

Toric IOL	Study	Year	Follow-up	Residual Refractive astigmatism	
				< 0.50 D	< 1.00 D
Acrysof	Lane	2009	6 month	60%	95%
	Ahmed	2010	6 month	71%	90%
Tecnis	Ferreira TB	2012	2 month	75%	100%
AT TORBI	Bascaran	2013	6 month	95.2%	100%
ACRIOL _{EC} toric (Care Group)	Current study	2018	3 month	92%	96%
OCCI	Mendicute [18]	2009	3 month	70%	100%
	Current study	2018	3 month	68%	100%

The major requirement for toric IOLs is rotational stability. In Toric IOL group, rotation of 5⁰ or less from its

intended axis was seen in 92% and of 10⁰ or less in 100% at 3 months postoperatively. In none of the cases IOL repositioning was

required. The largest rotation was 9 degrees and was seen in only two eyes. Most IOL rotation occurred in the early postoperative period. Once the anterior and posterior capsules fused, IOL rotation was less frequent at long-term follow-up.

CONCLUSION

Toric IOL implantation achieved an enhanced effect over OCCIs in treating pre-existing astigmatism in patients undergoing cataract surgery. No significant toric IOL axis rotation was noted in any eye.

Conflict Of Interest - None

REFERENCES

1. Khurana AK. Astigmatism control in cataract surgery. In: Disorders of lens and cataract surgery. New Delhi, CBS Publishers & Distributors Pvt. Ltd., 1st ed 2014:289-309.
2. Hoffer KJ. Biometry of 7500 cataractous eyes. *Am J Ophthalmol* 1980;90:360-8.
3. Nichamin LD. Astigmatism control. *Ophthalmology clinics of North America* 2006; 19:485-93.
4. Chen W, Zuo C, Chen C, Su J, Luo L, Congdon N et al. Prevalence of corneal astigmatism before cataract surgery in Chinese patients. *J cataract Refract Surg* 2013;39:188-92.
5. Ferrer-Blasco T, Montes-Mico R, Peixoto-de-Matos SC, Gonzalez-Meijome JM, Cervino A. Prevalence of corneal astigmatism before cataract surgery. *J cataract Refract Surg* 2009; 35:70-5.
6. Hoffmann PC, Hutz WW: Analysis of biometry and prevalence data for corneal astigmatism in 23,239 eyes. *J cataract Refract Surg* 2010; 36:1479-85.
7. Brinton JP, Oetting TA. Considerations for astigmatism management. *J Cataract Refract Surg* 2011;6:37-50.
8. Gross RH, Miller KM. Corneal astigmatism after phacoemulsification and lens implantation through unsutured sclera and corneal tunnel incisions. *Am J Ophthalmol.* 1996;121:57-64.
9. Lever J, Dahan E. Opposite clear corneal incisions to correct pre-existing astigmatism in cataract surgery. *J Cataract Refract Surg* 2000;26:803-5.
10. Shimizu K, Misawa A, Suzuki Y. Toric intraocular lenses: correcting astigmatism while controlling axis shift. *J Cataract Refract Surg* 1994; 20:523-6.
11. Holland E, Lane S, Horn JD, Ernest P, Arleo R, Miller KM. The AcrySof Toric intraocular lens in subjects with cataracts and corneal astigmatism: a randomized, subject-masked, parallel-group, 1-year study. *Ophthalmol.* 2010;117:2104-11.
12. Lal H. Nomogram. Available at: www.ejournalophthalmology.com.
13. Vickovic IP, Loncar VL, Mandic Z, Ivekovic R, Herman JS, Sesar A. Toric intraocular lens implantation for astigmatism correction in cataract surgery. *Acta Clin Croat* 2012 Jun; 51(2):293-7.
14. Visser N, Beckers HJ, Bauer NJ, Gast ST, Zijlmans BL, Berenschot TT et al. Toric vs aspherical control intraocular lenses in patients with cataract and corneal astigmatism: a randomized clinical trial. *JAMA Ophthalmol* 2014;132(12):1462-8.
15. Venkataraman A, Kalpana. Visual outcome and rotational stability of open loop toric intraocular lens implantation in Indian eyes. *Indian J Ophthalmol* 2013;61(11):626-9.
16. Ferreira TB, Berenschot TT, Ribeiro FJ. Clinical outcomes after cataract surgery with a new transitional toric intraocular lens. *J Cataract Refract Surg* 2016;32(7):452-458.
17. Hoffmann PC, Auel S, Hutz WW. Results of higher power toric intraocular lens implantation. *J Cataract Refract Surg* 2011; 37:1411-18.
18. Mendicute J, Irigoyen C, Ruiz M, Illarramendi I, Blasco TF, Mico RM. Toric intraocular lens versus opposite clear corneal incision to correct astigmatism in eyes having cataract surgery. *J Cataract Refract Surg* 2009;35:451-8.

How to cite this article: Anand N, Khurana AK, Garg K. Efficacy of toric intraocular lens versus opposite clear corneal incision on astigmatism correction in cataract surgery. *International Journal of Research and Review.* 2019; 6(7):157-163.
