

Case Report

## Subcutaneous Human Dirofilariasis - A Rare Case Report

Dr. Deepthi. J. S, Dr. Vamseedhar Annam, Dr. Shashikala. K., Dr. Anubhav. C.

Rajarajeswari Medical College and Hospital, Bangalore.

Corresponding Author: Dr. Vamseedhar Annam

### ABSTRACT

Human Dirofilariasis is a rare zoonotic infection caused by genus *Dirofilaria*, which includes more than 40 different species. Human Dirofilariasis caused by *D. repens* has not been widely recognized in India. Most of the documented cases of human Dirofilariasis recorded in India have presented with ocular manifestations. We report a rare case of subcutaneous human Dirofilariasis.

**Keywords:** Subcutaneous, Dirofilaria, Cyst, Left iliac fossa.

### INTRODUCTION

Human dirofilariasis is a cosmopolitan zoonosis. Dirofilaria are long thin parasitic round worms that infect a variety of mammals. Infections are mainly transmitted by mosquito bites (*Culex*, *Aedes*, *Anopheles*). 6 out of 40 species of Dirofilaria i.e. *D. immitis*, *D. repens*, *D. straita*, *D. tenuis*, *D. ursi* and *D. spectans* are known to cause diseases in humans. <sup>(1)</sup> *D. repens* and *D. immitis* are increasingly reported as human pathogens. *D. immitis* is a common parasite of canine cardiovascular system and a potential human pulmonary pathogen. *D. repens*, commonly found in the subcutaneous tissues of dogs, has also been reported as human pathogen from different parts of the world.

### CASE REPORT

A 16 years old male presented with progressive increase in size of the swelling in left iliac fossa since one week duration. Local examination of the swelling measured 3X2 cms, mobile, firm in consistency with mild tenderness. Routine laboratory

investigations that included hematology and clinical pathology were within normal limits. Ultrasonography was reported as a possibility of cystic lesion possibility of parasitic etiology (fig 1). A provisional clinical diagnosis of parasitic cyst probably cysticercosis was considered. The swelling was excised and sent for histopathological examination.

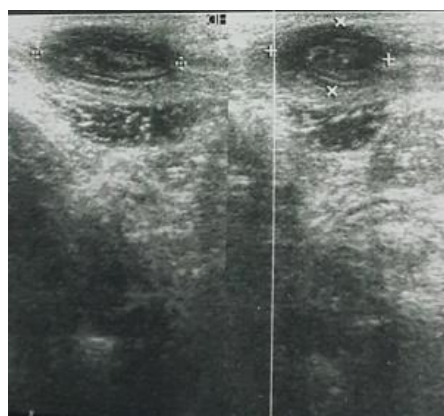

FIG.1: Ultrasonography suggesting a Cystic Lesion with possibility of parasitic infection.

**MACROSCOPY:** A nodular specimen measuring 2.5x2x1 cms was received. Cut section revealed a central cystic area. (Fig 2, 3).

### MICROSCOPY:

H & E stained sections showed a cystic space surrounded by dense inflammatory cells, predominantly eosinophils. The cystic space exhibited a cross section of a nematode parasite having thick cuticle with fine external spikes and a prominent circumferential muscle layer showing

transverse striations, double uterus and a gut (fig 4,5). Based on these morphological features, the parasite was identified as an adult female *Dirofilaria repens*. A final diagnosis of subcutaneous *Dirofilariasis* was made.

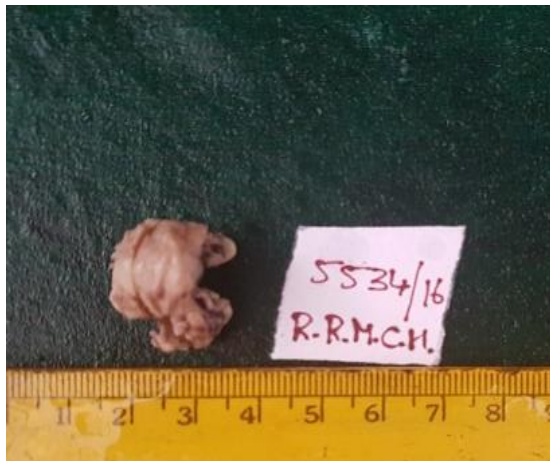

FIG.2

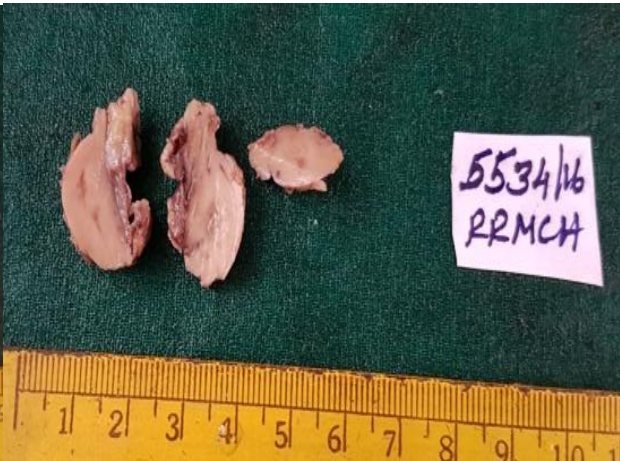


FIG.3

Fig 2 & 3 Nodular specimen with a central cystic area.

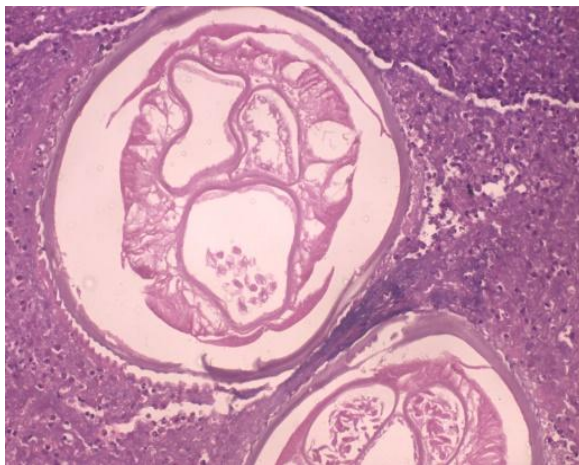


FIG.4 [H&E STAIN, X100]

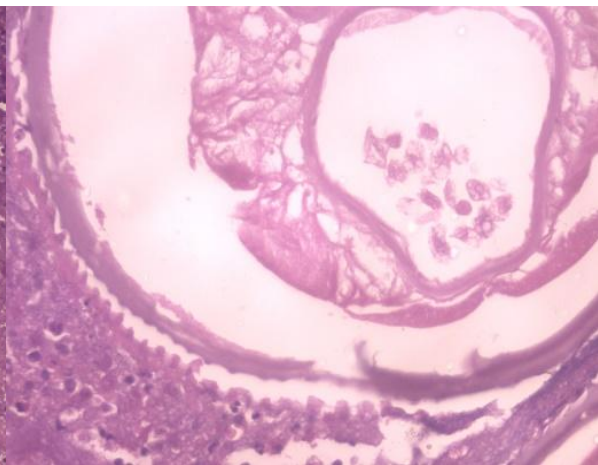


FIG.5 [H&E STAIN, X400]

Fig 4 & 5 [H&E stain] showing parasite having thick cuticle with fine external spikes and a prominent muscle layer.

### DISCUSSION

The genus *Dirofilaria* includes various species that are natural parasites of dogs, cats, foxes and wild mammals. Human dirofilariasis due to *D. repens* has been widely reported from European countries such as Italy, France, Greece and Spain. Sri Lanka is the most affected country in Asia. In India, though Kerala state seems to be the focus for human *Dirofilariasis*, few cases have also been

reported from Coastal Karnataka, Assam and Orissa. A review of the literature showed about 402 cases of Human subcutaneous dirofilariasis worldwide. (2) Subcutaneous nodules due to *Dirofilariasis* occur in exposed areas of the body such as face, orbits, upper limb, lower limb, chest wall and male genitalia. Man is an accidental dead end host. *D. repens* larvae are inoculated by the bite of an infected

insect and can invade a variety of tissues, where they mature into adult worms and die.

Almost all human infections by *D. repens* are localized to the upper half of the body, mostly in and around the eyes, although, it can occur in the extremities and thoracic wall as well. The important risk factors regarding human infections are mosquito density, warm climate with an extended mosquito breeding season, outdoor human activities and close contact with dogs. Even though, *Culex*, *Aedes* and *Anopheles* mosquitoes are the vectors for this parasite, information is lacking on which mosquito vector is involved in transmission of *D. repens* in Southern India. (3)

The definite diagnosis of human subcutaneous *Dirofilariasis* can be made after surgical excision or biopsy. Blood eosinophilia or elevated serum IgE levels are rarely observed. Therefore, eosinophilic counts and measurements of total IgE are of limited value in screening for *Dirofilariasis* in patients with subcutaneous nodules. (4) Surgical removal of the worm/nodule not only establishes the diagnosis in most of the cases, but also provides a definitive cure. There is no need for chemotherapy, because microfilaremia is extremely rare. Human infection with *D. repens* has been increasing in the world; many of them remain undiagnosed or unpublished. (5)

## CONCLUSION

How to cite this article: Deepthi. JS, Annam V, Shashikala. K et.al. Subcutaneous human *dirofilariasis* - a rare case report. *International Journal of Research and Review*. 2019; 6(5):56-58.

\*\*\*\*\*

In our case, the presentation was unusual as the asymptomatic swelling in left iliac fossa with negative peripheral microfilaremia and eosinophilia. The diagnosis was mainly based on the histopathological examination of Nematode on biopsy tissue.

It is emphasized that, both clinician and pathologist should have an increased awareness of this entity and include *Dirofilariasis* in the differential diagnosis of subcutaneous nodules at any site.

## REFERENCES

1. Reddy MV. Human *dirofilariasis*: An emerging zoonosis. *Trop Parasitol* 2013; 3:2-3.
2. Padmaja P, Kanagalakshmi, Samuel R. Subcutaneous *dirofilariasis* in southern India: A case report. *Ann Trop Med Parasitol* 2005; 99:437-40.
3. Permi HS, Veena S, Kishan Prasad HL, Kumar YS, Mohan R, Shetty KJ. Subcutaneous human *dirofilariasis* due to *Dirofilariarepens*: Report of two cases. *J Glob Infect Dis* 2011; 3:199-201.
4. Maltezos ES, Sivridis EL, Giantromanolaki AN, Simopoulos CE. Human subcutaneous *dirofilariasis*: A report of three cases manifesting as breast or axillary nodules. *Scott Med J* 2002; 47:86-8.
5. Sathyan P, Manikandan P, Bhaskar M, Padma S, Singh G, Appalaraju B. Subcutaneous infections by *Dirofilaria repens*. *Indian J Med Microbiol* 2006; 24; 61-2.