

Retropupillary Iris-Claw Lens Implantation in Aphakic Eyes without Capsular Support: Our Five Years Experience

Suraya Kounser¹, Rameez Ahmad¹, Khurshid Ahmad Ganaie²

¹Senior Resident, Department of Ophthalmology, SKIMS Medical College, Srinagar.

²Consultant Surgeon, Health Services Kashmir.

Corresponding Author: Khurshid Ahmad Ganaie

ABSTRACT

Objective. Among the choices of lens implantation like- iris-claw lenses, anterior chamber lenses and scleral or iris fixated lenses in aphakic eyes without capsular support, the iris-claw retropupillary lens implantation is gaining the popularity at present. Our aim of this study was to report the safety and efficacy of retropupillary iris-claw lens implantation in our institution.

Methods. In this study 29 eyes of 29 patients with aphakia without capsular support were included prospectively from 2013-2018. All the patients were evaluated properly and subsequently retropupillary iris-claw lens implantation was done.

Results. The mean age of patients was 62.3 years with SD of 11.2 years. Highest numbers of patients were in the age group of 60-70 years (43%). The mean follow-up of patients was 2.7 years ranging from two months to five years. Out of 29 eyes, 22 (75%) eyes had visual acuity of 6/9, three (10%) eyes had 6/12 and two eyes had 6/6 vision. The most common postoperative complication was subconjunctival hemorrhage, seen in 12 (41%) cases. Two eyes developed secondary glaucoma in postoperative period due to pupillary block. Retinal detachment was observed in one eye. We have not seen any case of bullous keratopathy, infection or cystoid macular edema till last follow-up.

Conclusion. In aphakic eyes without capsular support, retropupillary iris-claw lens implantation is easy to perform and gives us the good refractive outcome with all the physiological and optical advantages of posterior intraocular lens location at low risk of complication.

Key-Words. Aphakia, Iris-claw, Intra ocular lens.

INTRODUCTION

The iris claw implant was initially designed for use in aphakic eyes. This lens is fixated to the iris surface anteriorly by enclavation of a fold of iris tissue into two opposed claws of the lens. It was Worst in 1980 who invented iris-claw lens method in aphakic eyes in order to correct the refraction, which was a coplanar single-piece poly methyl methacrylate (PMMA) intra ocular lens. [1] Amar [2] proposed the technique of posterior fixation of iris-claw lens and later it was modified by Mohr et al. [3] By this technique the natural anatomy of

the eye is preserved. The fixation sites are located in the mid periphery of the iris, which is immobile during pupillary movement. This lens was later modified into a convex-concave design and was manufactured as Artisan/Verisyse lens and followed by a foldable model as Artiflex. [4] Although technically its implantation is relatively easy, but few disadvantages include the incision size, which if sutured usually generates astigmatism, and the relatively high cost of the lens. Early models needed to be sutured. The first-generation models of iris-claw lens such as the

Binkhorst [5,6] and the Medallion intra ocular lens [7] were associated with complications such as lens dislocation, glaucoma, cystoid macular oedema and uveitis. [8] The advantage of iris-claw lens is that it can be fixated to the iris without applying sutures because the peripheral iris is incarcerated between the claws, so implantation of this lens takes a few minutes only, thus the hypotonic open sky phase is shortened compared to combined surgery. [9,10]

MATERIALS AND METHODS

This study was conducted in the department of ophthalmology SKIMS medical college and hospital Srinagar, Kashmir. This was a prospective study in which 29 eyes of 29 patients of aphakia without capsular support were included from 2013-2018. All these eyes were aphakic due to post cataract surgery, and subsequently retro-pupillary implantation of iris-claw lens was done by the same team of surgeons. All these patients were informed in detail about the procedure, its risks and advantages, and written signed consent was obtained from the patients. The study design was approved by medical ethics committee of our institute. Demographic data was collected from the patients. In addition to this, data was also collected preoperatively about, best corrected visual acuity measured with snellen's decimal scale, intraocular pressure measured by goldmann applanation tonometry, refraction measured with auto refractometry, former operations, any previous disease and biometry measured with optical method. Only those eyes were included in the study who landed with post-cataract surgery aphakia resulted either from intra or post-operative complications. Patients having aphakia other than post-cataract surgery were excluded from the study, in addition to these patients with total aniridia or rubeosis iridis were excluded.

All eyes were operated under local anesthesia and used the same surgical technique. We used both rigid as well as foldable iris-claw intraocular lens. Either at 3 or 9 o'clock position corneal or

sclerocorneal paracentesis was done. Before injection of cohesive viscoelastic material through the incision, intracameral pilocarpine was injected for miosis, A 5.8 mm corneal incision was extended (in majority of eyes the existing cataract surgery site was used) followed by insertion of iris-claw intra-ocular lens (Figure-1) in to the anterior chamber and then by special lens fixation forceps moved to posterior chamber. Haptics of the iris-claw lens were attached to the iris at 3 and 9 o'clock position with the help of spatula. An intraocular lens dialer was used through the incision for iris enclavation by applying minimum gentle pressure over it through the slotted center of the IOL haptic. Peripheral iridectomies were performed in majority of cases. Corneal or sclerocorneal incision was closed with few interrupted nylon sutures. Finally antibiotic and steroid were injected sub-conjunctively. Afterwards postoperatively steroid and antibiotics were given to all patients four times daily for few days.

RESULTS

In this study we included 29 aphakic eyes without capsular support prospectively. The mean age of patients was 62.3 years with SD of 11.2 years. The patients ranged in age from 26–78 years. Highest number of patients 13 (44%) were in the age group of 60-70 year. Out of 29 patients 16 (55%) were males and 13 (45%) were females. The mean follow-up of patients was 2.7 years ranging from two months to five years. Postoperatively out of 29 eyes, 22 (75%) eyes had visual acuity of 6/9, three (10%) eyes had 6/12, two eyes had 6/6 vision, one eye had 6/24, and one patient had only perception of light and projection of rays in the follow-up period. The most common postoperative complication noted in this study was subconjunctival hemorrhage, seen in 12 (41%) cases. Superficial keratitis was noted in 10 (35%) eyes. In one case we have seen hyphaema postoperatively. The mean intraocular pressure at the end of follow-up was 15.9 ± 4.1 mmHg. Two eyes developed secondary glaucoma in postoperative period

due to pupillary block. In these cases we had not done iridectomy during intraocular lens implantation. Intraocular pressure remained >20 mmhg postoperatively in these cases. Retinal detachment was observed in one eye. In one eye we had subluxation of iris-claw intraocular lens which was refixated properly without any difficulty. Rest in all the cases the lens was central and in stable position (Figure-2). On the lens surface pigment dispersion was noted in two eyes, and in one eye iris atrophy was noted at enclavation site. Irregular pupil was noted in one eye. We have not seen any case of bullous keratopathy, infection or cystoid macular edema till last follow-up.

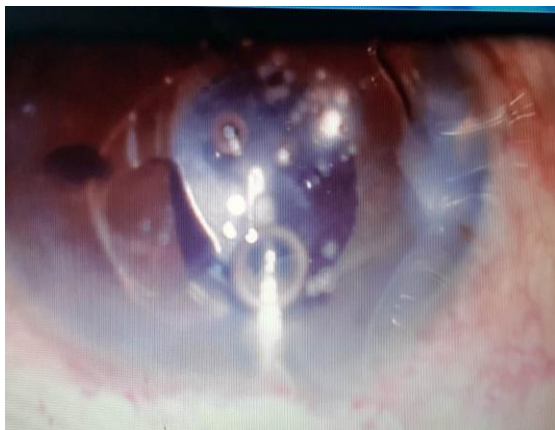

Figure- 1. Insertion of Iris-claw lens.

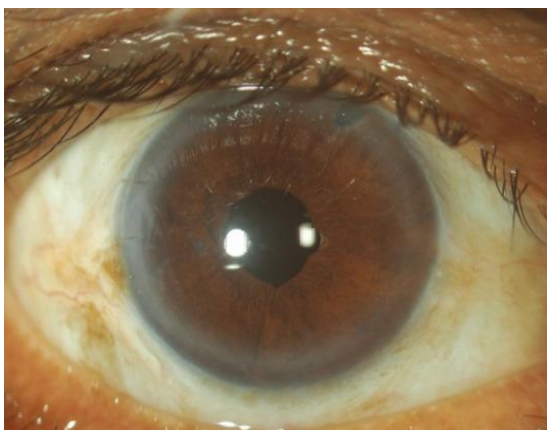


Figure- 2. After Eight weeks of Iris-claw lens implantation.

DISCUSSION

This was a prospective study in which 29 eyes were included from 2013-2018. Till now it is still considered a challenge and matter of discussion to treat aphakia without capsular support surgically,

because of various complications which are related to available treatment modalities. In patients of aphakic eyes, intraocular lens implantation had been done successfully in the anterior chamber by fixing the lens to anterior surface of iris. But this procedure carries more risk of decrease in the endothelial cell count. [11,12] While as, many studies have reported that retropupillary implantation of iris-claw lens does not show significant effect on endothelial cell count. [13,14]

In this study we have not observed any significant complication postoperatively which we could not manage at our hospital except in one case of retinal detachment. The most common complication in our study was minor subconjunctival hemorrhage, which disappeared within few days without any further treatment. Many studies regarding implantation of retropupillary iris-claw intraocular lens noted pigment dispersion as a complication. [13,14] Our study also showed pigment dispersion in two patients which was at par with these studies. One major complication we noted postoperatively was secondary glaucoma, which occurred in two cases. In these two cases we had not done iridectomy at the time of lens implantation. These were managed by laser iridotomy in the follow-up period successfully and we were able to achieve a desirable intraocular pressure in them. Few studies have correlated retinal detachment though rarely with implantation of iris-claw intraocular lens. [15,16] In our series of cases we had one case of retinal detachment till last follow-up. This patient had undergone vitrectomy at the time of lens implantation. Retinal detachment had been observed in more patients of scleral fixation [17] than iris fixation of intraocular lens. We had to refer the patient to vitreoretinal surgeon for further management as the same was not available in our hospital. In one eye we recorded iris atrophy at the site of enclavation. Many studies have shown that iris atrophy is most common in places of enclavation. [3] In the current study we noted some other minor complications

which needed no treatment in follow-up period other than observation only.

CONCLUSION

In aphakic eyes without capsular support, retropupillary iris-claw lens implantation is easy to perform and gives us the good refractive outcome with all the physiological and optical advantages of posterior intraocular lens location at low risk of complication. But one must keep in consideration the choice of patients for iris fixation and should properly follow the inclusion criteria. From our study as well as from other studies we have noted that, retropupillary iris-claw implantation in such patients is safe and effective among all the treatment modalities available at present.

REFERENCES

1. J. G. Worst, "Iris claw lens," American Intra-Ocular Implant Society Journal, vol. 6, no. 2, pp. 166–167, 1980.
2. L. Amar, "Posterior chamber iris claw lens," American Intra- Ocular Implant Society Journal, vol. 6, no. 1, p. 27, 1980.
3. A. Mohr, F. Hengerer, and C. Eckardt, "Retropupillary fixation of the iris claw lens in aphakia. 1 year outcome of a new implantation techniques," *Der Ophthalmologe*, vol. 99, no. 7, pp. 580–583, 2002
4. Myron Yanoff, Jay S. Duker (2009). *Ophthalmology (3rd ed.)*.
5. Binkhorst CD, Power of the prepupillary pseudophakos, *Br J Ophthalmol*, 1972;56: 332–7.
6. Binkhorst CD, Iris-supported artificial pseudophakia. A new development in intraocular artificial lens surgery (iris-clip lens), *Trans Ophthalmol Soc UK*, 1959; 79:569–81; discussion 581–4.
7. Worst JGF, van der Veen G, Los LI, Refractive surgery for high myopia; the Worst-Fechner biconcave iris claw lens, *Doc Ophthalmol*, 1990;75:335–41.
8. Lovisolo CF, Reinstein DZ, Phakic intraocular lenses, *Surv Ophthalmol*, 2005;50:549–87.
9. Rüfer F, Saeger M, Nölle B, et al. Implantation of retropupillar iris claw lenses with and without combined penetrating keratoplasty. *Graefes Arch Clin Exp Ophthalmol*. 2009;247:457–62.
10. Kanellopoulos AJ. Penetrating keratoplasty and artisan iris-fixated intraocular lens implantation in the management of aphakic bullous keratopathy. *Cornea*. 2004;23:220–4.
11. Acar N, Kapran Z, Altan T, Kucuksumer Y, Unver YB, Polat E. Secondary iris claw intraocular lens implantation for the correction of aphakia after pars plana vitrectomy. *Retina*. 2010;30:131–9.
12. Riazi M, Moghimi S, Najmi Z, Ghaffari R. Secondary Artisan-Versys intraocular lens implantation for aphakic correction in post-traumatic vitrectomized eye. *Eye (Lond)*. 2008;22:1419–24.
13. Wolter-Roessler M, Kuchle M. [Correction of aphakia with retroiridally fixated IOL]. *Klin. Monbl. Augenheilkd*. 2008;225:1041–4.
14. Baykara M, Ozcetin H, Yilmaz S, Timucin OB. Posterior iris fixation of the iris-claw intraocular lens implantation through a scleral tunnel incision. *AmJ Ophthalmol*. 2007; 144: 586–91
15. S. R. De Silva, K. Arun, M. Anandan, N. Glover, C. K. Patel, and P. Rosen, "Iris-claw intraocular lenses to correct aphakia in the absence of capsule support," *Journal of Cataract and Refractive Surgery*, vol. 37, no. 9, pp. 1667–1672, 2011.
16. M. Forlini, W. Soliman, A. Bratu, P. Rossini, G. M. Cavallini, and C. Forlini, "Long-term follow-up of retropupillary iris-claw intraocular lens implantation: a retrospective analysis," *BMC Ophthalmology*, vol. 15, article 143, 2015.
17. T. C. Y. Chan, J. K. M. Lam, V. Jhanji, and E. Y. M. Li, "Comparison of outcomes of primary anterior chamber versus secondary scleral-fixated intraocular lens implantation in complicated cataract surgeries," *American Journal of Ophthalmology*, vol. 159, no. 2, pp. 221–226.e2, 2015.

How to cite this article: Kounser S, Ahmad R, Ganaie KA. Retropupillary iris-claw lens implantation in aphakic eyes without capsular support: our five years experience. *International Journal of Research and Review*. 2019; 6(3):202-205.
