

# Incidental Gall Bladder Carcinoma in Routine Cholecystectomy Cases: Need for Histopathology

Tazeen Jeelani<sup>1</sup>, Jibran Amin<sup>2</sup>, Ruby Reshi<sup>3</sup>, Rabiya Rasheed<sup>4</sup>

<sup>1</sup>Lecturer, <sup>2</sup>Senior Resident, <sup>3</sup>Professor and Head, <sup>4</sup>Resident,  
Department of Pathology, Government Medical College Srinagar, J&K, India.

Corresponding Author: Tazeen Jeelani

## ABSTRACT

Gall bladder carcinoma accounts to be the 5th most common cancer of digestive tract. The clinical manifestations of gall bladder carcinoma are generally indistinguishable from those associated with cholecystitis or cholelithiasis. Incidental GBC (IGBC) refers to GBC not suspected before or at operation and not even on gross examination of the GB specimen and is only detected for the first time on histo-pathological examination. Study was conducted in the department of pathology Government medical college Srinagar Jammu and Kashmir and was two year retrospective study. The main aim was to study the frequency of incidental carcinoma of gall bladder in patients undergoing routine cholecystectomy. We found the incidence of IGBC to be 0.5% in our population.

**Key words:** IGBC, Cholecystitis, Cholelithiasis, Gall bladder.

## INTRODUCTION

Gall bladder carcinoma (GBC) is the most common cancer of the biliary tract worldwide <sup>(1)</sup> and accounts to be the 5th most common cancer of digestive tract. <sup>(2)</sup> According to the Indian cancer registry data, incidence of GBC is 0.8%-1%. <sup>(3)</sup> The clinical manifestations of gall bladder carcinoma are generally indistinguishable from those associated with cholecystitis or cholelithiasis. Around 90% of GB (Gall bladder) carcinomas have accompanying stones. <sup>(4)</sup> It is difficult to differentiate early stage of gall bladder carcinoma from chronic cholecystitis as it is mostly asymptomatic. <sup>(5)</sup> Most of the cases of GB carcinoma are diagnosed during or after surgery performed for stones or benign biliary diseases. <sup>(6)</sup>

Incidental GBC (IGBC) refers to GBC not suspected before or at operation and not even on gross examination of the GB specimen and is only detected for the

first time on histo-pathological examination (HPE). Studies in literature have reported IGBC from 0.3% -1.5%. <sup>(7)</sup> IGBC has better prognosis as it is detected on HPE at an early stage and radical cholecystectomy being the standard treatment for IGBC. Hence it has been the standard practice to submit all cholecystectomy specimens to routine HPE to exclude GBC. <sup>(8)</sup> However, few authors are of the opinion that histopathology is not needed for all surgically resected benign gallbladders as the incidence of IGBC is low and many of the cases present at an early stage with simple cholecystectomy being the optimal treatment. <sup>(9)</sup>

The aim was to study the frequency of incidental carcinoma of gall bladder in patients undergoing routine cholecystectomy and to study the demographic profile.

## MATERIALS AND METHODS

Study was conducted in the department of pathology Government medical college Srinagar Jammu and Kashmir India. The archives of department were retrospectively reviewed from October 2016 to September 2018. Total of 6233cholecystectomy cases were received. Both laparoscopic and open cholecystectomy specimens with a clinical diagnosis of benign gallbladder disease were included in the study. Gallbladder wall more than 3 mm was considered to be thickened. Diagnosis of IGBC was confirmed on hematoxylin- and eosin-stained (H&E), formalin-fixed, paraffin-embedded sections.

## RESULTS

Total of 6132 cases were received in the department over a period of 2 years.5521 cholecystectomy specimens without any preoperative suspicion of malignancy were found. The mean age at the time of surgery was 43 years (range 16-74 years). There were 1656 (29.9%) males and 3865 (70.1%) females with a male: female ratio of 1:2.3. Most common presenting symptom was pain in the right hypochondriac region seen in 90% of the patients followed by nausea and vomiting (6%) and epigastric pain (4%). Chronic calculous cholecystitis was the most frequent disease seen in 4400 patients (79.7%) followed by chronic a calculous cholecystitis in 663 patients (12%). Xanthogranulomatous cholecystitis was seen in 320 (5.8%), while as 55 (1%) cases each of adenomyomatosis and mucocele were identified. Twenty eight cases (0.50%) were diagnosed as IGBC (Table-1).It was noted that out of these28cases of IGBC, 78.6% (22) were female patientsand21.4% (6) were males. Cholelithiasis was present in 80% of the cases. The mean age group of affected patients was 52.65 years. Preoperatively USG abdomen detected increased wall thickness in 10 cases (35.7%). In rest of the cases no intraluminal mass lesion was detected. Gross inspection

of the majority specimens revealed thickening of gallbladder wall in about 53.6% (15/28) cases followed by ulceration of mucosa in three cases (10.7%). Ten cases (35.7%) did not show any preoperative or macroscopic findings suggestive of malignancy. Most of the cases of IGBC (22/28) were associated with gallstones. On microscopic examination, all cases showed features of adenocarcinoma (fig-1), in which tumor cells were arranged in glands and papillae. Tumor cells were round to cuboidal with moderate eosinophilic cytoplasm and a central pleomorphic vesicular nucleus with 1–2 nucleoli. Mitosis including atypical forms was seen. Lymphovascular invasion and perineural infiltration were seen in 12 cases and 3 cases, respectively. Tumor cells were seen infiltrating the lamina propria in 6 cases (pT1a), muscularis propria in 21 cases (pT1b), and peri-muscular connective tissue in remaining 1 case (pT2).

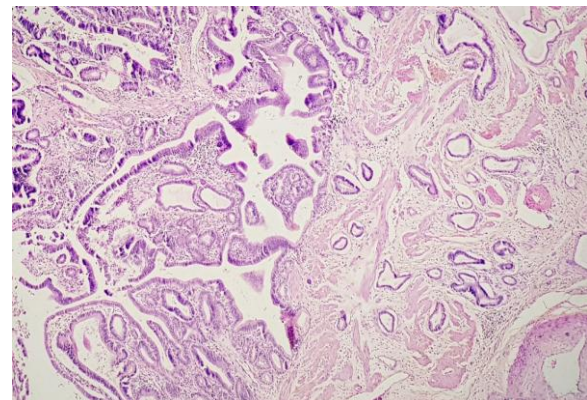


Fig-1: Photomicrograph showing adenocarcinoma of gall bladder with dysplastic glands infiltrating into muscularis propria (pT1b).

Diagnosis	Number of cases (n)	Percentage (%)
Chronic calculous cholecystitis	4400	79.7%
Chronic acalculous cholecystitis	663	12%
Xanthogranulomatous cholecystitis	320	5.8%
Adenomyomatosis	55	1%
Mucocele	55	1%
Incidental gall bladder carcinoma (IGBC)	28	0.5%
Total	5521	100%

## DISCUSSION

Incidental GBCs are defined as carcinomas of gallbladder diagnosed during or after cholecystectomy done for benign

diseases of gallbladder. <sup>(10)</sup> Incidental carcinoma of gallbladder is not an uncommon entity. Nonspecific clinical presentation and diagnostic challenge in early stage for radiologists encompasses difficulty in its preoperative diagnosis. <sup>(11)</sup> The incidence of IGBC is reported to be 0.2%-2.1%. <sup>(10)</sup> In our study, we found IGBC to be 0.5%. It was more common in females and in the elderly age group which was in concordance with the previous studies of literature. <sup>(12)</sup>

Daphna et al <sup>(13)</sup> and Khoo JJ & Nurul AM <sup>(14)</sup> in their studies found the incidence of IGBC to be 0.3% and 0.62% respectively which was comparable to our study. Cholelithiasis is a well-known risk factor for gallbladder cancers. Waghmare and Kamat reported a higher (85%) association of gallstones with IGBC. <sup>(9)</sup> In our study we found that Cholelithiasis was associated with 78.6% of the IGBC cases. However, association of cholelithiasis and gall bladder carcinoma was vary depending upon various factors like ethnic group, race, dietary habits. Gallstones cause mucosal irritation and chronic inflammation setting a stage for the development of dysplasia and subsequently carcinoma. But this transformation requires many years to occur, most cases of GBC are seen in the elderly. <sup>(15)</sup> Various studies in the past have shown that preoperative imaging / gross examination is abnormal in cases of invasive carcinoma and thereby recommending a selective policy rather than a routine histopathological examination of cholecystectomy specimens. <sup>(16)</sup> In our study we found that Preoperatively USG abdomen detected increased wall thickness in only 10 cases, in rest of the cases no intraluminal mass lesion was detected. Gross inspection of the majority specimens revealed thickening of gallbladder wall in about 53.6% cases. Ten cases (35.7%) did not show any preoperative or macroscopic findings suggestive of malignancy. Hence, preoperative USG was not useful in raising a high degree of clinical suspicion of malignancy. As IGBC is known to be early

stage cancers (pT1a and pT1b), many authors propose simple cholecystectomy for the treatment of these lesions. <sup>(17)</sup> In our study also most of the cases were pT1a or pT1b, however we observed one case of pT2. Our study showed the incidence of IGBC to be 0.5% which was in accordance with other studies in literature (Table-2). The Royal College of Pathologists suggests a histo-pathological examination of all cholecystectomy specimens as normal gross morphological features may be misleading at times. <sup>(18)</sup>

**Table-2: List of various studies showing incidence of incidental carcinoma GB.**

Study	Incidence	Number of cases studied
Khoo JJ <i>et al</i> (2005) <sup>(14)</sup>	0.62%	1122
Ghimire P <i>et al</i> (2009) <sup>(19)</sup>	1.28%	783
Kalitaet <i>al</i> (2013) <sup>(20)</sup>	0.44%	4115
Bimal Shah <i>et al</i> (2015) <sup>(5)</sup>	0.87%	803
Our study (2019)	0.5%	5521

## CONCLUSION

Gallbladder cancers are one of the common tumors of gastrointestinal tracts and are known to have a poor prognosis. In our study we found the Incidence of IGBC is low (0.5%) and is usually early stage cancers with a better survival rate. Histopathological examination of cholecystectomy specimens is the gold standard for the detection of occult malignancy. Therefore, we strongly recommend histological assessment of all cholecystectomy specimens regardless of the radiological diagnosis or macroscopic findings.

**Conflict of interest:** none

**Funding source:** nil

## REFERENCES

1. Diehl AK. Epidemiology of gallbladder cancer: a synthesis of recent data. *J Natl Cancer Inst.* 1980;65:1209-14.
2. Jemal A, Siegel R, Ward E, Murray T, Smigal C, Thun MJ. Cancer statistics, 2006. *CA Cancer J Clin* 2006; 56:106–130.
3. Jha V, Sharma P, Mandal KA. Incidental gallbladder carcinoma: Utility of histopathological evaluation of routine

- cholecystectomy specimens. South Asian J Cancer 2018;7:21-3.
4. Oddsdottir M, Hunter JG. Gall bladder and the extrahepatic biliary system. In: Brunicaardi FC, Andersen DK, Billiar TR, Dunn DL, Hunter JG, Pollock RE, editors. Schwartz's principle of surgery (8th ed.). New York: McGraw Hill; 2005.1187-1219.
  5. Bimal Shah, SarangDegloorkar. A retrospective audit of gall bladder histopathology following cholecystectomy. IP Journal of Diagnostic Pathology and Oncology, April-June, 2018;3(2):123-126.
  6. Have PC, Simpson KJ, Garden OG. Liver and biliary tract disease. Hasle; C, Chilvers ER, Boon NA, Colledge NR (19th ed.). Churchill Livingstone. 831-88.
  7. Targarona EM, Pons MJ, Viella P, Trias M. Unexpected carcinoma of the gallbladder, a laparoscopic dilemma. SurgEndosc. 1994; 8:211-3.
  8. Bharathi IV, Devi PU, Lakshmi AB. Study of cholecystectomy specimens over a period of one year in tertiary care centre. Int J Res Med Sci 2017;5:916-21.
  9. Waghmare RS, Kamat RN. Incidental gall bladder carcinoma in patients undergoing cholecystectomy: A report of 7 cases. J Assoc Physicians India 2014;62:793-6.
  10. Butte JM, Matsuo K, Gönen M, D'Angelica MI, Waugh E, Allen PJ, et al. Gallbladder cancer: Differences in presentation, surgical treatment, and survival in patients treated at centers in three countries. J Am CollSurg 2011;212:50-61.
  11. Shrestha R, Tiwari M, Ranabhat SK, Aryal G, Rauniyar SK, Shrestha HG. Incidental gallbladder carcinoma: value of routine histological examination of cholecystectomy specimens. Nepal Med Coll J. 2010;12:90-4.
  12. Ahn Y, Park CS, Hwang S, Jang HJ, Choi KM, Lee SG. Incidental gallbladder cancer after routine cholecystectomy: When should we suspect it preoperatively and what are predictors of patient survival? Ann Surg Treat Res 2016;90:131-8.
  13. Daphna W, Mehrdad H, Noa BJ, Sandbanand AH. Incidental finding of gallbladder carcinoma. Israel Med Assoc J 2002; 4: 334-6.
  14. Khoo JJ, Nurul AM. A clinicopathological study of nine cases of gallbladder carcinoma in 1122 cholecystectomies in Johor, Malaysia. Malaysian J Pathol 2008; 30(1):21-6.
  15. Talreja V, Ali A, Khawaja R, Rani K, Samnani SS, Farid FN. Surgically resected gall bladder: Is histopathology needed for all? Surg Res Pract 2016; 2016:9319-147.
  16. Dix FP, Bruce IA, Krypcyzk A, Ravi S. A selective approach to histopathology of the gallbladder is justifiable. Surgeon 2003; 1:233-5.
  17. Rathanaswamy S, Misra S, Kumar V, Chintamani N, Pogal J, Agarwal A, et al. Incidentally detected gallbladder cancer – The controversies and algorithmic approach to management. Indian J Surg 2012;74: 248-54.
  18. Royal College of Pathologists. Histopathology and Cytopathology of Limited or No Clinical Value, in Report of Working Group of the Royal College of Pathologists. 2nd ed. London, UK: Royal College of Pathologists; 2005.
  19. Ghimire P, Yogi N, Shrestha BB. Incidence of incidental carcinoma gall bladder in cases of routine cholecystectomy. Kathmandu Univ Med J 2011;34(2)3-6.
  20. Kalita D, Pant L, Singh S, Jain G, Kudesia M, Gupta K, et al. Impact of routine histopathological examination of gall bladder specimens on early detection of malignancy- a study of 4115 cholecystectomy specimens. Asian Pacific J Cancer Prev 2013;14:3315-18.

How to cite this article: Jeelani T, Amin J, Reshi R et.al. Incidental gall bladder carcinoma in routine cholecystectomy cases: need for histopathology. International Journal of Research and Review. 2019; 6(3):12-15.

\*\*\*\*\*