

Case Report

Cervical Paramedian Epidermoid Cyst: A Rare Case Report

Dr. C.R. Bande¹, Dr. Anagha Assissi², Dr. Akashay Mishra³, Dr. Ankita Bhagat²

¹Professor and Guide, ²PG Student, ³Reader,
Department of Oral and Maxillofacial Surgery, Swargiya Dadasaheb Kalmegh Smruti Dental, College and Hospital, Nagpur

Corresponding Author: Dr. C.R. Bande

ABSTRACT

Epidermoid cysts are benign epithelial cysts whose occurrence in the neck region is rare. It is generally accepted that traumatic implantation of epithelial cells in the surface epithelium leads to formation of these cysts. Unlike dermoid cysts, they do not contain adnexal structures like sebaceous glands pilose follicles and sweat glands. They can be congenital or acquire, with the latter being either post traumatic or iatrogenic. They show slight male predilection. These most commonly diagnosed in the third and fourth decade of life. The case of a 31-year-old man with a cystic lesion in the paramedian region on the left side of anterior triangle of neck is reported. The Ultra Sonographic evaluation revealed a cystic lesion in the region. The cyst was excised and was confirmed histopathologically as epidermoid cyst. Clinical progress was uneventful and post-operative recovery was excellent without recurrence.

Key words: Cervical paramedian epidermoid cyst, neck swelling

INTRODUCTION

Epidermoid cysts are lined with stratified squamous epithelium without presence of skin, sweat glands etc. [1] Traumatic implantation of epithelium into surface epithelium results in the formation of these cysts. [2] They manifest in the 3rd or 4th decade of life, more often in men than in women. [3] Epithelial lining consists of several layers which are probably dictated by the pressure of its contents. The combined incidence of epidermoid and dermoid cyst is about 7%, which is less than 0.01% of all oral cavity cysts. [4] The common modality of treatment is enucleation. Recurrence is very rare. [5] Rarely, these may transform into Squamous cell carcinoma. [6]

CASE REPORT

A 31-year-old patient reported to our Institution with a 2 years old swelling on the left side of neck. The lesion was initially

diagnosed as lymphadenitis when he first sought for treatment a year ago. The swelling was initially small and gradually attained the present size. When the patient reported to us, he was afebrile. There was a visible swelling in the paramedian region in the anterior triangle of neck (fig 1). The swelling was non-tender, firm in consistency and freely mobile from underlying tissues. Clinically there was no odontogenic source of infection which was confirmed radiographically

The patient was hospitalised and placed on intra-venous fluids and antibiotics. A USG of the patient revealed a the paramedian region of upper neck measuring about 19mm× 12 mm in size. The cyst was not related to submandibular gland and did not show presence of calcification or solid vascular component.

Excision of the cyst was done through curvilinear incision placed 1 cm below the cystic swelling. Blunt dissection

was done to explore the cystic lining followed by enucleation of the cyst. Thorough debridement was done (fig 2 and 3). The wound was closed in layers.

The H & E stained sections showed epithelium and connective tissue arranged in a cystic configuration (fig 4). The cystic lumen was filled with abundant orthokeratin. The epithelial lining was orthokeratinised stratified squamous type only few layers thick and with a flat interface with the underlying connective tissue. The connective tissue stroma was made of mature collagen fibre bundles which were superficially arranged parallel to the epithelial lining and appeared irregular in deeper parts. The diagnosis was paramedian epidermoid cyst. The patient was well post operatively and was placed on yearly follow ups.

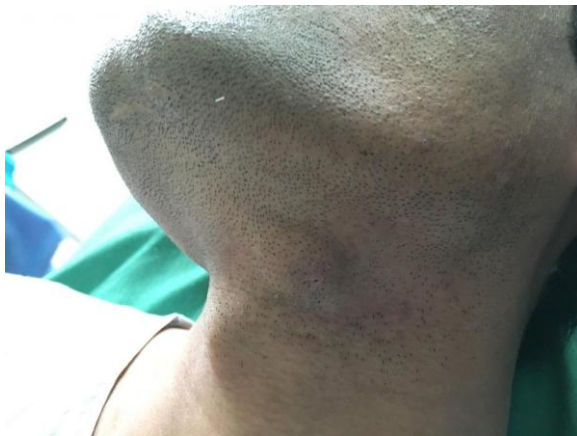

Figure 1. Swelling in Paramedian region of neck

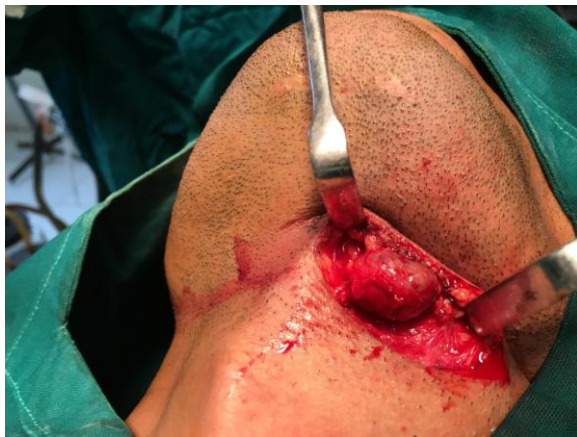

Figure 2. Exposed cyst.

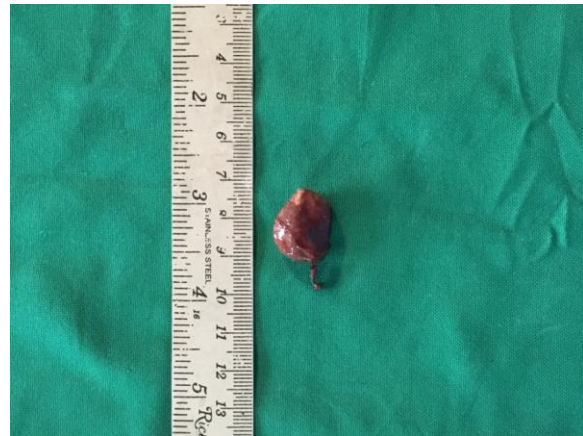

Figure 3. Excised specimen of cyst

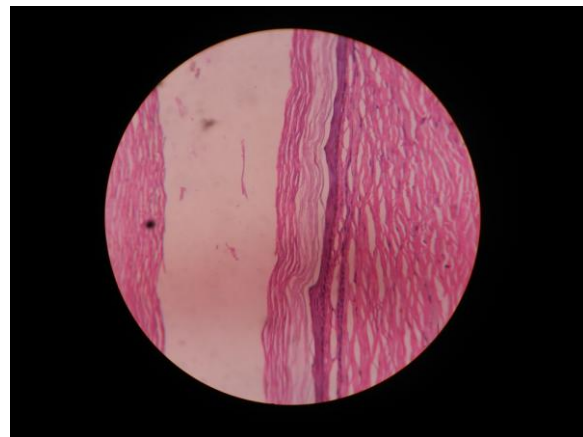


Figure 4. Histopathological picture of cyst

DISCUSSION

Epidermoid cysts constitute 1.6% to 6.9% of all cyst in the head and neck region. They commonly occur at the site of embryonic closure. [7] In our case the cyst was present in the lateral (paramedian) region of neck, which is an uncommon site for presentation of the lesion. In precise histologic considerations, occurrence of epidermoid cyst in lateral location in the neck is extremely rare. [2]

In our case, initially it was misdiagnosed as lymphadenitis. In lateral neck, the common lesions are lymphadenitis, cystic hygromas, branchial cyst, bronchogenic cyst, laryngocele etc. [8] Since these lesions are clinically similar, they pose the risk of diagnostic dilemma and may complicate management protocol.

The cyst arises due to invagination of surface ectoderm along lines of derma fusion. [2] They are lined by epidermis without adnexal structures. If adnexa are

present, it is termed as dermoid cyst. When derived from all the three germ layers, then it is termed as teratoma or teratoid cyst. [9] Often dermoid cyst is used to denote both epidermoid and dermoid cyst.

They usually present as slow growing lesion which is painless. The lesion may appear at any stage of life, and hence the right time for operation is when they manifest with signs and symptoms. It is often soft and well encapsulated with doughy consistency without associated lymphadenopathy. [4] The contents of the cyst are often keratinous, which in our case was confirmed by FNAC. In our case FNAC and USG played an important role in final diagnosis as they defined the dimensions and histopathologic parameters of the lesion.

CONCLUSION

Epidermoid cysts are pathologic entities that occur rarely in the lateral neck. They have unusual and misleading presentation that increases the diagnostic dilemma manifolds. Hence a margin of suspicion should always be kept and ought to be considered in the differential diagnosis.

Informed Consent: Informed consent was obtained from the patient as standard protocol.

Conflict Of Interest: Authors have declared that there is no conflict of interest.

Role of Funding Source: No role of any funding source was involved in this study.

REFERENCES

1. Dutta M, Saha J, Biswas G, Chattopadhyay S. Epidermoid Cysts in Head and Neck: Our Experiences, with Review of Literature. *Indian J Otolaryngol Head Neck Surg.* 2013;65(1):14-21
2. Kandogan T, Koç M, Vardar E, Selek E, Sezgin Ö. Sublingual epidermoid cyst: a case report. *J Med Case Rep* 2007;1:87.
3. Yilmaz I, Yilmazer C, Yavuz H, Bal N, Ozlouglu LN. Giant sublingual epidermoid cyst: a report of two cases. *J LaryngolOtol*2006 Mar;120(3):E19.
4. Mittal MK, Malik A, Sureka B, Thukral BB. Cystic masses of neck: A pictorial review. *Indian J Radiol Imaging* 2012;22(4):334-343.
5. Pradeep PV, Matta R. An Unusual Dermoid Cyst of the Neck presenting as Mass in the Lateral Neck. *World J Endocr Surg* 2012; 4(1):26-28.
6. Seah TE, Sufyan W, Singh B. Case Report Case Report of a Dermoid Cyst at the Floor of the Mouth. *Anna Acad Med Singapore* 2004;33(4):77S-79S.
7. Meyer I. Dermoid cysts (Dermoids) of floor of mouth. *Oral Surg Oral Med Oral Path* 1955; 8(11):1149-1164.
8. Smirnotopoulos JG, Cheichi MV. Teratomas, Dermoids and Epidermoids of head and neck. *Radiographics.* 1995;15: 1437-55.
9. Kenyon GS, Khayat MA-. Midline sublingual dermoid cyst. *J Otol Laryngol* 1990; 104:578-80.

How to cite this article: Bande CR, Assissi A, Mishra A et.al. Cervical paramedian epidermoid cyst: a rare case report. *International Journal of Research and Review.* 2019; 6(3):171-173.
