

Case Report

# Mucinous Cystadenoma Coexisting With Adult Granulosa Cell Tumour: A Very Rare Collision Tumor of Ovary

Dr Byna Syam Sundara Rao<sup>1\*</sup>, Dr Vissa Shanthi<sup>1\*</sup>, Dr Nandam Mohan Rao<sup>1\*</sup>,  
Dr Bhavana Grandhi<sup>2\*</sup>, Dr Vijayalakshmi Muramreddy<sup>\*</sup>

<sup>1</sup>Professor, <sup>2</sup>Associate Professor,

\*Department of Pathology, Narayana Medical College, Nellore (A.P), India

Corresponding Author: Dr Byna Syam Sundara Rao

## ABSTRACT

Collision tumours consist of two histological different tumours in the same organ without intermixture of two cell types. Collision tumours of ovary are quite rare lesion. Coexistence of a mucinous cystadenoma with adult granulosa cell tumour is infrequently reported. Mucinous tumour occurs rarely in association with adult granulosa cell tumour. Here we present a rare case of dual tumour consisting of mucinous cystadenoma in association with granulosa cell tumour in a 41 year old woman who presented with lower abdomen pain and abdominal distension.

**Key Words:** Collision tumour, Ovary, Mucinous cystadenoma, Adult granulosa cell tumour.

## INTRODUCTION

Adult granulosa cell tumour account 1 to 2% of all ovarian tumours and account for 95% of all granulosa cell tumour. <sup>(1)</sup> Ovarian mucinous cystadenoma is a benign multilocular cyst with smooth outer and inner surface. Of all ovarian tumours, mucinous tumours accounts for 15%. About 80% of mucinous tumours are benign, 10% are borderline and 10% are malignant. <sup>(2)</sup> Mucinous tumour occurs rarely in association with Sertoli-Leydig cell tumour, cystic teratoma, and granulosa cell tumour. Collision tumour represents a coexistence of two distinct tumours in the same organ without any histopathological intermixing. <sup>(3)</sup> These tumours have been reported in different organs but ovary is rare. There is only one case has been reported with combination of mucinous tumour coexisting with granulosa cell tumour in 39 year old female. <sup>(4)</sup> Here we report a rare 2<sup>nd</sup> case of collision tumour consisting of mucinous

cystadenoma in association with granulosa cell tumour in 41 year old female.

## CASE REPORT

A 41 year old female presented with complaints of pain abdomen and abdominal distension over a period of 3 months. On routine physical examination no abnormality was detected. Basic haematological investigations, liver function tests and renal function tests were normal. Ultrasound examination revealed probability of serous cystadenoma or mucinous cystadenoma. Patient had history of Hypertension. Clinical diagnosis was serous cyst adenoma of left ovary with hypertension. Patient had underwent left ovarian cystectomy and left salpingectomy. The specimen was sent to department of pathology for histopathological examination. Macroscopic examination showed ovarian cystic mass measuring 23x21x7 cms with attached fallopian tube

measuring 2 cm length. External surface was grey brown to white. Cut surface revealed multiloculated cyst, filled with mucinous material. Papillary excrescences and focal solid area measuring 1.5x1x0.5cm (Fig-1).

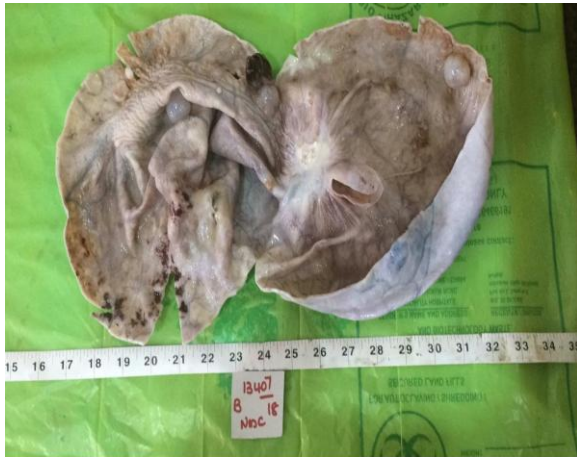

Fig.1. Gross Photograph shows cut section of ovarian cyst with smooth inner surface and focal solid area.

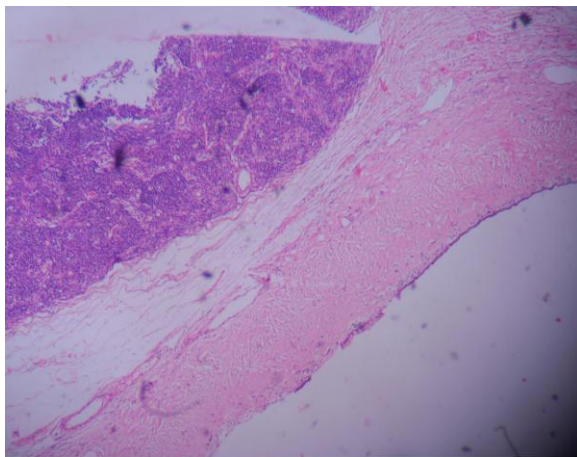


Fig.2. Microscopic examination(H&E)(10X) shows cyst wall lined by nonciliated mucin secreting columnar epithelium and subepithelial fibrocollagenous tissue shows adult granulosa cell tumor.

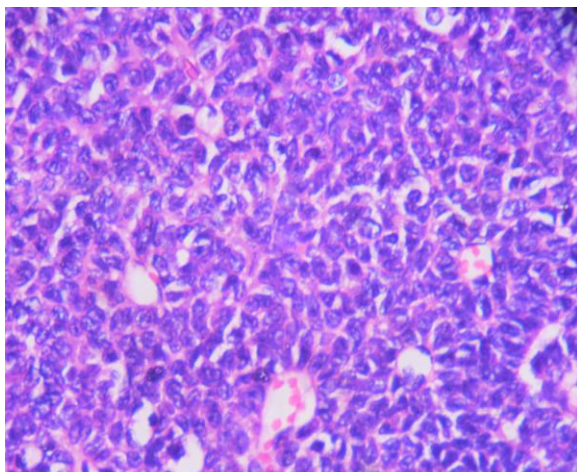


Fig.3. Microscopic examination (H&E)(40X) SHOWS Round to oval tumor cells with eosinophilic cytoplasm and prominent nuclear grooves. Focal call exner bodies noted.

Microscopic examination revealed cyst wall lined by columnar epithelium basally placed nucleus and apical mucin vacuole. Sub epithelium shows fibrous collagenous tissue, congested blood vessels and chronic inflammatory cells. Within the fibro collagenous tissue, there is a well demarcated lesion noted consisting of tumour tissue (Fig-2). Tumour tissue showing tumour cells arranged in microfollicular pattern, cords, trabecular and sheets. Tumour cells are round to oval with eosinophilic cytoplasm and pale nucleus showing nuclear grooves (Fig -3) Focal Call-Exner bodies are noted. Tumour cells are separated by vascular stroma. Fallopian tube showed normal morphology on the basis of microscopic findings. A diagnosis of mucinous cystadenoma with adult granulosa cell tumour was made based on histopathological examination.

## DICUSSION

Surface epithelial and stromal tumours are the commonest of ovarian tumour. Sex cord-stromal tumours are less common. Surface epithelial and stromal tumours account for approximately 60% of all ovarian tumours while sex cord stromal tumours account for approximately 8% of all ovarian tumours. (5) The more combinations of ovarian tumours encountered are with mucinous cystadenoma with combination of mature cystic teratoma, Brenner tumour, Sertoli-Leydig cell tumour or serous cystadenoma. (6) Mucinous tumours can be classified in to 3 main categories of benign, border line and malignant. In Mucinous cystadenoma, multilocular cysts have been reported in 76% and unilocular in 24%. (7) On gross examination, mucinous tumours, characterised by cysts of variable sizes without surface invasions. Microscopically mucinous cystadenoma is lined by columnar non ciliated epithelial cells with apical mucinous vacuole and basal nuclei. Adult granulosa cell tumours are usually unilateral, solid, yellow tan to grey tan color with cystic areas. Microscopically shows

tumour cells arranged in trabecular, microfollicular pattern and insular pattern. Cells having round to oval nuclei with longitudinal nuclear grooves and abundant eosinophilic cytoplasm. Focal Call-Exner bodies are noted. They mostly occur in post menopausal than premenopausal women. Combination of mucinous cystadenoma and adult granulosa cell tumour in ovary very rarely reported in literature. <sup>(4)</sup>

Collision tumour is existence of two distinct tumours in the same organ without any histopathological intermixing. <sup>(3)</sup> Dual tumour have been described not only in the ovary but also other tissues of such as lung, liver stomach, brain, kidneys, and, esophagus. <sup>(4)</sup> Collision tumour in the ovary is a rare lesion and combination of mucinous cystadenoma and granulosa cell tumour is very rare in the literature. Various combinations have been reported in the literature such as combinations of dermoid cyst, cystadenoma mucinous cystadenoma and teratoma, <sup>(7)</sup> serous carcinoma and sarcoma and Sertoli-Leydig cell tumour and serous cystadenoma and <sup>(8)</sup> each component of collision tumours occur coincidentally with no connection. The biological behaviour depends on their own tumour features. The most common histological combination collision tumour in the ovary is the coexistence of teratoma with mucinous tumour. <sup>(9)</sup>

The pathogenesis of collision tumour is not well understood but various hypotheses have been suggested regarding formation of collision tumours. The first hypothesis is that the coexistence of two tumours in the same tissue is due to a “chance accidental meeting”. The second hypothesis proposed is that the presence of the first tumour creates changes in the microenvironment, engendering the development of the second primary tumour or the seeding of metastatic tumor cells. The third theory proposes that each primary tumour has its origin in a common stem cell. <sup>(10)</sup>

Collision tumours are mostly unilateral and can vary in size from 2 to

200cm and predominantly affected in the age group of 17-66 years. Most of them are diagnosed postoperatively after microscopic examination. A clear diagnosis of collision tumour can be made when normal tissue intervenes between both tumours and there is no histological admixture at the interface.

## CONCLUSION

We are reporting this case for creating awareness and recognition among pathologist about the occurrence of their rare collision tumour with combination of mucinous cyst adenoma and adult granulosa cell tumour. Extensive gross and microscopic examination can be helpful in diagnosis of rare collision tumour, So that misdiagnosis and mismanagement can be avoided.

## REFERENCES

1. Young RH, Scully RE: Sex cord-stromal, steroid cell, and other ovarian tumours and paraneoplastic manifestations. Blaustein's pathology of the female Genital tract. 5 edition. New Delhi: Springer-Verlag; 2002,907-917.
2. Mittal S, Gupta N, Sharma A, Dadhwal V: Laparoscopic management of a large recurrent benign mucinous cystadenoma of the ovary. Arch Gyencol Obstet 2008, 277(4):379-380.
3. Bige O, Demix A, Koyunucoglu M, al. Collosion tumour. Serous cystadenocarcinoma and dermoid cyst in the same ovary. Arch gynecal obstet. 2009; 279: 767-70.
4. Rooplata, Yerram Seti, Anantha Lakshmi: A rare dual ovarian tumour mucinous cystadenoma with adult granulosa cell tumour. Journal of dental and medical sciences: 2014; 13(12): 72-73.
5. Young, R.H.(2011) Blaustein's pathology of the female genital tract. In: Kurman R.J Hedrick Ellenson.L and Ronnett, B.M., Eds., 6<sup>th</sup> Edition, Springer, New York, 786.
6. Fox, H. And wells, M.(2003) surface epithelial stromal tumours of the ovary. In: Fox, H and wells, M., EDS., Haines& Taylor obstetrical and Gynaecological Pathology, Vol.1 Churchill Livingstone, Madrid.

7. Tavassoli FA, Devilee p(2003). World health organization classification of tumours pathology and genetics of tumour of the breast and female genital organs. Lyon: IARC Press: 163-171.
8. Seo EJ, Kwon HJ, Shim SI. Ovarian serous cystadenoma associated with sertoli leydig cell tumour- a case report. J Korean med sci. 1996; 11(1): 84-87.
9. Tang P, Oukkary S, Kahn E(2003) Mature cystic teratoma of the ovary associated with complete colonic wall and mucinous cystadenoma. Ann clin Lab Sci 33(4): 465-470.
10. Brandwein- Gensler M, Wang B(2004) collision tumour of the thyroid: a case report of metastatic liposarcoma plus papillary thyroid carcinoma. Head Neck 26(7): 637-641.

How to cite this article: Rao BSS, Shanthi V, Rao NM et.al. Mucinous cystadenoma coexisting with adult granulosa cell tumour: a very rare collision tumor of ovary. International Journal of Research and Review. 2019; 6(2):199-202.

\*\*\*\*\*