

Case Report

Intramuscular Dendritic Fibromyxolipoma of Thigh - A Rare Case Report

Prerona Roy¹, Reeta Dhar², Hoogar M.B.³, Rakesh Demde⁴, Shilpi Sahu⁵

¹Post Graduate Student, Department of Pathology, MGM Medical College, Navi Mumbai

²Professor, Department of Pathology, MGM Medical College, Navi Mumbai

³Associate Professor, Department of Pathology, MGM Medical College, Navi Mumbai

⁴Lecturer, Department of Pathology, MGM Medical College, Navi Mumbai

⁵Professor and Head, Department of Pathology, MGM Medical College, Navi Mumbai

Corresponding Author: Prerona Roy

ABSTRACT

Dendritic fibromyxolipomas are very rare, benign soft tissue tumours that have only been recently described in literature. The tumour is distinguished by the slender cytoplasmic processes of the spindle cells, prominent vascular pattern and a myxoid and collagenous background along with few vacuolated, mature adipocytes. It is extremely rare for this tumour to occur in the extremities. We report a case of a 68 year old female presenting with a mass over the right thigh since 3 years. Histopathological examination and immunohistochemistry diagnosed the case as a dendritic fibromyxolipoma, a rare and distinct soft tissue tumour with the close differentials of low-grade myxoid liposarcoma, spindle cell lipoma and solitary fibrous tumour. The tumour was completely excised and post-operative period was uneventful.

Key words: soft tissue spindle cell tumour, immunohistochemistry, dendritic fibromyxolipoma thigh

INTRODUCTION

Dendritic fibromyxolipoma (DFML) is a rather recently reported benign soft tissue lesion most commonly of the subcutaneous tissue or muscle fascia. It has been reported mostly in the head and neck region, shoulders, calf, foot or back in adult male patients.^[1] It shares clinicopathological features with other soft tissue lesions like the rare myxoid variant of spindle cell lipoma (SCL) and solitary fibrous tumour (SFT). It is considered to be a variant of spindle cell lipoma but with the distinctive dendritic processes, myxoid change and a prominent vascular pattern.^[2] These tumours are typically positive for CD34, Bcl-2 and Vimentin.^[3] We report an extremely rare case of a 68-year-old female patient with a mass over the right thigh that

was diagnosed as DFML on immunohistochemistry. Very few cases of DFML have been reported in literature. To the best of our knowledge, this is the second case of a DFML reported in the right thigh.

CASE REPORT

A 68-year-old female patient presented with a painless slow-growing mass over the antero-lateral aspect of the right thigh over a period of 3 years. There was no history of pain and increase in size. The patient had no history of similar swelling or any relevant medical or surgical history. Physical examination revealed a single, non-mobile, soft to firm, non-tender subcutaneous swelling over the right thigh. The mass was completely excised and sent for histopathological examination.

On gross examination the mass measured 9x6x4cm and was well-encapsulated with a glistening, smooth, grey-white external surface. The cut surface

was grey-white and yellowish in colour with a myxoid appearance. Few areas of haemorrhage were seen (Figure 1).

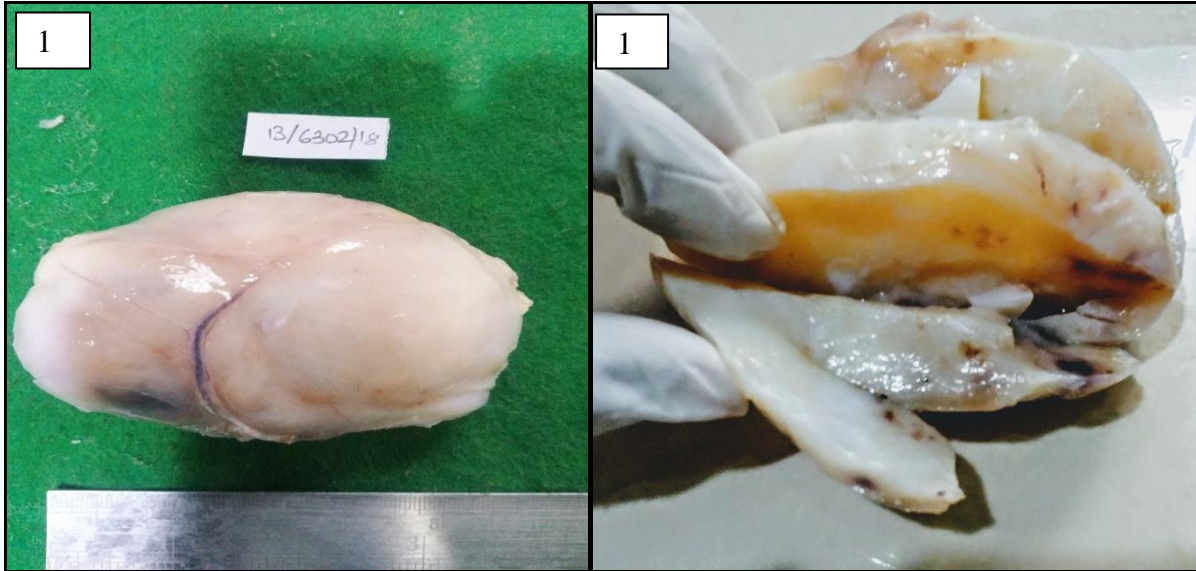


Figure 1A: External surface of the tumour is well-encapsulated, lobulated and glistening.

Figure 1B: Cut surface shows firm grey-white and muroid areas with few brownish areas of haemorrhage.

Microscopic examination of the sections revealed mostly hypocellular tumour with focal cellular areas, containing an admixture of myxomatous, adipomatous, fibrocollagenous and fibrovascular elements in varying proportions. Fatty component showed mature adipocytes both scattered and in clusters. The main component was a proliferation of spindle cells which were uniform, bland-looking and stellate-shaped

with small round to oval nuclei and scant cytoplasm. Higher magnification revealed fine cytoplasmic dendritic processes. The cells were seen on a background of abundant myxoid stroma and roopy collagen. Plexiform blood vessels and diffuse infiltration by mast cells was also seen. No mitotic activity, necrosis or giant cells were identified (Figures 2A and 2B).

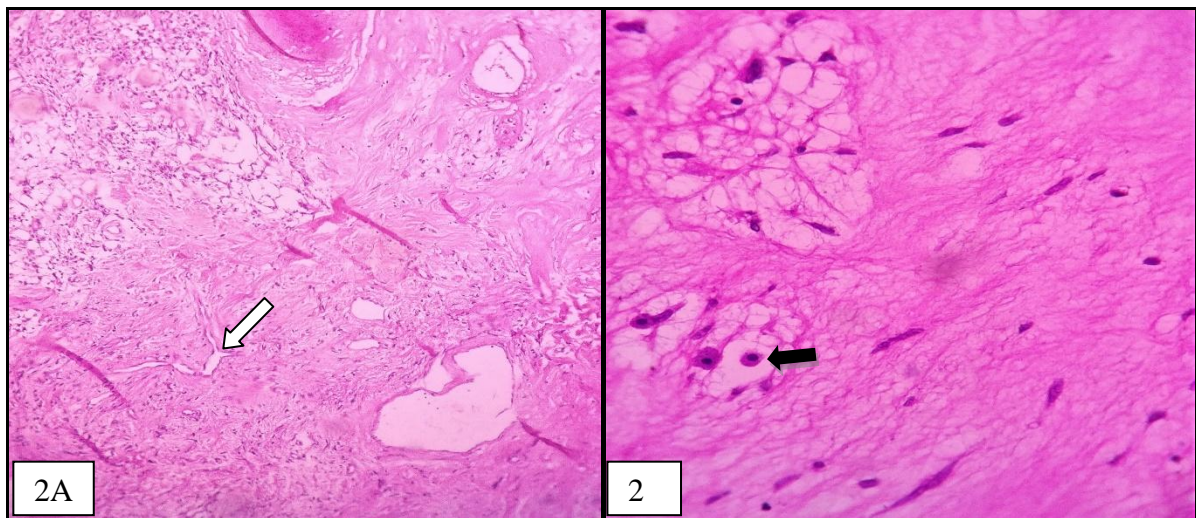


Figure 2A: Low power view showing hypocellular and cellular areas with spindly and stellate cells against a myxoid background along with mature adipocytes, plexiform blood vessels (white arrow) and roopy collagen. **Figure 2B:** High power view showing mature adipocytes, mast cells (black arrow) and stellate cells with drawn-out cytoplasmic processes on a myxoid background.

The dendritic processes of the stellate-shaped cells were strongly highlighted by CD34 and Vimentin (Figures 3A and 3B). Bcl-2 was strongly positive in the mast cells and the stellate cells (Figure 4A). S-100 was negative (Figure 4B). Toluidine blue stain also highlighted the mast cells (Figure 5). A final histopathological diagnosis of dendritic fibromyxolipoma was made.

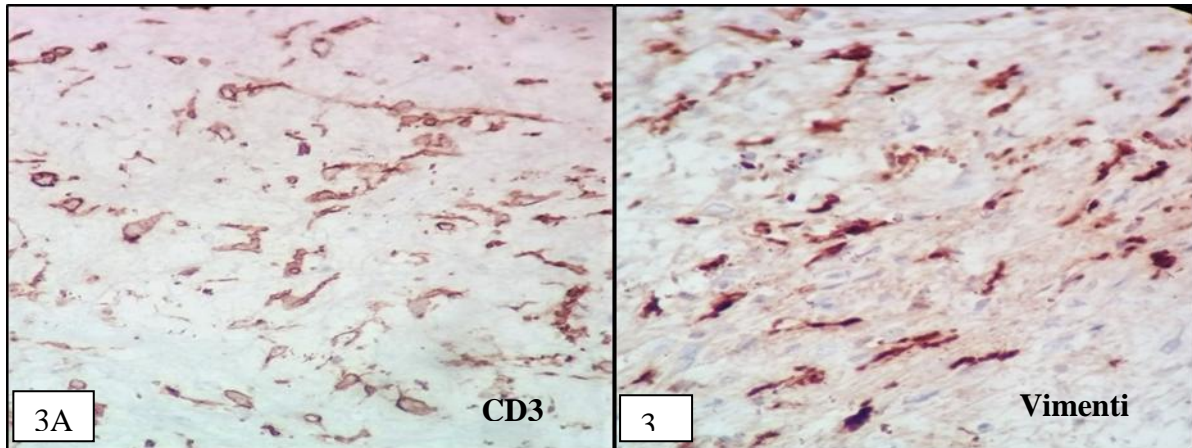


Figure 3A: Shows positivity of CD34 in the spindle and stellate cells with cytoplasmic processes. Figure 3B: Strong positivity of the spindle and stellate cells for Vimentin.

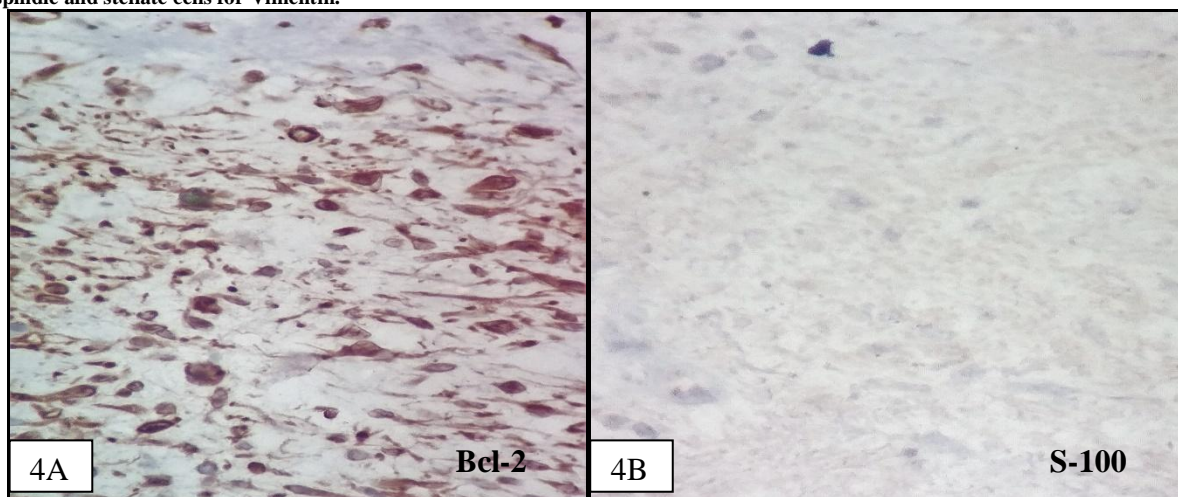


Figure 4A: Strong immunoreactivity for Bcl-2. Figure 4B: Negativity for S-100.

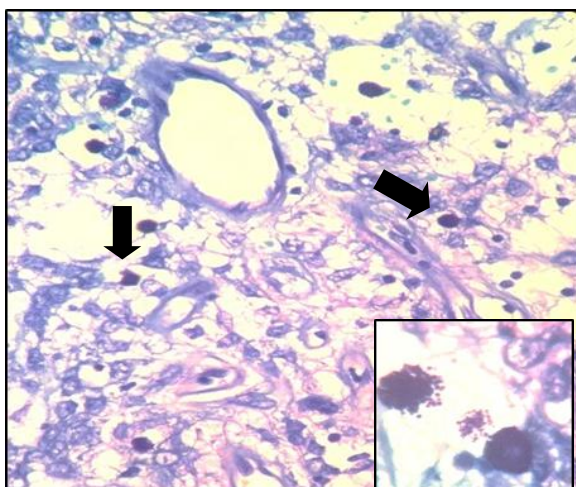


Figure 5: Toluidine blue stain shows mast cells (black arrows). Inset: Higher magnification (Toluidine blue x100) showing granules of mast cells.

DISCUSSION

DFML is a very rare and benign tumour of the soft tissue and was initially reported in 1998 by Suster et al. It has mostly been reported in adult males in the shoulder, neck, face and upper back. It is typically slow-growing and very well-circumscribed. Microscopically, the typical picture shows bland spindle cells on a background of abundant myxoid stroma, anastomosing blood vessels, ropy collagen bundles and mast cells. The dendritic processes of the stellate-shaped spindle cells have been confirmed on electron microscopy [2] and are best demonstrated by strong positivity for CD34 and Vimentin. [4]

The stellate cells are negative for S-100 stain, which is typical for DFML. [5] CD99 has also been reported positive in one case. [6] Karim et al also reported chondroid metaplasia in their case, the only known report so far. [2]

The histological features may be confused with many benign and malignant soft tissue lesions, such as SFT, SCL and low-grade myxoid liposarcoma (MLS). An important differential diagnosis in our case was MLS as the lesion showed abundant myxoid stroma along with rich network of capillaries, but the absence of mitotic activity and lipoblasts and the fact that the tumour was very well-encapsulated made the diagnosis unlikely. Also, immunohistochemically MLS is positive for S-100 but negative for CD34. [7]

SCL is a very close differential to DFML. The dendritic processes, plexiform capillary arrangement and abundance of short, thick, ropy collagen bundles are said to be the key differentiating features between the two lesions. [2] Another confusing differential is SFT. However, it is mostly seen arising in the thoracic cavity and has a characteristic 'patternless pattern' of bland spindle cells. The most important differentiating features from DFML are a 'haemangiopericytoma-like' pattern of blood vessels and absence of an adipose tissue component. [8]

Some other differentials include lipoblastoma, nodular fasciitis, low-grade myxofibrosarcoma and vascular myxolipomas. Lipoblastoma almost always occurs in infants which is not the case with DFML. The absence of lipoblasts is also a differentiating feature. Nodular fasciitis may have a spindle cells on a myxoid background with marked inflammation, but they are poorly encapsulated and are negative for CD34. [4] Myxofibrosarcomas show marked pleomorphism and mitotic activity as opposed to the bland nature of DFML. The vessels are curvilinear and not plexiform as is seen in DFML. Vascular myxolipomas have numerous vessels on a background of myxoid stroma and

adipocytes, but lack the collagenous and spindle cell component of DFML. [2]

CONCLUSION

DFML is a rare benign soft tissue lesion that has an uncertain origin and histologic nature, and is thought to be an intermediate tumour between SCL and SFT. [9] In this article, to our knowledge, we report the second case of DFML in the thigh and the first in a female occurring in the same region. It is necessary for clinicians and pathologists to be aware of this newer entity as it could be misdiagnosed as other benign as well as malignant soft tissue neoplasms. Careful histopathological and immunohistochemical evaluation, along with clinical features and gross examination would help towards diagnosis. It is hoped that this article would contribute to the existing literature on this recently reported unique entity.

ACKNOWLEDGEMENTS

We thank the Department of Surgery, MGM Medical College, Navi Mumbai for their help in providing the patient history and surgical specimen. Technical assistance from the immunohistochemical section is also gratefully appreciated.

REFERENCES

1. Han X, Zheng L, Shang X. Dendritic fibromyxolipoma on the nasal tip in an old patient. *Int J ClinExpPathol.* 2014; 7(10):7064-7067.
2. Karim R, McCarthy S, Palmer A, Bonar S, Scolyer R. Intramuscular dendritic fibromyxolipoma: Myxoid variant of spindle cell lipoma?. *Pathology International.* 2003;53(4):252-258.
3. Sun F, Wang S, Liu F et al. Intramuscular dendritic fibromyxolipoma of the right thigh region: a case report and review of the literature. *Int J ClinExp Med.* 2018; 11(5):5281-5285.
4. AlAbdulsalam A, Arafah M. Dendritic Fibromyxolipoma of the Pyriform Sinus: A Case Report and Review of the Literature. *Case Reports in Pathology.* 2016;2016:1-4.
5. Al-Maskery A, Al-Sidairy S, Al-Hamadani A. Dendritic Myxofibrolipoma: Often Misdiagnosed as Sarcoma.

- Craniomaxillofacial Trauma and Reconstruction. 2011;4(3):171-174.
6. Dahlin L, Ljungberg O. Dendritic fibromyxolipoma adherent to the median nerve in the forearm. *Journal of Plastic Surgery and Hand Surgery*. 2012;46(2):120-123.
 7. Liu S, Wang X, Lei B et al. Dendritic fibromyxolipoma in the latissimusdorsi: a case report and review of the literature. *Int J ClinExpPathol*. 2015;8(7):8650-8654.
 8. Zhang XJ, Zhou S, Nie K et al. Dendritic fibromyxolipoma in the right inguinal and perineum regions: a case report and review of the literature. *Diagnostic Pathology*. 2013;8(1):157.
 9. Kim SN, Kwon KH, Suh Y. Dendritic Fibromyxolipoma – A Case Report. *The Korean Journal of Pathology*. 2001;35:441-50.

How to cite this article: Roy P, Dhar R, Hoogar MB et.al. Intramuscular dendritic fibromyxolipoma of thigh - a rare case report. *International Journal of Research and Review*. 2019; 6(1):14-18.
