

Original Research Article

# A Prospective Observational Study of Clinical, Functional and Radiological Assessment of Unstable Intertrochanteric Fracture of Femur in Elderly Patients Treated with Proximal Femoral Nail Antirotation Using Harris Hip Score

Dr. Akshay Jain<sup>1</sup>, Dr. Lokesh Gudda Naik<sup>2</sup>, Dr. Pawal Gajendra Prabhakar<sup>1</sup>,  
Dr. Ankit Jain<sup>3</sup>

<sup>1</sup>Senior Registrar, Nanavati Super Specialty Hospital, Mumbai, India.

<sup>2</sup>Associate Consultant, Department of Orthopaedics, Sir HN Reliance Foundation Hospital, Mumbai, India,

<sup>3</sup>Resident, Gandhi Medical College, Bhopal, Madhya Pradesh, India.

Corresponding Author: Dr. Lokesh Gudda Naik

## ABSTRACT

**Background:** The incidence of unstable intertrochanteric fracture in elderly is rising because of increased age and with low bone mineral density. The presence of osteoporosis in intertrochanteric fractures is important because fixation of the proximal fragment depends entirely on the quality of cancellous bone present. The surgical stabilization of unstable intertrochanteric fractures remains a persistent challenge. The purpose of this study is to study the effectiveness and drawbacks of one such newer intramedullary device, Proximal Femoral Nail Antirotation in management of intertrochanteric fractures.

**Patients and method:** After obtaining clearance from hospital ethical board, patients who underwent PFNA for unstable intertrochanteric fractures at a tertiary care center, Mumbai, who have given written and informed consent. Patients fitting into inclusion criteria would form the study group. Sample size was calculated using Post-hoc analysis sample size calculator. Data collected by interviews, observation of clinical and radiological findings and assessment of function done using Harris hip score. Categorical data was analyzed by using Chi-square test and comparison of results done using Paired t test.

**Results:** The study comprised of 40 patients, with a mean age of mean age  $77 \pm 8.93$  years who suffered unstable fracture intertrochanteric femur, due to either trivial fall (82.50%) or RTA (17.50%) and managed by cephalomedullary nailing using Proximal Femoral Nail Antirotation at our centre. Majority of the patients had quality of reduction; Majority of patients took 14 weeks for union with mean union time of 14.2 weeks with standard deviation of  $\pm 1.29$ . Patients were asked to follow up routinely, with post operative follow up ranging from minimum of 20 weeks to 9 months. At final follow up following results obtained according to Harris Hip Score, were- 45% patients Excellent, 32.50% patients-Good, 20% patients- Fair, 2.50% patients-Poor.

**Conclusions:** The intertrochanteric fracture in elderly patients treated with cephalomedullary nailing using proximal femoral nail-antirotation, which has biomechanical advantage of helical blade providing bone compaction, increasing surface area and better anchorage in femoral head, which showed favorable outcome by retarding rotation and varus collapse and prevents medialization by acting as a central pillar.

**Key Words:** Intramedullary; Intertrochanteric fracture; AO & OTA classification; Singh's index; Cephalomedullary Femoral Nail; Proximal femoral nail antirotation; Helical blade; Harris hip score.

**Abbreviations used:** AP: Anteroposterior, AO: Arbeitsgemeinschaft für Osteosynthesefragen, ASIF: Association for the Study of Internal Fixation, OTA: Orthopaedic Trauma Association, PFNA: Proximal Femoral Nail Antirotation, RTA: Road traffic accident, TAD: Tip Apex Distance, Wks: Weeks, Yrs: years.

## INTRODUCTION

The incidence of intertrochanteric fracture is rising because of the increase in

number of elderly population with osteoporosis. These fractures are three to four times more common in women and the

mechanism of injury is usually due to a low-energy trauma like a simple fall. By 2040, the incidence is estimated to be doubled. In India these figures may be much more. [1] More than 50% of intertrochanteric fractures are unstable. Unstable patterns occur more commonly with increased age and with low bone mineral density. The presence of osteoporosis in intertrochanteric fractures is important because fixation of the proximal fragment depends entirely on the quality of cancellous bone present. The surgical stabilization of unstable intertrochanteric fractures remains a persistent challenge. Dissatisfaction with the use of the extramedullary devices like the Dynamic Hip Screw in unstable intertrochanteric fracture patterns has gradually led to the evolution of intramedullary devices. The purpose of this study is to study the effectiveness and drawbacks of one such newer intramedullary device, Proximal Femoral Nail Antirotation in management of intertrochanteric fractures that has biomechanical advantage of helical blade providing bone compaction and better anchorage in femoral head. [2]

## **PATIENTS AND METHODS**

After obtaining clearance from hospital ethical board, patients who underwent PFNA for unstable intertrochanteric fractures at a tertiary care center, Mumbai between April 2016 to May 2017, who have given written and informed consent. Patients with AO type 31A2, 31A3, age more than or equal to 60 years, fit for surgery, willing to participate in study, visit for follow up were included and would form the study group. Patients with AO type 31A1, age below 60 years, unfit for surgery, with associated fracture in the ipsilateral lower limb, compound fractures, pathological fractures, one who not consented for surgery or study, existing neurological deficits and with ongoing chemo or radiotherapy were excluded. Sample size was calculated using Post-hoc analysis sample size calculator. Percentage

decrease and good to excellent results using Harris hip score was taken to calculate the sample size. As per Kumar GN et.al [3] it was 78% and as per Sahin S et.al [4] it was 66.60%. We had to enroll 26 patients with 80% power and 95% significance. Hence a sample size of 26 was chosen for the purpose of study and also included consecutive consented to a total of 40 patients. All patients were assessed as per standard pre operative protocol by clinical examination, necessary blood investigations, X rays of pelvis with hips, lateral view and also traction views wherever necessary. All surgeries performed by standard accepted method by a single senior surgeon and standard post operative protocol was followed for all the patients. All patients were assessed clinically, radiologically (According to Baumgaertner criteria modified by Fogagnolo et al [5]). Alignment Anteroposterior plane: Normal collodiaphysial angle or slight valgus and in Lateral plane: Angulation less than 20° degrees. 2). Displacement of main fragments More than 80% overlapping in both planes and shortening less than 5 mm. Good meets both criteria, acceptable meets only one criterion and Poor does not meet both criteria) and functionally by Harris hip score. Data collected by interviews, observation of clinical and radiological findings and assessment of function done using Harris hip score. Categorical data was analyzed by using Chi-square test and comparison of results done using Paired t test.

## **RESULTS**

The mean age was  $77 \pm 8.93$  years. There was a female predominance. Majority of the patients (pre-operative ambulatory status) were walking without support, 36 out of 40 patients, accounting for 90% of patients. Majority of the patients had trivial fall was the commonest mode of injury, 33 out of 40 patients, accounting for 82.50% of patients. Majority of the patients had AO and OTA classification- Type 31-A2.2

fracture, 12 out of 40 patients, accounting for 30% of patients. Majority of the patients had osteoporotic index (Singh's index) grade 3, 17 out of 40 patients, accounting for 42.50 % of patients. Majority of fractures were reduced by closed means intraoperatively, 36 out of 40 accounting for 90% of cases. In majority of the patients, the duration of surgery was less than 1 hour, 28 out of 40 patients, accounting for 70% of patients. Majority of the patients we used 100 to 150 C-arm shoots, 33 out of 40 patients, accounting for 82.50 % of patients. Majority of the patients had quality of reduction, Good, 27 out of 40 patients, accounting for 67.50% of patients. Majority of the patients (post operative ambulatory status) were, walking without support, 34 out of 40 patients, accounting for 85% of patients. Majority of the patients were walking with normal gait, 37 out of 40 patients, accounting for 92.50% of patients and the rest 03 patients had abductor lurch. Majority of the patients took 14 weeks for union with mean union time of 14.2 weeks with standard deviation of 1.29. Majority of the patient's final outcome according to Harris hip score was excellent, 18 out of 40 patients, accounting for 45% of patients. Only 3 patients had complications in the form of anterior thigh pain and in the same patients we had abductor lurch as well.

### **Harris Hip Score** [15]

#### **1. Pain (44 possible)**

- a) None or ignores it 44 points
- b) Slight, occasional, no compromise in activities 40 points
- c) Mild pains, no effect on average activities, rarely moderate Pain with unusual activity, may take aspirin 30 points
- d) Moderate pain, tolerable but makes concessions to pain some limitation of ordinary activity or work 20 points
- e) Marked pain, serious limitation of activities 10 points
- f) Totally disabled, crippled, pain in bed, bed ridden 0 points

#### **2. Function (47 possible)**

##### **A) Gait (33 possible)**

###### i) Limp

- a) None 11 points
- b) Slight 8 points
- c) Moderate 5 points
- d) Severe 0 points

###### ii) Support

- a) None 11 points
- b) Cane for long walk 7 points
- c) Cane most of the time 5 points
- d) One crutch 3 points
- e) Two canes 2 point
- f) Two crutches 0 point
- g) Not able to walk (Specify reason) 0 point

###### iii) Distance walked

- a) Unlimited 11 points
- b) About 1000 meters 8 points
- c) About 5000 meters 5 points
- d) Indoors only 2 points
- e) Bed and chair 0 point

##### **B) Activities (14 possible points)**

###### i) Stairs (4 maximum)

- Foot over foot without use of banister 4 points
- Foot over foot using banister 2 points
- Stairs in any manner 1 points
- Unable to do stairs 0 point

###### ii) Put on Shoes and socks (4 maximum)

- With ease 4 points
- With difficulty 2 points
- Unable 0 points

###### iii) Sitting

- Comfortably in ordinary chair for one hour 5 points
- On a high chair for half an hour 3 points
- Unable to sit comfortably in any chair 1 point

###### iv) Ability to enter public transportation

- 1 point

###### Absence of deformity (All yes=4;if less than four yes=0)

- less than 30<sup>0</sup> flexion deformity
- less than 10<sup>0</sup> fixed adduction
- less than 10<sup>0</sup> fixed internal rotation in extension
- limb length discrepancy<3.2cm

**Range of Motion**

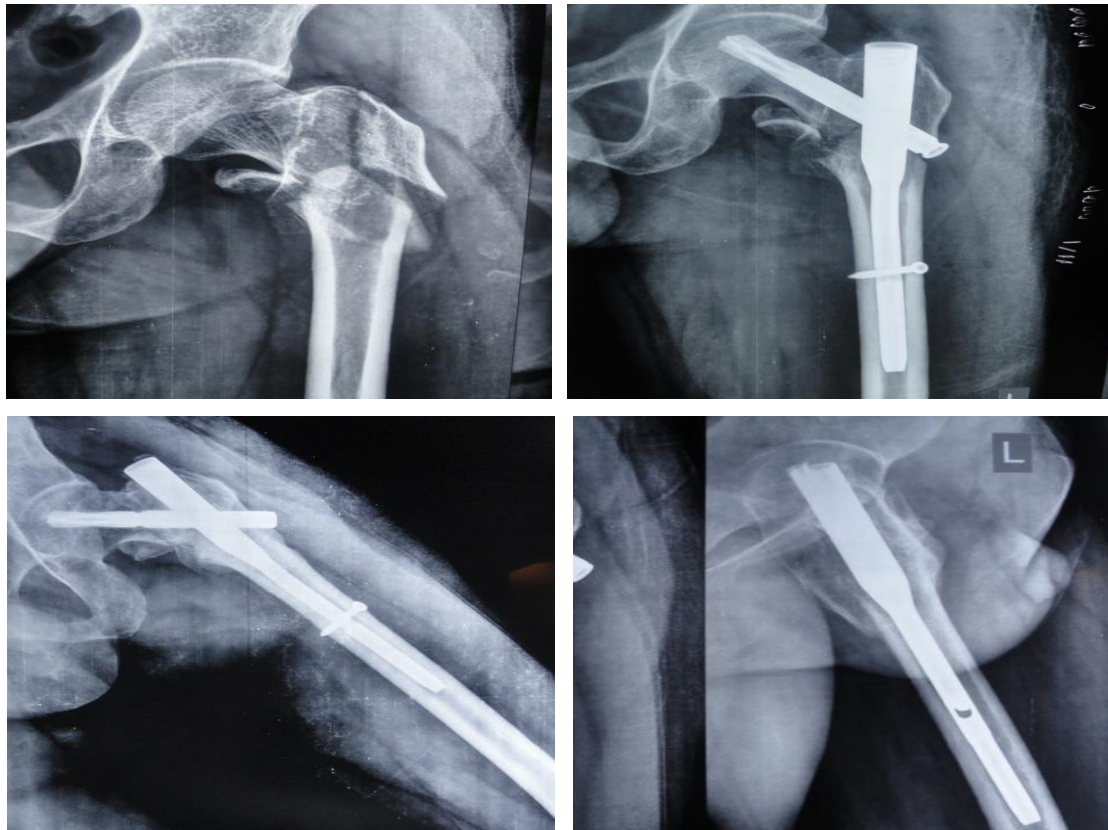
-Flexion 140°  
 -external rotation 40°  
 -internal rotation 40°  
 -Abduction 40°  
 -Adduction 40°

161°-210° 4 points  
 101°-160° 3 points  
 61°-100° 2 points  
 31°-60° 1 points  
 0°-30° 0 point

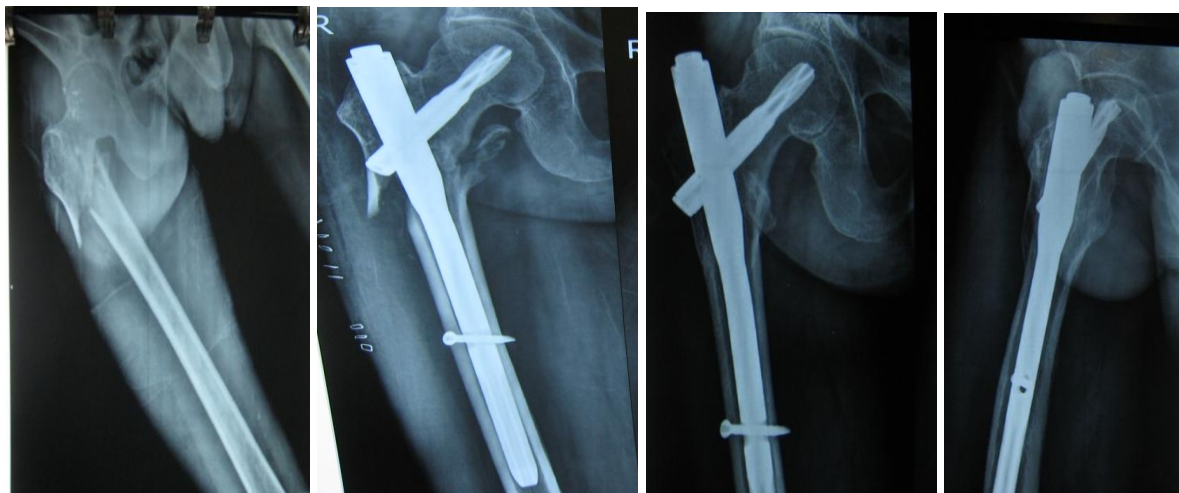
RESULT	SCORE
Excellent	91-100
Good	81-90
Fair	71-80
Poor	≤70

**Range of Motion Score**

211°-300° 5 points



Case 1: Pre op AP view, Post op AP view and at final follow up AP and Lateral view.



Case 2: Pre op AP view, Post op AP view and at final follow up AP and Lateral view.

## DISCUSSION

Stable intertrochanteric fractures are those, in which posteromedial cortex remains intact and calcar femorale is not affected. Unstable intertrochanteric fractures are those, in which comminution of posteromedial buttress exceeds a simple lesser trochanteric fragment, those with subtrochanteric extension or those with reverse oblique fracture patterns.

Surgical management is the preferred treatment for unstable fractures. Successful treatment of intertrochanteric fractures depends on surgeon independent variables like bone quality (osteoporosis), fracture pattern & fracture stability. Surgeon dependent variables like quality of fracture reduction, choice & placement of implant. [6]

In unstable proximal femoral fractures, control of axial telescoping and rotational stability are essential. Intramedullary implants inserted in a less-invasive manner are better tolerated by the elderly. [7]

In the present study, the average age for intertrochanteric fractures was 77 years. P value of 0.001 on comparing with results of other series, found to be statistically significant. Which was higher when compared to Kumar GN et.al (2015)<sup>3</sup> with mean age of 61years and lower when compared to Soucanye E et.al (2012) [8] with mean age of 85 years. Majority of the patients were females and P value is 0.0001 on comparing with results of other series found to be statistically significant. Which was similar to Sadic S et.al (2014) [9] and higher than Kumar GNet.al (2015). [3] Good reduction was achieved in 27(67.50%) patients. Acceptable reduction was achieved in 12(30%) patients and poor reduction in 1 (2.50%) patient. With P value of 0.303 on comparing with results of Sahin S et.al (2010), [4] found to be statistically not significant. Mean tip apex distance was 18.70 mm with standard deviation 3.90 with a P value of 0.008 on comparing with results of other series suggesting statistically significant. It was similar to Sahin S et.al [4]

(2010). Mean duration of surgery was 55.8 minutes with standard deviation of 15.93 with a P value of 0.0001 on comparing with results of other series found to be statistically significant. It was similar to LiM, WuL et.al [10] (2014). Mean duration of radiological union was 14.2 weeks with standard deviation of 1.29 with a P value of 0.04 on comparing with results of other series found statistically significant. It was similar to Lv C, Fang Y et.al [11] (2011).

In our study, we estimated the patient functional outcomes following Cephalomedullary nailing using proximal femoral nail antirotation for unstable intertrochanteric fractures in elderly patients using Harris hip score and we found good and excellent outcome in 31(77.50%). It was similar to Kumar GN [3] et.al (2015). We did not encounter any case of varus collapse and blade cut-out, suggesting a good purchase of helical blade. During insertion of helical blade, it compacts the trabecular bone around it and decreases its susceptibility of yielding to strain. A study done on cadaveric bones by Goffin et.al [12] concludes that bone compaction caused during insertion of helical blade is significantly important in bones with lower density and provides additional mechanical anchorage to the blade and decreases chances of cut outs. There have been other biomechanical studies that conclude the superiority of blade over screws with regard to minimising chances of cut out. [13] Though there have been a few cases reported where cut out or joint perforation has occurred, but most of these seem to have occurred due to improper placement of screw. [14] In our series, majority of the patients had severe osteoporosis, but with correct placement of blade we did not have any case of implant failure. So, our experience suggests that the helical blade, when properly placed, is well suited for osteoporotic patients.

## CONCLUSION

The Intertrochanteric fractures in elderly patients treated with

cephalomedullary nailing with proximal femoral nail antirotation that has biomechanical advantage of helical blade providing bone compaction and better anchorage in femoral head, which retards rotation, varus collapse and prevents medialization by acting as a central pillar. The proper selection of patients, good pre operative planning and careful insertion of PFNA helical blade in a patient with good bone quality or osteoporotic, should be mandatory.

## REFERENCES

1. GS Kulkarni, Rajiv Limaye, Milind Kulkarni, Sunil Kulkarni. Intertrochanteric fractures. Indian journal of orthopaedics 2008, 40:16-23.
2. Evans PJ, McGrory BJ. Fracture of the proximal femur. Hosp Phys 2002; 38:30-8.
3. Kumar GN, Sharma G, Khatri K, Farooque K, Lakhotia D, Sharma V, Meena S. Treatment of Unstable Intertrochanteric Fractures with Proximal Femoral Nail Antirotation II: Our Experience in Indian Patients. Open Orthop J. 2015 Nov 19;9:456-9.
4. Sahin S, Erturer E, Ozturk I, Toker S, Seckin F, Akman S. Radiographic and functional results of osteosynthesis using the proximal femoral nail antirotation (PFNA) in the treatment of unstable intertrochanteric femoral fractures. Acta Orthop Ttraumatol Turc 2010;44(2):127-34.
5. Baumgaertner MR, Curtin SL, Lindskog DM, Keggi JM. The Value of the Tip-Apex Distance in Predicting Failure of Fixation of Peritrochanteric Fractures of the Hip. Journal of Bone and Joint Surgery 1995; 77A: 1058.
6. Kaufer H. Mechanics of the treatment of hip injuries. Clin Orthop. 1980; 146:53-61
7. Baumgaertner MR, Curtin SL, Lindskog DM. Intramedullary versus extramedullary fixation for the treatment of intertrochanteric hip fractures. Clin Orthop Relat Res 1998;348:87-94.
8. Soucanye de Landevoisin E, Bertani A, Candoni P, Charpail C, Demortiere E. Proximal femoral nail antirotation [PFNA-ATM] fixation of extra-capsular proximal femoral fractures in the elderly: Retrospective study in 102 patients. Orthop Traumatol Surg Res [Internet]. Elsevier Masson SAS; 2012;98[3]:288-95.
9. Sadic S, Custovic S, Jasarevic M, Fazlic M, Smajic N, Hrustic A, et.al. Proximal femoral nail antirotation in treatment of fractures of proximal femur. Med Arch.2014;68(3):173-7.
10. MingHui Li, Lei Wu, Yang Liu, CaiMing Wang. Clinical evaluation of Asian proximal femur intramedullary nail antirotation system for treatment of intertrochanteric fractures: J Orthop Surg Rea. 2014;9:112.
11. Lv C, Fang Y, Liu L, Wang G, Yang T, Zhang H, Song Y. The new proximal femoral nail antirotation-Asia: early results. Orthopedics. 2011 May 18;34(5):351.
12. Goffin JM, Pankaj P, Seil R, Gerich TG. Does bone compaction around the helical blade of a proximal femoral nail antirotation [PFNA] decrease the risk of cut-out? 2013;2[5]:79-83.
13. Sommers MB, Roth C, Hall H, Kam BCC, Ehmke LW, Krieg JC, et al. A laboratory model to evaluate cutout resistance of implants for pertrochanteric fracture fixation. J Orthop Trauma. 2004;18[6]:361-8.
14. Stern R, Lübbecke A, Suva D, Miozzari H, Hoffmeyer P. Prospective randomised study comparing screw versus helical blade in the treatment of low-energy trochanteric fractures. Int Orthop. 2011;35[12]:1855-61.
15. Harris WH. Traumatic arthritis of the hip after dislocation and acetabular fractures: treatment by mold arthroplasty. An end result study using a new method of result evaluation. J bone Joint Surg (Am) 1969;51:737-55.

How to cite this article: Jain A, Naik LG, Prabhakar PG. A prospective observational study of clinical, functional and radiological assessment of unstable intertrochanteric fracture of femur in elderly patients treated with proximal femoral nail antirotation using Harris Hip Score. International Journal of Research and Review. 2018; 5(9):81-86.

\*\*\*\*\*