

Case Report

Crystalloids in Cytology Smears of Parotid Lesions: A Diagnostic Challenge

Shanthi Vissa¹, Kande Srinivasulu², Nandam Mohan Rao¹,
Byna Shyam Sundara Rao², Bhavana Grandhi³

¹Professor, ³Associate Professor,
Department of Pathology, Narayana Medical College and Hospital, Nellore, Andhra Pradesh, India.
²Associate Professor, Department of Pathology, Rajiv Gandhi Institute of Medical Sciences, Ongole,
Andhra Pradesh, India

Corresponding Author: Shanthi Vissa

ABSTRACT

Cystic lesions in neck region yield fluid on fine needle aspiration cytology and are frequently reported as non-specific as they lack cellularity. Non cellular structures like crystalloids in the fluid give clue to the diagnosis. We report a case of 43 year old male patient presenting with swelling in the right parotid region at the angle of the mandible which on cytology was diagnosed as retention cyst.

Key words: Crystalloids, Salivary glands, cytology.

INTRODUCTION

Crystalloids may be found in various salivary gland lesions. They are more common in non-neoplastic salivary gland lesions but can be encountered rarely in malignant lesions. Various crystalline structures described in non-neoplastic and neoplastic salivary gland lesions are tyrosine, amylase, oxalate, collagenase and intramural crystalloids.^[1] We present a case of cystic lesions in the parotid gland containing amylase crystalloids.

CASE REPORT

A 43 year old male presented with tender swelling at the angle of the mandible on the right side. There was no history of fever, hearing loss or weight loss. On clinical examination firm tender swelling measuring 2x3cms is present at the right parotid region. Ultrasonography revealed homogeneous hypoechoic lesion in the right parotid gland suggesting benign cystic lesion. Fine needle aspiration was performed and 2ml of clear fluid was

aspirated. After aspiration swelling subsided. Fine needle aspiration smears were prepared and stained with Haematoxylin & Eosin. Smears revealed numerous rhomboid & rectangular shaped crystalloids with parallel sides ([Figure 1](#)). Some of them showed pointed ends. Few foci showed epithelioid cell clusters ([Figure 2](#)) & multinucleated foreign body giant cells ([Figure 3](#)).

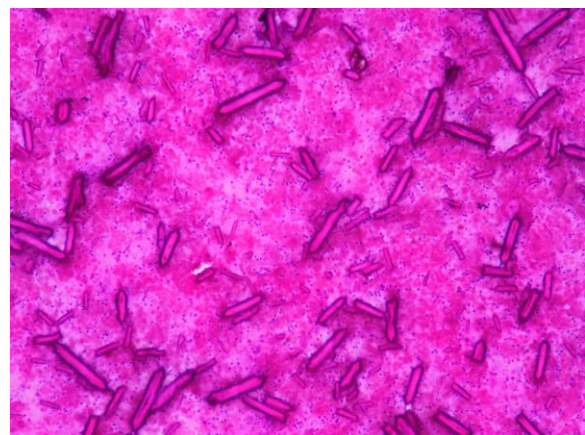

Figure 1: Smears with numerous rectangular shaped crystalloids with parallel sides (H&E, X100)

Foamy macrophages were noted in some foci. Background showed eosinophilic necrotic debris. No acinar or ductal elements were seen. Cytological diagnosis of benign cystic lesion with the possibility of retention cyst of parotid was made.

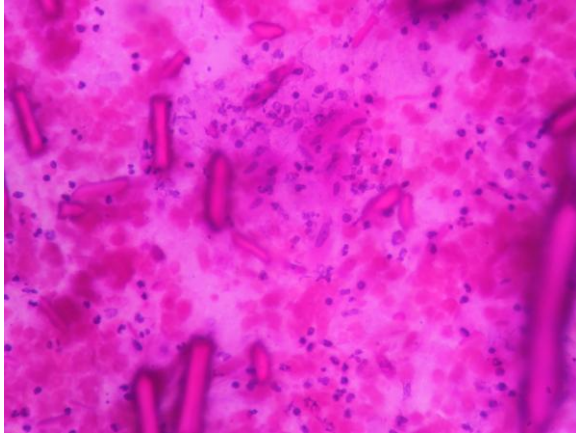

Figure 2: Smears showing crystalloids with adjacent epithelioid cell cluster (H&E,X400)

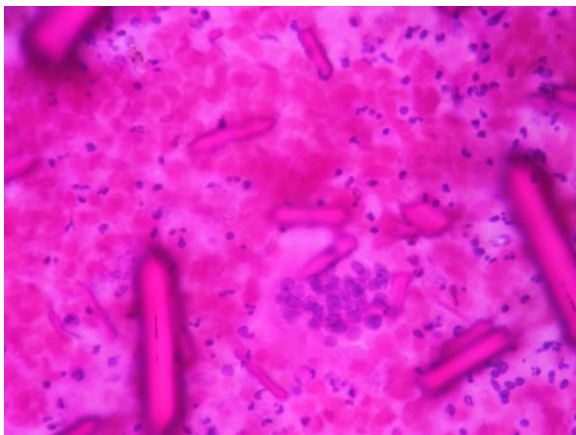


Figure 3: Smears showing crystalloids and a multinucleated foreign body giant cells (H&E,X400)

DISCUSSION

Crystalloids in a benign salivary duct cyst was first seen by Takeda & Ishikawa in 1983. [2] They described α -amylase crystalloids and proposed that crystalloids are formed from supersaturation of saliva representing crystallised amylase. Jayaram et al in 1993, first reported such crystalline structures is fine needle aspiration cytology of benign cystic lesions of parotid gland. [3] Johnson et al established that these crystalline structures in cystic parotid lesion were crystallized alpha amylase and they differed from the other crystalloids like tyrosine or collagen rich

crystalloids which were described in pleomorphic adenoma. [4]

Nature of amylase crystalloids in addition to morphology were described by Boutonnat et al by using mass spectrometry, transmission electron microscopy and measurement of amylase activity [5] Amylase crystalloids are translucent and are usually of size 500 μ . They are geometric shaped and are rectangular, rhomboid or bar shaped. They stain pink with Haematoxylin & Eosin stain, orange with Papanicolaou stain & dark blue with Diff-Quik stain. These crystalloids are non birefringent and are encountered only in benign lesions including retention cyst, lymphoepithelial cyst, Warthin's tumor and chronic sialadenitis. [6]

Other crystalline structures which can be encountered are tyrosine, oxalate, collagenous crystalloids & intramural crystals. Differentiation between these crystalloids from the amylase crystalloids is important as these geometric shaped crystals are found only in benign lesions where as other crystals may be encountered in malignant lesions. [7]

Tyrosine crystals are eosinophilic and appear as refractile with sun burst or flower like petal shaped with blunt ends on Haematoxylin & Eosin stain. They show positive reaction with Millen reagent & with diazotization coupling reaction. These crystals are non birefringent and are mainly encountered in pleomorphic adenomas. Rarely they are identified in malignant salivary gland tumors such as adenoid cystic carcinoma, carcinoma ex pleomorphic adenoma & low grade adenocarcinoma. [8] Collagenous crystalloids are birefringent and present as fusiform or radial fibres of collagen which appears eosinophilic on Haematoxylin & Eosin. With trichrome stain, they appear bright blue which indicates the presence of type -I collagen. They stain positive with Snook reticulin stain which indicates the presence of Type III collagen. Collagenous crystalloids were encountered in myoepitheliomas,

pleomorphic adenomas & myoepithelial carcinoma. [7]

Intramural crystalloids have geometric shapes and are amorphous dense filled with eosinophilic substance. They are of size 100 μ and are encountered in malignant salivary gland tumors. [9] They appear as rods, needles, rhomboid and polyhedrons embedded in eosinophilic amorphous material.

CONCLUSION

Identification of different types of crystalloids may help in diagnosis parotid lesions on fine needle aspiration cytology. Cytomorphology of crystalloids give clue to the cytopathologists. Amylase crystalloids are encountered in benign lesions where as other crystalloids can be seen in malignant lesions also

REFERENCES

1. Paker I, Anlar M, Genel N, Alper M. Amylase crystalloids on fine needle aspiration of salivary gland. Turk J Pathol. 2010;26:153-5.
2. Takeda Y, Ishikawa G. Crystalloids in salivary duct cysts of human Parotid gland. Scanning electron microscopical study with electron probe X-ray microanalysis Virchow's Arch A Pathol Anat Histopathol 1983; 399:41-8
3. Jayaram G, Khurana N, Basu S. Crystalloids in a cystic lesions of parotid salivary gland: Diagnosis by fine needle aspiration. Diagn Cytopathol.1993;9:70-1
4. Johnson FB, Oertel YC, Amman K. Sialadenitis with crystalloid formation: A report of six cases diagnosed by fine needle aspiration. Diagn Cytopathol 1995;12:76-80
5. Boutonnat J, Pueros V, Pinel C, Kieffer S, Fervier A, Garin J et al. Identification of amylase crystalloids in cystic lesions of the parotid gland. Acta cytol.2000;44:51-6.
6. Issac Rm, Oommen AM, Mathai JM. Crystalloids in salivary gland lesions. J Cytol 2014;31:194-5.
7. Bellizzi AM, Mills SE. Collagenous crystalloids in myoepithelial carcinoma: Report of a case and review of the literature. Am J Clin Pathol 2008;130:355-62].
8. Busra Y.Bayrak, cigdem Vural, Nadir Paksoy. Amylase crystalloids in fine needle aspiration cytology of parotid gland: A diagnostic challenge. Cytojournal 2015;12:12
9. Ro J Y, Mackay B, Batsakis JG, Cartwright J Jr. Intramural crystalloids in malignant salivary tumors (electron microscopic & x-ray microanalytical studies) J Laryngol Otol.1987;101:1175-81)

How to cite this article: Vissa S, Srinivasulu K, Rao NM et al. Crystalloids in cytology smears of parotid lesions: a diagnostic challenge. International Journal of Research and Review. 2018; 5(11):9-11.
