

# Alterations in Urine Routine Microscopic Analysis in Patients with Urinary Tract Infection

Mohd Khalid<sup>1</sup>, Mohd Rashid<sup>2</sup>

<sup>1</sup>Assistant Professor, Department of Ilmul Amraz, Hakeem Rais Unani Medical College, Sambhal, U. P., India

<sup>2</sup>Professor, Department of Microbiology, F. H. Medical College, Tundla, Agra, U. P., India

Corresponding Author: Mohd Rashid

## ABSTRACT

**Background:** Urinary tract infection (UTI) is among the leading reasons for treatment in adult primary care medicine, accounting for a considerable percentage of antibiotic prescriptions.

**Aim:** The current study was carried out in a tertiary care hospital in western UP, India with an aim to identify the markers of urinary tract infection by urine routine microscopic analysis.

**Method:** Urine of UTI patients was examined by physical, chemical (protein and glucose) and by microscopy methods.

**Result:** Urine color of the majority of patients was found to be pale yellow with turbid appearance. Protein was present in most of the samples whereas glucose was present in a minor number of samples. Microscopy revealed increase in pus and epithelial cells count in most of the samples while bacteria were present in all the samples.

**Conclusion:** It can be concluded from the present study that appearance, presence of protein, pus cells, epithelial cells and bacteria, all taken together can serve as a strong indicator of UTI.

**Keywords:** urinary tract infection, routine microscopy,

## INTRODUCTION

The routine examination of urine is a good tool for the calculation and observation of many diseases in human body. Different physico-chemical properties including color, pH, proteins, glucose, blood, and other abnormal constituents are the main objectives in any routine urine examination. Microscopic assessment is executed for the detection of RBCs, bacteria, leucocytes (pus cells), crystals, epithelial cells and casts. A 10 ml urine sample is enough for conducting urine routine microscopic analysis. [1] For the reliable results time interval should be less than two hours between collection of sample and its assessment. Sample of urine must be cooled if the examination is delayed. [2] The urine samples with abnormal physical conditions are clinically significant because

they can occur from many non-pathologic causes. Due to that the false negative and false positive results may arise. Abnormal urine test is the first indication of a major renal disorder. [3, 4] Owing to low cost and simplicity of urine analysis, it is the finest technique in early finding of mainly frequent conditions like hematuria, proteinuria or glycosuria. Urine RE is of great importance in the identification of symptomatic and analysis of asymptomatic disorders like assessment of kidney functions, urinary tract infection (UTI), metabolic disorders, jaundice, hemorrhagic conditions, kidney stones, trauma and malignancy etc. [5]

UTI is a condition where one or more structures in the urinary tract become infected after bacteria overcome its strong natural defenses. It is an important cause of

illness in humans and also one of the main causes of reproductive failures, general health complications and reduction of the life expectancy .It is the most common disease of urinary tract and also one of the main causes of reproductive failures, general health complications and reduction of the life expectancy [6] Many urinary infections resolve spontaneously, but others can progress to destroy the kidney. The infection process may involve the kidney, renal pelvis, ureters, bladder and urethra along with adjacent structures, such as prostate and epididymis in males. UTI are important complications of diabetes, renal disease, renal transplantation and structural neurological abnormalities that interfere with urine flow. [7-8]

### METHODOLOGY

**Study Area:** The present study was performed at a tertiary care hospital in western UP, India.

**Study population:** A total of 50 urine samples from UTI patients were included in this study. A single sample was taken from each patient.

**Sample Collection** A fresh mid-stream urine sample (10 ml to 15 ml) was obtained from patient in sterile urine container.

#### a) Physical Analysis:

Chromatic analysis of urine was done by examination of urine color. Variation in urine color like yellow, pale yellow, milky and reddish were noted. Appearance of urine (clear, turbid, hazy and cloudy) was also recorded for evaluation.

#### b) Chemical analysis:

**Assessment of protein:** 3-4 ml of centrifuged urine sample was transferred into a small test tube then 2-3 drops of sulfosalicylic acid were added on the top of the sample, after 5 min the turbidity was observed for the presence of protein (albumin).

**Assessment of glucose:** 2 ml of Benedict's reagent was added to 8 drops of urine and the mixture was heated for 5-10 min. No color change (blue) is indicative of glucose

absence whereas change in color intensity from green to brick red depicts increase in glucose content in the sample.

#### c) Microscopic analysis:

Urine samples were transferred to centrifuge tube and were centrifuged at 2500 rpm for 5 minutes, Supernatant was decanted off and the sediment was re-suspended in remaining urine in the tube. A single drop of this urine was transferred to a clean glass slide and a cover slip was fixed over it. Microscopic analysis of urine was done to check the presence of RBCs, pus cells, epithelial cells, crystals and presence of bacteria.

### RESULT AND DISCUSSION

The data obtained from physical, chemical and microscopic examination of urine from UTI patients revealed its pH to be within acidic range. However, color of the urine varies from pale yellow to red and milky. All the samples give putrid odour with few samples showing clear, cloudy and hazy appearance whereas majority of the samples looked turbid (Figure 1). Variation in color and appearance may be due to the difference in number of pus cells, RBCs, epithelial cells etc in the urine.

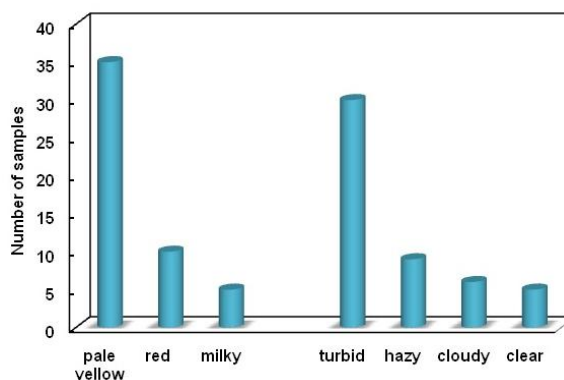


Figure 1: Physical analysis of urine sample from UTI patients.

Chemical analysis showed 38 out of 50 samples to be proteinuria positive while 43 samples were glucose negative (Figure 2). In our study albumin is present in most of the urine samples, the reason could be pyuria or some underlying renal disease. Thus, proteinuria can be considered as a marker for UTI. [9]

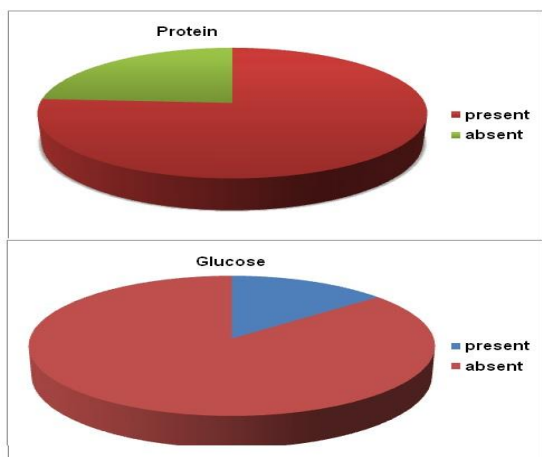


Figure 2: Chemical analysis of urine sample from UTI patients for detection of protein and glucose.

The data obtained from microscopic examination of revealed that pus cell count increases in all samples suffering from UTI. Majority of the samples depict the presence of RBCs while 39 samples showed presence of epithelial cells. The reason could be inflamed urinary tract of UTI patient. Crystals were present in just 6 samples. All the samples were found to be positive for bacteria (Table 1). It might be due to urinary tract infection cause by pathogenic microorganism such as *Escherichia coli*, *Klebsiella*, *Proteus* etc. [10]

Table 1: Microscopic examination of urine from UTI patients.

		Number of samples
Pus cells	5-6	06
	8-10	05
	12-15	09
	20-30	30
RBCs	Absent	17
	5-7	23
	35-40	10
Epithelial cells	2-3	11
	8-10	39
Crystals	Present	06
	Absent	44
Bacteria	Present	50
	Absent	00

## CONCLUSION

Based on the present study we conclude that no single factor can envisage

UTI. However, combined factors like appearance, proteinuria and microscopic examination taken together can strongly predict UTI in patients. As culture results are obtained after 24 - 48h, urine routine microscopic examination can help in presumptive diagnosis of UTI and on the basis of this, we can start empirical therapy.

## REFERENCES

- Humayun E, Bibi A, Khan A *et al.* Analytical study of urine samples for epidemiology of urinary tract infections by using urine r/e in local population of Abbottabad, Pakistan. *IOSR Journal of Pharmacy*.2015; 5: 32-38.
- Somerville JA, Maxted WC, Pahira JJ. Urinalysis a comprehensive review. *American Family Physician*. 2005; 71: 53-62.
- Weber G, Riesenber K, Schlaeffer F *et al.* Changing trends in frequency and antimicrobial resistance of urinary pathogens in outpatient clinics and a hospital in southern Israel. *Eur J Clin Microbiol Infect Dis*. 1997; 16: 834-838.
- Stamm WE, Counts GW, Running KR. Diagnosis of coliform infection in acutely dysuric women. *N Eng J Med*. 1982; 307: 463-468.
- Bronsema DA, Adams JR, Pallares R *et al.* Secular trends in rates and etiology of nosocomial urinary tract infections at a university hospital. *J Urol*. 1993; 150: 414-416.
- Ananthanarayan R, Jayaram Paniker CK. Urinary Tract Infections. In: Kapil A, eds. Text Book of Microbiology. 9<sup>th</sup> ed. Hyderabad, India: University Press; 2013: 671.
- Akmal Hasan SK, Naveen Kumar T, Radha Kishan N *et al.* Laboratory diagnosis of urinary tract infections using diagnostics tests in adult patients. *Int J Res Med Sci*. 2014; 2:415-421.
- Wilson ML, Giado L. Laboratory diagnosis of urinary tract infections in adult patients. *Clinical infectious Diseases*. 2004; 38:1150-1158.
- Lenherr SM, Clemens JQ, Braffett BH *et al.* Glycemic control and urinary tract infections in women with type I diabetes Results from the DCCT/EDIC. *J Urol*. 2016; 196: 1129-1135.
- Pande AM, Chavan RT, Muley SS *et al.* Studies on routine urine analysis of urinary tract infection. *Recent Research in Science and Technology*. 2011, 3: 38-39.

How to cite this article: Khalid M, Rashid M. Alterations in urine routine microscopic analysis in patients with urinary tract infection. *International Journal of Research and Review*. 2018; 5(10):360-362.

\*\*\*\*\*