

Original Research Article

Histological Effect of *Piper Guineense* (UZIZA) Leaves on the Liver of Wistar Rats

Joanita Nakatude Wasswa^{1,3}, Terry Nosa Omorodion², Godwin Ovie Avwioro³,
Olawale Saheed Asimiyu⁴

¹Health Services Department, Shell Nigeria Plc

²Department of Medical Laboratory Science, School of Basic Medical Sciences, University of Benin, Benin City, Nigeria,

³Faculty of Science, Delta State University, Abraka, Nigeria

⁴Department of Medical Laboratory Science, Babcock University, Ilishan-Remo, Ogun State, Nigeria

Corresponding Author: Terry Nosa Omorodion

ABSTRACT

The use of plant medicine dates back to ancient times, the nearly all year round availability and the relatively cheaper cost of medicinal plants in sub Saharan Africa makes them more attractive as therapeutic agents when compared to the orthodox medicine. The use of herbal medicine is on the increase globally, hence the increased interest on research on herbal formulations and preparations. Some of these plants are used as condiments and ingredients in food thus referred to as local spices. One of such plants used as a local spice in Nigeria is *Piper guineense* traditionally called 'Uziza' amongst the Igbo tribe, 'Iyere' amongst the Yoruba tribe, 'Etinkene' amongst the Efik and Ibibio tribe and 'Ebe-ahinhi akpoke' amongst the Edo tribe. The leaves and seeds of *Piper guineense* were initially consumed in the Southern part of Nigeria but overtime its consumption has spread across the entire country even into neighboring countries like Benin republic, Ghana, Liberia, Cameroun amongst others Also, its incorporation in intercontinental dishes and its high demand by Nigerians in foreign countries has promoted its use in countries far and wide. The aim of this research is to detect and demonstrate any histological effect of *Piper guineense* leaves on the liver of Wistar rats. Specific objectives are: To assess behavioral responsiveness of Wistar rats to the leaves of *Piper guineense*, to detect physical variation in normal body processes/ activities, to harvest and process liver successfully, to assess histological responsiveness of the liver to the leaves of *P. guineense*, to determine the amount of *P. guineense* that causes marked histological changes, to identify and compare histological effects of *P. guineense* leaves when consumed at different doses. During the course of experimental feeding, it was observed that all rats in the experimental groups responded positively to *Piper guineense* leaves. There was increased agility, faster consumption and enhanced coordination in the rats. There was also a characteristic aggressiveness amongst certain rats in groups four (4) and five (5). At purchase, the rats weighed between 125-145g. During the acclimatization period which lasted for two (2) weeks, three rats died due to what I termed the "**Helicopter Syndrome**" which is characterized by loss of appetite, emaciation, weakness, dislocation of neck with head leaning to the right, consistent rolling over and vigorous twirling in circular motion during carriage.

Keywords: Liver, *Piper guineense*, wistar rat

INTRODUCTION

The use of plant medicine dates back to ancient times, the nearly all year round availability and the relatively cheaper cost

of medicinal plants in sub Saharan Africa makes them more attractive as therapeutic agents when compared to the orthodox medicine. ^[1,2] The use of herbal medicine is

on the increase globally, ^[9] hence the increased interest on research on herbal formulations and preparations. ^[7] Some of these plants are used as condiments and ingredients in food thus referred to as local spices. One of such plants used as a local spice in Nigeria is *Piper guineense* traditionally called 'Uziza' amongst the Igbo tribe, 'Iyere' amongst the Yoruba tribe, 'Etinkene' amongst the Efik and Ibibio tribe and 'Ebe-ahinhi akpoke' amongst the Edo tribe. The leaves and seeds of *Piper guineense* were initially consumed in the Southern part of Nigeria but overtime its consumption has spread across the entire country even into neighboring countries like Benin republic, Ghana, Liberia, Cameroun amongst others ^[8] Also, its incorporation in intercontinental dishes and its high demand by Nigerians in foreign countries has promoted its use in countries far and wide. An assessment of the effect of *Piper guineense* consumption on various human organs is essential to ascertain merits and detect demerits if any in order to avert health conditions that may arise overtime due to continual use. An organ of particular interest is the Liver; the body's largest compound organ weighing 1.5kg in adult humans. It lies in the right upper quadrant of the abdomen and is completely protected by the thoracic rib cage. It is the principal metabolic organ and massive detoxification center for alcohol, drugs and other chemical substances, thus is directly influenced overtime by the toxicity of substances assimilated. The function of the liver as a detoxifying and clearance organ harbors the danger that the substances that should be degraded and/or eliminated eventually lead to tissue damage. ^[6] Nature has been a source of medicinal treatment for thousands of years and plant-based systems continue to play an essential role in the primary health care of underdeveloped and developing countries. Plants have formed the basis of traditional medicine system that has been the way of life for thousands of years. ^[5] The liver is a vital organ present in vertebrates and some other animals. It has a

wide range of functions, including detoxification, protein synthesis, and production of biochemicals necessary for digestion. The liver is necessary for survival and there is currently no way to compensate for the absence of liver function in the long term, although new liver dialysis techniques can be used in the short term. *Piper guineense* has been implicated as the cause of macrovesicular steatosis, disrupted liver cyto-architecture and cell necrosis when administered in high doses, thus implying the possibility of toxic side effects when used at certain doses consistently over a long period of time. The aim of this research is to detect and demonstrate any histological effect of *Piper guineense* leaves on the liver of Wistar rats. Specific objectives are: To assess behavioral responsiveness of Wistar rats to the leaves of *Piper guineense*, to detect physical variation in normal body processes/ activities, to harvest and process liver successfully, to assess histological responsiveness of the liver to the leaves of *P. guineense*, to determine the amount of *P. guineense* that causes marked histological changes, to identify and compare histological effects of *P. guineense* leaves when consumed at different doses.

MATERIALS AND METHODS

This research was carried out in the Department of Medical Laboratory Science, Babcock University, Ilesha-Remo, Nigeria. Thirty male Wistar rats of average body weight (125-145g) were purchased from the Department of Physiology, University of Ibadan, Ibadan, Oyo State, Nigeria. They were housed in a well ventilated room with a temperature of 28-30°C under the natural light and dark cycle. Fresh *Piper guineense* leaves were purchased from Ilesha market, Ilesha-Remo, Ogun state, Nigeria. They were identified by a representative from the Department of Crop and Soil Sciences, School of Agriculture and Industrial Technology, Babcock University, Ogun State. The *Piper guineense* leaves were sun dried for fourteen days to ensure proper removal of water content after which it was

grinded into powder using an attrition mill (a locally fabricated mill). The ground leaves were stored in a tightly covered plastic container to prevent the entrance of moisture. The thirty male Wistar rats were fed with standard laboratory diet and water ad libitum for an acclimatization period of fourteen days. After this period, the animals were divided into six groups, one control (VI) and five experimental groups (I, II, III, IV, V). The control group was given clean water and pelletised growers feed while the experimental group I, II, III, IV, V and V were fed increasing concentrations of *Piper guineense* leaves; 0.009g, 1.509g, 3.009g, 4.509g, and 6.009g per rat per serving. The rats were fed twice daily (morning and evening) for fourteen days. The rat cage was cleaned every forty-eight hours and all experimentations were carried out following the guideline for the care and use of laboratory animals obtained from the Institution's animal ethics committee. The Nutritional Composition of the Pelletised growers feed is; Crude Protein (14%), Fat (7%), Crude Fibre (10%), Calcium (1%),

Available Phosphorus (0.35%), Metabolisable energy (2550kcal/kg). LD₅₀ of *Piper guineense* is 100mg/kg.

Average rat weight is 175g; therefore, LD₅₀ is 17.5mg/175g daily, 8.75mg/175g per serving.

From the feeding pattern observed during acclimatization, 5 rats consume 65g of feed per serving indicating that 1rat consumes 13g of feed.

From personal findings, it was discovered that a 70kg human consumes 3.75g of Uziza per serving thus providing a baseline for *Piper guineense* constitution in the experiment as shown in the calculation below;

$$3.75g/70kg = 3.75g/70,000g$$

$$1g = 70,000 \div 3.75$$

$$1g = 18,666.67g$$

$$\text{Since } 1g = 18666.67g,$$

$$Xg = 175g$$

$$18666.67X = 175$$

$$X = 175 \div 18666.67$$

$$X = 0.009g.$$

Therefore; 3.75g/70kg human is equivalent to 0.009g/175g rat.

Table 1: Uziza and Pelletised Growers Feed (PGF) proportion in final experimental feed per 175g rat per serving in the six groups.

	Group I	Group II	Group III	Group IV	Group V	Group VI (Control)
Uziza (g)	0.009	0.509	1.009	1.509	2.009	0
PGF (g)	12.991	12.491	11.991	11.491	10.991	13
Total (g)	13	13	13	13	13	13

Twelve hours after the last feeding, the animals were anesthetized with chloroform vapor and dissected. The harvested liver was carefully dissected out, trimmed of all fat and connective tissue and blotted dry to remove any blood. The tissues were then fixed in 10% formal saline and transferred to a graded series of ethanol. On day 1, they were placed in 70% alcohol for 7 hours, then transferred to 90% alcohol and left in the latter overnight. On day 2, the tissues were passed through three changes of absolute alcohol for an hour each then cleared in xylene. Once cleared, the tissues were infiltrated in molten paraffin wax in the oven at 58°C. The tissues were then passed through three changes of molten paraffin wax at one-hour interval, after which the tissues were embedded in paraffin

wax and blocked out. Prior to embedding, it was ensured that the mounted sections to be cut by the rotary microtome were properly orientated. Serial sections of 5µm thick were obtained from a solid block of tissue, fixed on clean albuminized slides to enhance adhesion and later stained using the Haematoxylin and Eosin staining technique which was performed by; Dewaxing the sections in Xylene and Hydrating through descending grades of alcohol (Absolute, 90%, 80%, 70%) and finally into water, Staining for ten minutes in Ehrlich Haematoxylin and rinsing afterwards in water, Differentiating briefly in 1% acid alcohol and rinsing afterwards in water, Bluing for ten minutes in Scot tap water, Counterstaining for two minutes in 1% aqueous eosin and rinsing afterwards in

water, Dehydrating through ascending grades of alcohol (70%, 80%, 90% and Absolute), Clearing in two changes of xylene and air drying, Mounting in synthetic resin medium (DPX) and Examining with light microscope using x10 and x40 objective magnification. The initial and final weights of the rats and weight of the liver were measured using a weighing balance. Records of the histological results were obtained by photomicrography using digital photomicrographic microscope in the Department of Medical Laboratory Science, Babcock University, Ilishan-Remo, Ogun State, Nigeria.

RESULTS

During the course of experimental feeding, it was observed that all rats in the

experimental groups responded positively to *Piper guineense* leaves. There was increased agility, faster consumption and enhanced coordination in the rats. There was also a characteristic aggressiveness amongst certain rats in groups four (4) and five (5). At purchase, the rats weighed between 125-145g. During the acclimatization period which lasted for two (2) weeks, three rats died due to what I termed the “**Helicopter Syndrome**” which is characterized by loss of appetite, emaciation, weakness, dislocation of neck with head leaning to the right, consistent rolling over and vigorous twirling in circular motion during carriage. After two weeks of acclimatization, the rats weighed;

Table 2: Weight of rats per group after Uziza consumption for two weeks.

	Group I	Group II	Group III	Group IV	Group V	Group VI (Control)
Rat I	193.9g	208.7g	217.5g	162.1g	203.5g	208.9g
Rat II	181.0g	192.3g	202.2g	209.5g	222.1g	249.6g
Rat III	187.2g	198.4g	223.1g	207.2g	213.4g	240.5g
Rat IV	208.5g	192.2g	245.4g	219.4g	210.0g	
Rat V		194.9g	204.4g	168.4g	168.9g	
Average weight	192.7g	197.3g	218.5g	193.3g	203.6g	233.0g

After sacrificing the rats, the livers were harvested, fixed and weighed. The weights are given below;

Table 3: Weight of liver of sacrificed experimental rats per group.

	Group I	Group II	Group III	Group IV	Group V	Group VI (Control)
Rat I	8.5g	7.1g	8.1g	6.8g	6.9g	10.5g
Rat II	8.5g	8.1g	7.8g	6.2g	6.7g	9.8g
Rat III	7.4g	6.3g	6.7g	7.2g	6.2g	9.7g
Rat IV	7.2g	7.8g	8.7g	7.2g	7.5g	
Rat V		6.5g	8.4g	5.9g	7.1g	
Average weight	7.9g	7.2g	7.9g	6.7g	6.9g	10.0g

PHOTOMICROGRAPHY

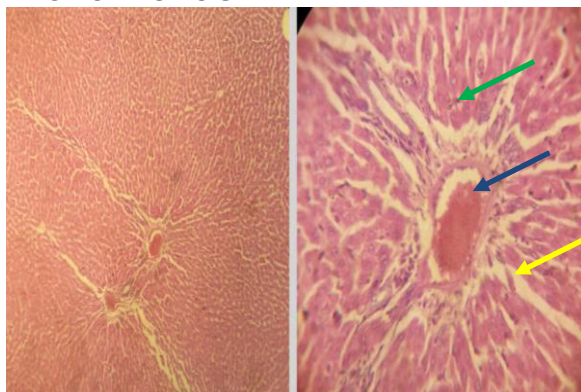


Figure 1: H&E Photomicrograph of Control liver at X10 and X40 showing a central vein with red blood cells (Blue arrow), hepatocytes (Green) and sinusoids (Yellow). The architecture is normal with normal cells. There are no inflammatory cells.

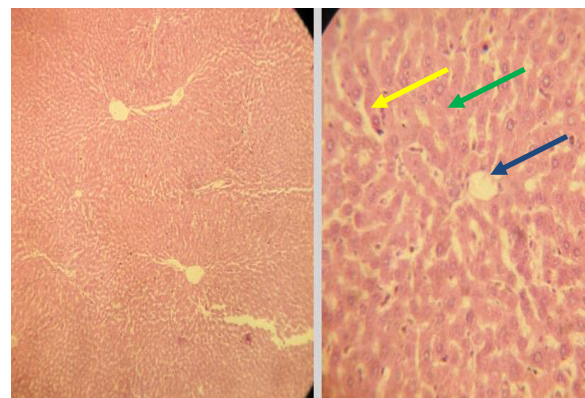


Figure 2: H&E Photomicrograph of Group I liver at X10 and X40 objective magnification. There are no inflammatory cells. There is no evidence of congestion or necrosis. The hepatocytes (Green) and sinusoids (Yellow) are also normal. The central vein (Blue arrow) is also normal

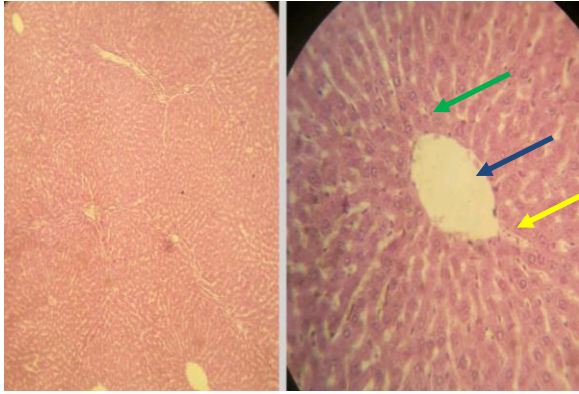


Figure 3: H&E Photomicrograph of Group II liver at X10 and X40 objective magnification. There are no inflammatory cells. There is no evidence of congestion or necrosis. The hepatocytes (Green) and sinusoids (Yellow) are also normal. The central vein (Blue arrow) is also normal

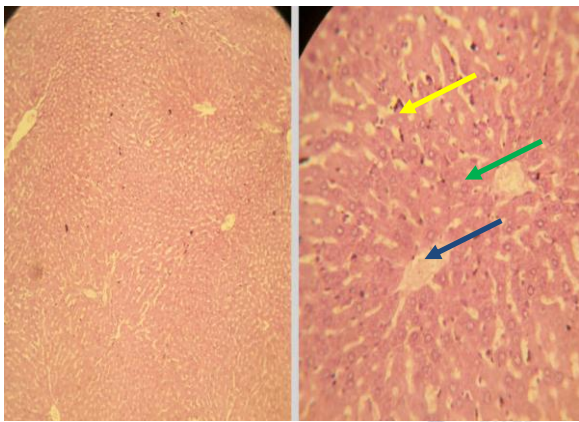


Figure 4: H&E Photomicrograph of Group III liver at X10 and X40 objective magnification. There are no inflammatory cells. There is no evidence of congestion or necrosis. The hepatocytes (Green) and sinusoids (Yellow) are also normal. The central vein (Blue arrow) is also normal

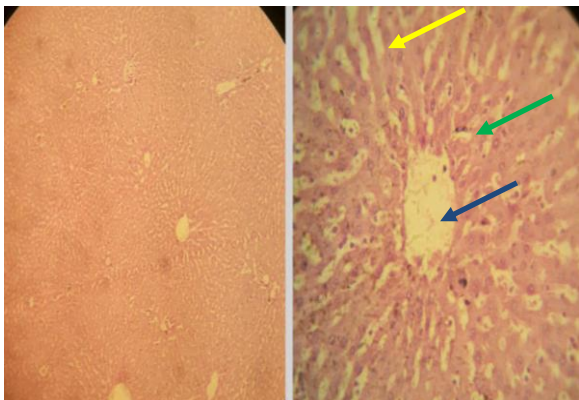


Figure 5: H&E Photomicrograph of Group IV liver at X10 and X40 objective magnification. There are no inflammatory cells. There is no evidence of congestion or necrosis. The hepatocytes (Green) and sinusoids (Yellow) are also normal. The central vein (Blue arrow) is also normal

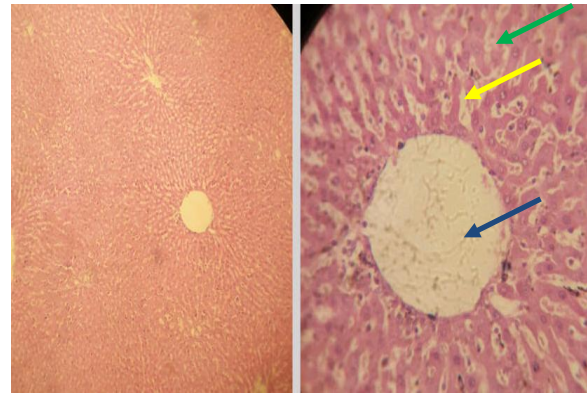


Figure 6: H&E Photomicrograph of Group V liver at X10 and X40 objective magnification. There are minimal inflammatory cells which are not significant. There is no evidence of congestion or necrosis. The hepatocytes (Green) and sinusoids (Yellow) are also normal. The central vein (Blue arrow) is also normal

RECOMMENDATION

The consumption of *Piper guineense* leaves at the experimental doses; 0.009g, 1.509g, 3.009g, 4.509g, and 6.009g by the Wistar rats, resulted in a histological picture that demonstrated liver tissue normality, good preservation of sinusoids and overall liver architecture, presence of minimal insignificant inflammatory cells and no evidence of congestion or necrosis, this is contrary to the report of Ebeye *et al.* (2007) who reported alteration in liver cyto-architecture and cell necrosis. This disparity could be due to the part of the *Piper guineense* plant used as used in 2010 made use of an extract from the plants seed, thus inferring a possible difference in the composition or concentration of chemical constituents of *Piper guineense* leaves and seeds. [2] There was increased agility and appetite observed in all the experimental Wistar rats especially those in the groups fed with the highest concentration of *Piper guineense* leaves and this is also contrary to the report by Ebeye *et al.* (2007) stating reduced agility and loss of appetite in the rats fed with higher concentrations of the *Piper guineense* seed extract. This variance could be due to the duration of the experiment which resulted in prolonged feeding and apparent lack of interest in the feed by the experimental animals. The significant increase in body weight observed at the end of the two weeks experimental feeding was is in line with the result of 2010

who reported a significant increase in the body weight of rats treated with *Piper guineense* [3] The increase in the body weight of the rats may be due to the androgenic properties of *Piper guineense* which possess anabolic activity. [4] Regardless of an increase in body weight, there was a decrease in the average weight of the liver. This intriguing detail could be further explored to derive a definite explanation divulging its cause.

CONCLUSION

Piper guineense leaves when taken reasonably has no effect on the histology of the liver, hence its use should be encouraged.

REFERENCES

1. Agbor, A.E. & Ngogany, Y.J. (2005). Toxicity of herbal preparations. *Cam. J. Ethnobot* 1, 23-28
2. Edem, D.O. & Usoh, I.F. (2009). Biochemical changes in Wistar Rats on oral doses of Mistletoe (*Loranthus micranthus*). *American Journal of Pharmacology and Toxicology* 4(3), 94-97. www.iiste.org/Journals/index.php/JNSR/article/download/2579/2595
3. Ebeyee, O.A., Emore, E., Enaibe, B.U. and Igbigbi, P.S. (2007). Histological Effect of *Piper guineense* Extract on Wistar Rats. *Journal of Biological Science*; 7(8): 1484-1487. scialert.net/fulltext/?doi=jbs.2007.1484.1487&org=11
4. Hassan I., Ogah M., Yusuf D., Musa M. & Saldu M. (2010): The Effect of Acute and Chronic (Short and Long term) Oral Administrations of Black Pepper (*Piper guineense*) Aqueous Extract on the Body Weight and Haematological Values of Albino-Wistar rat. *Journal of Medicinal Plants Research*. 4(12): 1122-1125. http://www.academicjournals.org/article/article1380714951_Hassan%20et%20a1.pdf
5. Mbongue F., Kantichoung P., Esame O., Yewah P., Dimo T. & Lontsi D. (2005): Effect of Extract of Dry Fruits of *Piper guineense* on the Reproductive Function of Adult Male Rats. *Indian Journal of Pharmacology*. 37:30-32. online.com/article.asp?issn=0253-7613;year=2005;volume=37;..
6. Mbongue O. & Ekeleme M. (2013): Comparative Study of In Vitro Antioxidant and Antimicrobial Activities of *Piper guineense*, *Curmuma longa*, *Gongronemalati folium*, *Allium Sativum*, *Ocimum gratissimum*. *World Journal of Medicine and Medical Science*. pp. 51-62.
7. Ramadori G., Moriconi F., Malik I. & Dudas J. (2008): Physiology and Pathophysiology of Liver, Inflammation and Repair. *Journal of Physiology and Pharmacology*. 59: 107-117. <http://www.iiste.org/Journals/index.php/JBAH/article/viewFile/26471/27522>
8. Tilburt, C. & Kaptchuk, J. (2008): Herbal Medicine Research and Global Health: At Ethic Analysis. *World Health Organization*. 86:594599. http://www.redorbit.com/news/health/1541eal_medicine_research_and_global_health_an_ethical_analysis/
9. Usenekong O., Sambo D. & Efiom O. (2013): Gas Chromatography- Mass Spectrometry Analysis of Petroleum Ether Extract of *Piper guineense* seeds (Schumand Thonn). pp.52.
10. World Health Organization (1996): WHO Guideline for the Assessments of Herbal Medicines. WHO Expert Committee on Specification for pharmacological preparations. Technical Report Series No. 863, Geneva. www.who.int/medicines/areas/quality.../expert_committee/WHO_TRS_992_web.pdf

How to cite this article: Wasswa JN, Omorodion TN, Avwioro OG et al. Histological effect of *piper guineense* (UZIZA) leaves on the liver of wistar rats. *International Journal of Research and Review*. 2017; 4(3):36-41.
