

Case Report

Anesthetic Management of Large Cystic Hygroma of Neck in a Newborn

Dr. Rakesh Kumar¹, Dr. Bhupendra Singh¹, Dr. Babita², Dr. Naveen Paliwal¹,
Dr. Neelam Meena³

¹Assistant Professor, ³Associate Professor,
Dept. of Anesthesiology, Dr. S. N. Medical College Jodhpur.
²ADMO Divisional Railway Hospital Jodhpur.

Corresponding Author: Dr. Bhupendra Singh

ABSTRACT

Cystic hygroma is a benign congenital tumour without any potential to malignancy. Its incidence of 1/6000 live birth commonly located in neck region. It is commonly present in pediatric age group rather than adult. Perioperative anesthetic management of large neck mass is real challenge due to difficulty in airway and hemodynamic management. We present a 3 month old male child admitted in hospital with swelling on right side of neck (10×8×6cm) extending to floor of mouth. . Initially child was put on conservative management. Swelling increases in size lead to push the tongue towards oropharynx causes respiratory distress and hemodynamic instability so emergency surgery was planned. Patient intubated keeping on spontaneous respiration after giving premedication and sevoflurane. Perioperative fluid and blood given according to weight and blood loss. After surgery patient shifted to neonatal ICU and next day patient extubated successfully

Key Words: cystic hygroma, newborn, anesthetic management

INTRODUCTION

Cystic hygroma (CH) is a benign progressive tumor characterized by a sac filled with lymphatic fluid that forms in the lymphatic system. 70-80% cases occurs at the nape of neck usually in the posterocervical triangle, ^[1] the remaining 20–30% occurs in the other part of the body axilla, superior mediastinum, chest wall, mesentery, retro-peritoneal region, pelvis and lower limbs. Cystic hygroma of neck region always be challenging for anesthesiologist due to difficulty in intubation because of extension of tumors into pharynx or thorax, presence of major vessels and nerves in neck, massive hemorrhage during surgery and concurrent congenital anomalies like down syndrome, turner syndrome.

CASE REPORT

A 3 month old male child weight 4.5kg admitted in hospital with swelling on right side of neck (10×8×6cm) extending to floor of mouth. Initially child was put on conservative management. Swelling increases in size because of sudden bleeding inside the swelling lead to push the tongue towards oropharynx causes respiratory distress and hemodynamic instability. Hb of patient decreased from 13g/dl to 8g/dl within 1 hrs. Patient shifted immediately into OT for emergency surgery.

On arrival in OT, patient respiratory rate was 60 breaths /minute, heart rate 190 beats /minute and arterial oxygen saturation (SpO₂) was 70-75% with 10 liter/minute oxygen via oxygen hood. Child

was drowsy, pale and decreased motor tone. Two 24G iv cannulae were secured and isolyte-p and blood & isolyte-p was started and optimized patient before surgery. 100% O₂ started with bag and mask. Standard monitoring consisting of ECG, non-invasive blood pressure and pulse oximetry was attached to patient. Patient was premedicated with inj atropine 0.02mg/kg and inj fentanyl 2mcg/kg. It was anticipated difficult intubation we preferred to maintain the spontaneous respiration at the time of induction but suddenly saturation start decreasing because of airway obstruction so guedel's airway no 0 used with chin lift and jaw thrust airway obstruction release and saturation improve. A shoulder roll was used to keep the child at optimal laryngoscopic position. Patient was induced with oxygen and sevoflurane and Laryngoscopy tried for intubation but there were no visualization of epiglottis we call for assistance and swelling was lifted upward and apply pressure on trachea to optimal visualisation of epiglottis and intubation tried with the help of stylet but not successful. Then we call our senior anesthesiologist and he puncture the swelling with wide bore 16 G needle and aspirate fluid from swelling which cause decrease size of swelling and pressure release on trachea then optimal attempt tried and intubation done with the help of stylet. A straight blade laryngoscope was used (miller no 2) a 3 mm uncuffed endotracheal tube was used for intubation. After confirmed the bilateral air entry & ETCO₂ for tube positioning, the ETT was fixed with sutures to left side of angle of mouth to prevent accidental extubation due to manipulation during surgery. Anesthesia was maintained on oxygen, nitrous oxide, sevoflurane (2-3%) and Inj. atracurium 1.5 mg and supplemental doses 0.1 mg/kg were used SOS. Due to hemodynamic status of patients and nature of surgery it was anticipated massive blood and fluid loss for this reason insert invasive arterial blood pressure line in radial artery to monitor sudden hemodynamic changes. Surgery last

for four hours. Intraoperative blood loss around 100 ml was replaced. Due to surgical manipulation around the neck there is chance of developing reactionary edema we give 25mg hydrocortisone & put patient on electively ventilation for 24 hours. After fulfilling the extubation criteria, patient was extubated successfully next day in ICU.

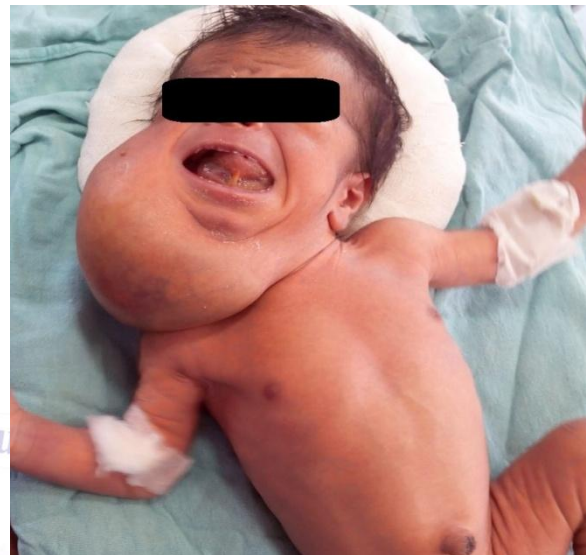

Fig 1

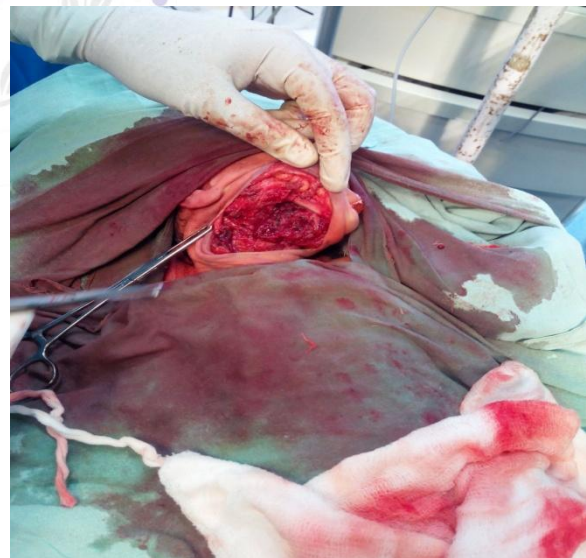


Fig 2

DISCUSSION

Cystic hygroma, also called cavernous hemangioma is a histologically benign congenital tumor of lymphatic origin. [1] The most important sign is the presence of a swelling followed by interference with normal breathing and swallowing. [2]

Various treatment options include continued observation, repetitive suction, injection of curing agent into the mass, radiation therapy and radio frequency treatment. [3,4] However, the only radical treatment method is surgical removal. General surgery is performed when the patient is 18 months to 2 years old. (2) In our case, the size of the lump was continuously increasing due to sudden hemorrhage inside the swelling causing respiratory distress and hemodynamic instability so it was considered for emergency surgical removal. (5)

Preoperative evaluation is an important step in managing these cases. It is most important for the anesthesiologist to understand the size and extent of the neck mass, the range of invasion into the respiratory tract by the mass. All cases must have chest x-ray to exclude the presence of intrathoracic lesions.

Pediatric airway always be challenging to anesthesiologist due to having unique anatomical, cardiophysiological differences and rapid desaturation due to high oxygen consumption and low functional residual capacity. (6,7) Cystic hygroma of neck region exaggerated above condition. The most important step in anesthetic management of CH is the provision of safe and secure airway to avoid hypoxia. As most anesthetic mishaps result from hypoxia as a result of airway problem. (8) Different options are available for intubation depending upon availability and expertise. Inhalation anesthesia remains the preferred technique for management of a difficult pediatric airway. In our case we induced with fentanyl, oxygen, nitrous oxide and sevoflurane keeping on spontaneous respiration until airway is secured.

The second problem is about airway maintenance during surgery. (8) Considering the uncuffed endotracheal tube, large surgical field, manipulation of head and neck by surgeon during surgery there is always possibility of accidental extubation or endobronchial migration of tube causing rapid development of hypoxia. In our case to prevent this we suture endotracheal tube to angle of mouth. Large tumor mass anticipated to more blood loss so arterial line inserted for invasive blood pressure monitoring. We covered baby with cotton roll and used warm fluid and maintain OT room temperature to prevent hypothermia.

REFERENCES

1. Wang TC, Wu CM, Sun LS, Chiang TC. [Giant cystic hygroma: a case report]. *Zhonghua Yi Xue Za Zhi (Taipei)* 1993; 51: 479-81.
2. Sharma S, Aminuldin AG, Azlan W. Cystic hygroma: Anaesthetic considerations and review. *Singapore Med J* 1994; 35:529-31.
3. Samuel M, McCarthy L, Boddy SA. Efficacy and safety of OK-432 sclerotherapy for giant cystic hygroma in a newborn. *Fetal Diagn Ther* 2000; 15: 93-6.
4. Gross E, Sichel JY. Congenital neck lesions. *Surg Clin North Am* 2006; 86: 383-92
5. Ishaq M, Minhas MR, Hamid M, Punjwani R. Management of compromised airway due to unusual presentation of cystic hygroma. *J Pak Med Assoc* 2006; 56: 135-7.
6. Caplan RA, Posner KL, Ward RJ, Cheney FW. Adverse respiratory event in anesthesia: a closed claim analysis. *Anesthesiol* 1990; 72:828-32.
7. Pethkar T, Malde A. Anesthetic management of cystic hygroma of tongue in a child. *J Anesthesiol Clin Pharmacol* 2011; 27:421-3.
8. Kim H, Kim HS, Oh JT, Lee JR. Anesthetic management for neonate with giant cystic hygroma involved upper airway: A case report. *Korean J Anesthesiol* 2011; 60:209-13.

How to cite this article: Kumar R, Singh B, Babita et al. Anesthetic management of large cystic hygroma of neck in a newborn. *International Journal of Research and Review*. 2017; 4(2):23-25.
