

Case Report

# Autologous Stem Cell Assistance in Periodontal Regeneration Technique (SAI-PRT) In Treatment of Grade II Furcation Defect

Dr. Vandana KL<sup>1</sup>, Dr. PriyankaJairaj Dalvi<sup>2</sup>

<sup>1</sup>M.D.S, Sr. Professor, <sup>2</sup>B.D.S, Postgraduate student,  
Dept. of Periodontics, College Of Dental Sciences, Davangere 577004

Corresponding Author: Dr. Vandana KL

## ABSTRACT

Invasion of bifurcation and/or trifurcation of multi-rooted teeth are the most serious complications of periodontitis, resulting in early and frequent loss of molars than any other teeth type. The current report describes a novel approach of direct application periodontal ligament stem cells using stem cell application in periodontal regeneration technique in regeneration of furcation defect bypassing ex vivo culture. We used soft tissue harboring the periodontal ligament stem cells (PDLSCs) adherent to the root of an extracted impacted wisdom tooth along with its cementum and dentin shavings to restore the periodontal furcation defect of another molar of the same patient. The current approach resulted in improvement in clinical parameters, probing pocket depth reduction and gain in clinical attachment loss with negligible changes in gingival marginal position and clinical and radiographic improvement in furcation defect. Stem cell application in periodontal regeneration technique has emerged as a constructive avenue in treatment of periodontal furcation defects. Moreover the clinical feasibility, success and cost effectiveness over currently available techniques are encouraging.

**Key words:** furcation involvement; periodontal regeneration; stem cells.

## INTRODUCTION

Invasion of bifurcation and/or trifurcation of multi-rooted teeth are the most serious complications of periodontitis, resulting in early and frequent loss of molars than any other teeth type. [1] Various treatment modalities involve either maintaining existing furcation (scaling and root planing) or increasing access to furcation (gingivectomy/ apically positioned flap, odontoplasty, osteoclast/ostectomy), or its elimination (root amputation/tooth resection, bicuspidization). The regenerative approach seeks to eliminate periodontal defects by creating new bone and periodontal ligament and coronally displacing gingival attachment and margin. Novel cell based approaches based on tissue

engineering principles have achieved periodontal regeneration in a predictable manner. Use of periodontal ligament stem cells in periodontal regeneration is very promising. [2]

We utilized stem cell assistance in periodontal regeneration technique (SAI-PRT) [3] using direct application of autologous periodontal ligament stem cells (stem cells), cemental and dentin scrapings (signaling molecules) and gelatin sponge (scaffold) which is based on tissue engineering triad [4] in the treatment of grade II furcation defect [5] bypassing the ex-vivo culture in the current case report. The direct application of autologous periodontal stem cells, cementum scrapings and dentin shavings in treatment of furcation defect

was attempted for the first time in periodontal literature.

### CASE DESCRIPTION

An apparently healthy 28 year old male patient reported to the department of Periodontics with the chief complaint of food lodgment in the lower left back tooth region since 2 years. Occasionally, bleeding occurred while brushing the teeth. On clinical examination, the oral hygiene status of the patient was found to be good with moderate gingivitis. The periodontal evaluation revealed periodontal pocket in relation to left mandibular second molar midbuccally and grade II furcation involvement. [5] Intraoral peri-apical radiograph showed widening of periodontal ligament space and radiolucency in the furcation area. Based on this history, clinical findings and radiographic evaluation diagnosis of localized periodontitis was reached upon.

The treatment plan was explained to the patient and a written consent was obtained. The study protocol was approved by institutional review board (IRB no. 2014/C11-09) and was in compliance with the Helsinki declaration.

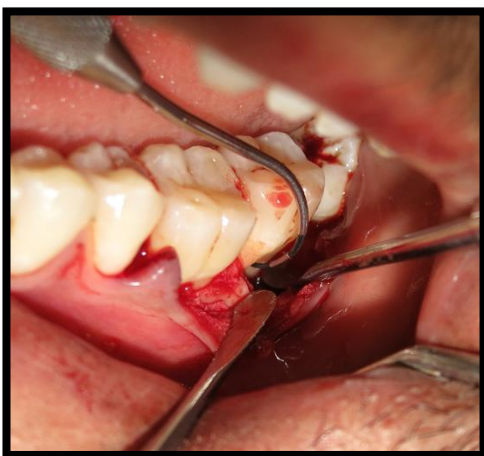


Figure 1: Grade II furcation involvement seen with respect to left mandibular second molar

Following the surgical protocol, a full-thickness mucoperiosteal flap was raised involving distal of mandibular left

first molar to distal of mandibular left second molar teeth beyond the defect (Figure 1).

Complete debridement of the furcation defect was done followed by extraction of the impacted maxillary left third molar. The transplant consisted of soft tissue adherent to root of an extracted third molar [6] and the extraction socket [7] which harbored the PDLSCs and cementum scraping which was obtained by gently scraping the tooth root and extracted socket using a sterile curette Abgel®©™( gelatin sponge-Shri Gopal Krishna Labs Pvt. Ltd. Mumbai, Maharashtra India) which was cut into small pieces (1mm ×1mm) was mixed with the autologous transplant in a sterile dappen dish to obtain a transferable mass to the selected furcation defect. The soft tissue scrapings was mixed quickly with Abgel®©™ to preserve the viability of stem cells in it. The pre-sutured knot was tightened and periodontal dressing was placed. Post-operative instructions were given and suture removal was done after 10 days. Post-surgical medication were prescribed as follows: Antibiotics (amoxicillin 500mg Tid) and analgesics (paracetamol 650mg bid) was prescribed. The post-surgical course was uneventful. The sutures were removed after 10 days. The control site was treated by open flap debridement. Clinical examination was performed at baseline and at six months and one year post- surgery (Table 1).

### RESULTS

All the measures of this study were performed by the same calibrated examiner using a PCP-UNC 15 and Naber's probe approximated to the nearest mm. Presence of bleeding on probing, gingival marginal position(GMP) probing pocket depth (PPD), furcation involvement using furcation stent and degree of furcation involvement were recorded. (Table 1)

**Table 1 clinical measurements of left mandibular second molar furcation area at different time intervals**

Clinical variables (in mm)	Stem	Cell (Test group)	therapy	OFD (Control group)		
	Baseline	6 months	1 year	Baseline	6months	1 year
Horizontal measurement of furcation involvement	5mm	3mm	1mm	5mm	3mm	3mm
Vertical probing depth (mid buccal)	9mm	6mm	3mm	8mm	6mm	6mm
Clinical attachment level(CAL) Midbuccal	8mm	5mm	1mm	7mm	5mm	3mm
Gingival margin position	5mm	4.5mm	4.5mm	5mm	4mm	4mm
Gingival thickness	1.5mm	1.5mm	1.5mm	1.2mm	1.2mm	1.2mm

Standardized radiographs were evaluated at baseline 6months and 1year (Figure 2 and 3).

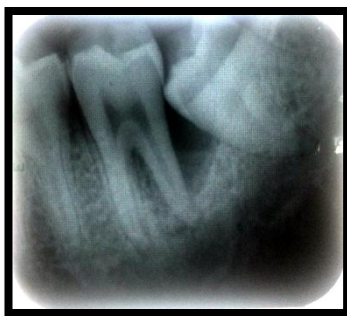

Figure 2 baseline radiograph (left mandibular second molar)

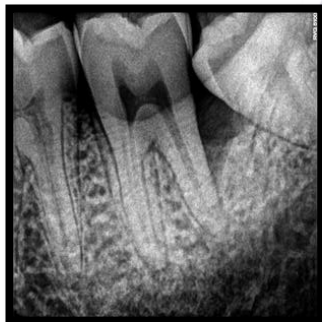


Figure 3: 1year follow up radiograph(left mandibular second molar)

The radiographic density changes were measured using Adobe PhotoshopCS3. There was change in radiodensity (as calculated by histogram using Adobe Photoshop) observed in the defect area suggestive of improvement in newly formed bone.

## DISCUSSION

Periodontal regeneration is defined histologically as regeneration of the tooth's supporting tissues, including alveolar bone, periodontal ligament, and cementum over a previously diseased root surface. [8] The human periodontal ligament (PDL) encloses

subpopulation of stem cells which exhibit multipotency, as demonstrated by their ability to differentiate into osteoblasts, fibroblasts and tooth cement oblasts and to form cementum- and PDL-like tissues, and are generally termed periodontal ligament stem cells (PDLSCs.) They were first isolated from the periodontal ligament tissue of extracted human third molar teeth. [6] In addition to the periodontal ligament of the root surface following tooth extraction, the PDL remaining on the alveolar bone surface of the extraction sockets has also been used to isolate PDLSCs. [7]

Cementum appear to play a critical role in the regeneration of the tooth attachment apparatus and is a rich source of many growth factors such as IGF, FGF, BMPs etc. which influence the activities of various periodontal cell types [9,10] while dentin exhibits biochemical components which are similar to bone e.g. dentin contains growth factors: insulin-like growth factor (IGF)-II, bone morphogenetic protein (BMP)-2, and transforming growth factor beta (TGF)- $\beta$ . [11] The presence of dentin promotes the formation of a calcified tissue similar to bone and accelerates healing whilst inhibiting inflammatory reaction. [12] Tooth dentin contain a number of bone growth factors including type I collagen and bone morphogenic protein (BMP) and have been used in treatment of periodontal osseous. [13] Agelatin sponge owing to its flexibility, biocompatibility, and biodegradability, and potential to be used as a scaffold [14] to support osteoblasts and to promote bone regeneration in defective areas was considered in the current case report.

We utilized soft tissue adherent to the extracted impacted third molar

harboring the periodontal ligament stem cells along with cemental and dentin scrapings for their potential role in periodontal regeneration in the treatment of furcation defect in the same patient. The direct application of autologous periodontal stem cells in treatment of furcation defect using stem cell application in periodontal regeneration technique [3] was attempted for the first time in periodontal literature and this technique abides by the tissue engineering triad [4] using PDLSCs from impacted third molar (cells), Abgel®<sup>TM</sup> (gelatin sponge - scaffold) [14] and cementum scrapings and dentin shavings which consist of variety of signaling molecules. [10-12] e.g. IGF, VEGF etc.

The immediate periodic healing events were uneventful. The improvement in probing pocket depth (PPD), gain in clinical attachment level (CAL) or radiographic demonstration of original defect resolution has been an important observation of the study. The radiographic density changes were measured using Adobe PhotoshopCS3 for the first time in literature.

The basis of SAI-PRT [3] is undoubtedly based on study by Feng et al [2] which demonstrated use of ex-vivo processed PDL stem cells in the treatment of 3 periodontal cases. The basic problem faced during ex-vivo cell culture is that the sensitive nature of the procured PDLSCs from the extracted tooth root to survive for ex-vivo culture. There are several attempts by the researcher to succeed in the stem cell survival, as the first step in ex-vivo cell culture expansion. Keeping this in mind, the authors of the paper attempted to place the periodontal ligament tissue adherent to the root directly into the selected osseous defect following extraction of impacted tooth in the same patient. In fact on microscopic examination this tissue contains all the cells favorable for tissue regeneration. The crucial step of cell survival by direct placement served the best of tissue engineering which was constituted in the current novel technique by mixing the

PDLSCs with a sponge and cementum and dentin scrapings containing growth factors was fruitful. Thus the tissue engineering from lab become a chair side reality.

Studies have proved that soft tissues on the extracted third molar root harbors PDLSCS, which have shown a clinical and radiographical improvement in the treatment of periodontal osseous defects. [1,15,16] Based on this, in SAI-PRT we are attempted to transplant the autologous PDLSCs directly into the periodontal osseous defects. As an evidence based approach initiated in 2014, out of 10 cases, the first case report of 12 months evaluation is presented in this case report. The clinical and radiographic outcome measures are highly successful as compared to control group of open flap debridement. Since there are no bone graft / substitute used in this study as used in other studies [1,11] direct transplantation of autologous PDLSCs containing tissue, it is discernable that the successful clinical and radiographic changes in the treated site is attributable to the PDLSCs .

At present the limitations of the study are the uncertainty on the number and viability of cells transplanted immediately after scraping the tissues from the root surface of extracted tooth. As of now lack of histologic evidence and invitro analysis of stem cells characterisation and osteogenic potential are few of important short comings. Further studies are being directed where in 15 patients are undergoing current therapy as randomised controlled trial with the due consideration of addressing the above said short comings.

## CONCLUSION

A simple task of PDLSCs procurement and immediate placement are the major advantages of the current concept, the autologous Stem cell Assistance in Periodontal Regeneration – Technique (SAI-PRT) [3] that has emerged as a constructive avenue in treatment of periodontal osseous defects. Moreover the clinical feasibility, success and cost effectiveness over currently available

techniques are encouraging. The clinical utility of this novel idea is recommended.

**Conflicts of interest:** “the authors declare no conflicts of interest”

## REFERENCES

1. Tsao YP, Neiva R, Al-Shammari K, Oh TJ, Wang HL. Factors influencing treatment outcomes in mandibular class 2 furcation defects. *J. Periodontol* 2006; 77:641-646.
2. Feng F, Akiyama K, Liu Y, Yamaza T, Wang TM, Chen JH, Wang BB, Huang GT, Wang S, Shi S. Utility of PDL progenitors for in vivo tissue regeneration: a report of 3 cases. *Oral Dis.* 2010; 16:20-8.
3. Vandana KL, Desai R, Dalvi PJ. Autologous Stem Cell Application in Periodontal Regeneration Technique (SAI-PRT) Using PDLSCs Directly From an Extracted Tooth...An Insight. *Int J Stem Cells.* 2015; 8:235-7.
4. Kao RT, Murakami S, Beirne OR. The use of biologic mediators and tissue engineering in dentistry. *Periodontol* 2000 2009; 50:127-53.
5. Glickman I. Bifurcation involvement in periodontal disease. *J Am Dent Assoc* 1950; 40:528-538.
6. Seo BM, Miura M, Gronthos S, Bartold PM, Batouli S, Brahimi J, et al. Investigation of multipotent postnatal stem cells from human periodontal ligament. *Lancet* 2004;364:149-55.
7. Wang L, Shen H, Zheng W, Tang L, Yang Z, Gao Y, et al. Characterization of stem cells from alveolar periodontal ligament. *Tissue Eng Part A* 2011; 17:1015-26.
8. Consensus report. Periodontal regeneration around natural teeth. *Ann Periodontol.* 1996; 1:667-70.
9. Narayanan AS, Bartold PM. Biochemistry of periodontal connective tissues and their regeneration: a current perspective. *Connect Tissue Res* 1996; 34:191-201.
10. Saygin NE, Giannobile WV, Somerman MJ. Molecular and cell biology of cementum. *Periodontol* 2000 .2000; 24:73-98.
11. Schmidt-Schultz TH, Schultz M. Intact growth factors are conserved in the extracellular matrix of ancient human bone and teeth: a storehouse for the study of human evolution in health and disease. *Biol Chem.* 2005; 386:767-76.
12. Holland R, Nery MJ, Souza V, Bernabé PF, Mello W, OtoboniFilhoJA. The effect of the filling material in the tissue reactions following apical plugging of the root canal with dentin chips. A histologic study in monkeys' teeth. *Oral Surg Oral Med Oral Pathol.* 1983; 55:398-401.
13. Kim YK, Lee J, Um IW, Kim KW, Murata M, Akazawa T et al. Tooth-derived bone graft material. *J Korean Assoc Oral Maxillofac Surg.* 2013; 39: 103–111.
14. RaminRohanizadeh AE, Michael V. Swain AE, Rebecca S. Mason. Gelatin sponges (Gelfoam) as a scaffold for osteoblasts. *J Mater Sci Mater Med* 2008; 19:1173–1182.
15. Graziano A, Carinci F, Scolaro S, D'Aquino R. Periodontal tissue generation using autologous dental ligament micro-grafts: case report with 6 months follow-up. *Ann Maxillofac Surg* 2013; 1: 20
16. Chen FM, Gao LN, Tian BM, Zhang XY, Zhang YJ, Dong GY et al. Treatment of periodontal intrabony defects using autologous periodontal ligament stem cells: a randomized clinical trial. *Stem Cell Res Ther.* 2016; 7:33.

How to cite this article Vandana KL, Dalvi PJ. Autologous Stem cell assistance in periodontal regeneration technique (SAI-PRT) in treatment of grade II furcation defect. *International Journal of Research and Review.* 2017; 4(2):5-9.

\*\*\*\*\*