

Case Report

Myxoid Dermatofibrosarcoma Protuberans: A Diagnostic Dilemma

Dr. Evith Pereira¹, Dr. Shilpi Sahu², Dr. Manisha Tambekar², Dr. Reeta Dhar³,
Dr. Kalyani Mahore¹

¹Resident, ²Associate Professor, ³HOD & Professor,
Department of Pathology, MGM Medical College, Navi Mumbai.

Corresponding Author: Dr. Evith Pereira

ABSTRACT

Dermatofibrosarcoma Protuberans (DFSP) is a relatively uncommon soft tissue neoplasm with intermediate to low grade malignancy which rarely metastasizes but has a higher proclivity for local recurrence. The myxoid variant of DFSP is rare which often presents with diagnostic challenge clinically and histopathologically. We herein report a highly recurrent, locally aggressive DFSP that failed twice surgically and was diagnosed as myxoid variant of DFSP on histopathology and immunohistochemically.

Key words: Dermatofibrosarcoma, Myxoid, recurrence,

INTRODUCTION

The term Dermatofibrosarcoma protuberans was first coined by Hoffman in the year 1925. [7] The entity originates from the dermis and is a rare malignant dermal tumor. Dermatofibrosarcoma Protuberans (DFSP) is a rare, locally aggressive dermal mesenchymal neoplasm with a great potential of recurrences exhibiting a small risk of distant metastasis. The incidence rate is reported to be nearly 5 per 1 million people annually and accounts for between 2% to 6% of all soft tissue sarcomas. DFSP is resistant to chemotherapy as well as radiotherapy thus leaving surgery as the only modality of treatment with five year survival rate being 88.9%. Different variants of DFSP have been described in the English literature, those including classic, pigmented (Bernard tumor), fibrosarcomatous, granular cell, flat atrophic, myxoid variant as well as variants with myogenic differentiation. The myxoid

variant is one of the least commonest types which presents on the limbs, head, neck and trunk in adults. We herein report a highly recurrent, locally aggressive myxoid DFSP. [1-5]

CASE REPORT

75 year old male, farmer by occupation, presented to surgery outpatient department with history of mass over right lower limb since 1 and half years. On examination the mass measured 18x9x 2cm, firm in consistency and was non-tender. Scar was also noted during examination. On further enquiring about the same, patient mentioned about the recurrence of the mass and it being excised twice previously without any further histopathological examination of the same. FNAC of the swelling showed loosely cohesive tumor cells comprising of oval to spindle cells embedded in collagenous stroma with individual cell showing mild anisonucleosis

with fine homogenous chromatin and ill defined cytoplasmic borders, cytomorphological features were suggestive of spindle cell lesion.

The patient underwent wide local excision of the mass and the specimen was sent for histopathological examination. On gross examination, mass was skin covered measuring 17x 8.5x1 cm with two circumscribed, firm nodules, largest measuring 7x7x5 cm and smallest measuring 5x4x3.5 cm. On cut section the mass was yellowish tan coloured with no areas of hemorrhage or necrosis seen. (Figure 1-A, B, C). Hematoxylin and Eosin stained sections studied showed tumor cells arranged in fascicles, vague storiform pattern at the periphery showing marked myxoid degeneration along with both neoplastic proliferation of fibroblasts and histiocytes. The histiocytes being round to oval with vesicular nucleus and indistinct cytoplasm. Mild degree of nuclear pleomorphism and occasional mitosis was seen along with increased blood vessel proliferation. (Figure 2A & 2B). Immunohistochemically the tumor cells were positive for CD 34, focally positive for SMA, Ki-67 showed 40% proliferative index and were negative for S- 100, Pan Ck and Desmin thus confirming the diagnosis of DFSP with myxoid variant. (Figure 3- A,B,C,D & E)

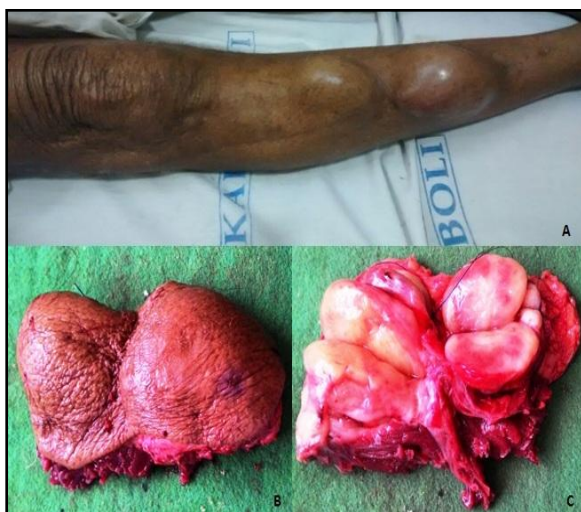

Figure 1A & 1B - Skin covered mass measuring 18x 9 9x2cm in size, along with scar seen on lateral aspect of right leg.
Figure 1C - Cut section of the mass shows Yellowish tan coloured homogenous mass with no areas of necrosis and hemorrhage.

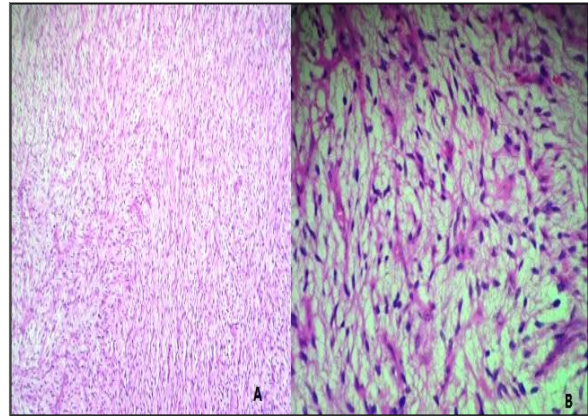


Figure 2A - sections show tumor cells arranged in fascicles, vague storiform pattern at the periphery showing marked myxoid degeneration (H & E 10x).
Figure 2B - myxoid degeneration along with both neoplastic proliferation of fibroblasts and histiocytes. (H & E 40x).

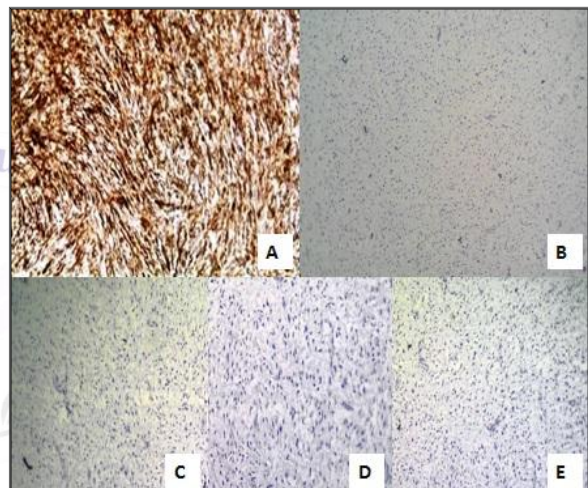


Figure 3A - CD 34 - strong positive
Figure 3B - Ki67 - 40 % proliferative index
Figure 3C, D & E - Negative for Desmin, Pan ck and S-100

DISCUSSION

Dermatofibrosarcoma protuberans was first described clinically in 1980. Darrier and Ferran described the tumor as 'progressive and recurrent dermatofibrosarcoma or skin fibrosarcoma'. Although DFSP can be seen at any age, it is more common in 30-50 years of age with the incidence being 0.8-4.2 per million populations of which approximately 10% are children. The exact cause of DFSP is unknown. However, cytogenetic studies have shown tumor cells with chromosomal anomalies together with mononuclear cellular origin, with reciprocal translocation $t(17;22)(q22;q13)$ or a supernumerary ring chromosome $r(17;22)$. Both of which give

rise to chimeric gene COL1A1-PDGFB through the fusion of collagen type 1alpha gene on chromosome 17 and platelet growth factor beta chain gene on chromosome 22. Translocation is a common abnormality found in children whilst ring chromosome abnormality been seen predominantly in adults. Some studies also describe DFSP at vaccination sites, in the scars of surgical incisions or of dermal burns. [1-6]

The myxoid subtype is a rare entity of DFSP and was first described by Frierson et al in 1983. In one of the largest case series published of dermatofibrosarcoma protuberans, only 4.3% of the lesions were of myxoid subtype. The differential diagnosis of myxoid dfsp includes myxoid liposarcoma, myxofibrosarcoma, myxoid neurofibroma and superficial angiomyxoma. Myxoid lesions varies from classic variant by presenting mainly on the lower limbs, the next frequent sites being trunk and anogenital region. [3] The cells in myxoid variant are embedded in an abundant, pale eosinophilic myxoid stroma and prominent, thin walled blood vessels are frequently present throughout the tumor. The myxoid eurofibroma can be distinguished by the presence of S-100 protein positivity, Superficial angiosarcoma can be difficult to distinguish as it tends to show positivity for CD34 but as histologically it tends to display lobular growth pattern with scattered neutrophils surrounding the vessels, it helps in distinguishing from dfsp. Immunohistochemical findings were consistent with that of classical dermatofibrosarcoma protuberans, with it being positively stained for CD34, with increased Ki-67 proliferative index and negative for markers such as Desmin, S-100, epithelial markers it thus helped us to distinguish from malignant fibrous histiocytoma [MFH] which expresses CD68 and to come to a conclusive diagnosis of Myxoid variant of DFSP. [4,7]

Multiple finger-like projections grow within the nodules at the periphery of the tumor mass. The DFSP with its finger-like projections is frequently disseminated

to beyond to the level of vision. Insufficient excisions of these projections were thought to be responsible for the high relapse rate. [9] The tumor invades laterally through the fascicles of the dermis over a period of many years, which may vary from half a year to 30 years. After this period, the tumor enters the growth phase and infiltrates the subcutaneous tissues and deep fascial structures. [8,10] Satellite nodules coalesce to form a bulky mass, producing the typical protuberant appearance of well-developed lesions. Pain and increased sensitivity might indicate the early stages of the period of rapid growth. As the mass grows aggressively, the skin becomes stretched and thinned out, ulcerations may form which may be bleeding. In some untreated cases, dermal infarcts can be seen on the surface of bulky tumors. Reported diagnostic survey was up to 10 years. The average tumor size has been reported to be less than 5 cm and, according to the literature, tumors of 10 cm or more are extremely rare.

The metastases rate is reported to be less than 5% in DFSP. Metastases may occur many years after the onset of the disease and are mostly to lungs, followed by the regional lymph nodes; the visceral organs and bones are rarely affected The most likely explanation for the occurrence of local relapse is insufficient local resection with positive boundary tissue on histopathology. Poor prognostic factors are older age, increased activity and advanced period.

Histologically, DFSPs should be differentiated from fibrohistiocytic neoplasms and lesions such as malignant fibrous histiocytoma, atypical fibrosarcoma, dermatofibrosarcoma, infantile myofibromatosis, nodular fasciitis, keloid, and hypertrophic cicatrix, all of which may have similar pathologic findings. In the immunohistochemical investigations, the CD-34 marker is positive while other fibrohistiocytic lesions being usually negative for CD-34 expression. [9-11]

The preferred therapy of DFSP is radical wide surgical excision which includes resection of a 3-cm margin of skin beyond the borders of the tumor and should include the fascia and even muscle tissue if necessary to attain negative intact borders histopathologically. Radiotherapy is of limited value in the treatment of DFSP. However, it might have some role to play when the resection border is positive or when extensive excision is not possible due to cosmetic or functional difficulties. [8-10]

CONCLUSION

The myxoid variant is one of the least common types of dermatofibrosarcoma protuberans which makes it difficult to diagnose it clinically from other superficial myxoid tumors, with FNAC and histopathology along with immunohistochemistry being the mainstay for diagnosis. We herein presented an interesting case of myxoid DFSP with local recurrence and awareness of this rare variant is important to avoid misdiagnosis of myxoid tumors and their treatment modalities.

REFERENCES

1. Jiang J-Q, Huang Z, Wang L-H, Shen S-D, LU H. Dermatofibrosarcoma protuberans of the breast: A case report. *Oncology Letters*. 2014;8(3):1202-1204.
2. Valiulyte Agniete, et al.. Dermatofibrosarcoma protuberans in adolescence: a case report and literature review. *Lietuvos Chirurgija* 2015; 14(1): 61-64.
3. Campos M, et al. Dermatofibrosarcoma protuberans mixoide infantile. *Actas Dermosifiliogr*.2012;103:422-6.
4. Al-Daraji W, Husain E, Zelger BG, Zelger B. A Practical and Comprehensive Immunohistochemical Approach to the Diagnosis of Superficial Soft Tissue Tumors. *International Journal of Clinical and Experimental Pathology*. 2009;2(2):119-131.
5. Softah A. Recurrence of dermatofibrosarcoma protuberans: a case report and a review of literature.. *Indian J Chest Dis Allied Sci* 2003 Oct-Dec; 45(4):261-3.
6. Trinh, S., Hanna, P., Petersen, K., Elsayy, O. Dermatofibrosarcoma Protuberans: A Case Report and Review of Surgical Management. *Journal of Current Surgery, North America*, 6, jul. 2016;6(2):57-59
7. Hong YJ, Choi YW, Myung KB, Choi HY. A Case of Myxoid Dermatofibrosarcoma Protuberans. *Annals of Dermatology*. 2011;23(3): 379-381
8. Laskin WB. *Dermatofibrosarcoma protuberans*. *CA Cancer J Clin*. 1992;42:116–25
9. Minter RM et al.. Metastatic potential of dermatofibrosarcoma protuberans with fibrosarcomatous change. *J Surg Oncol*. 2003 March; 82(3):201-8
10. Sirvent N et al. Genetics of dermatofibrosarcoma protuberans family of tumors: from ring chromosomes to tyrosine kinase inhibitor treatment. *Genes Chromosomes Cancer*. 2003 May; 37(1): 1-19.
11. Garcia C. et al. Dermatofibrosarcoma protuberans.. *Int J Dermatol* 1996 Dec; 35(12):867-71

How to cite this article: Pereira E, Sahu S, Tambekar M et al. Myxoid dermatofibrosarcoma protuberans: a diagnostic dilemma. *International Journal of Research and Review*. 2017; 4(1):99-102.
