

Recurrent Aphthous Stomatitis: A Review

Dr. Santosh Kumar¹, Dr. Shresth Kumar Bhagat², Dr. Mobeen Khan³,
Dr. Archana Bhagat⁴, Dr. Khushboo Kumari⁵, Dr. Rekha Prashad⁶

¹Senior Lecturer, Department of Conservative Dentistry and Endodontics, PDCH, Government Dental College Patna, Bihar.

²Reader, Department of Conservative Dentistry and Endodontics, Mithila Minority Dental College and Hospital, Darbhanga, Bihar.

³Senior Lecturer, Department of Oral Medicine and Radiology, Chandra Dental College and Hospital, Safedabad, Barabanki, Uttar Pradesh, India.

^{4,5,6}BDS, Private Practitioner, Bihar.

Corresponding Author: Dr. Mobeen Khan

ABSTRACT

Recurrent aphthous stomatitis (RAS) or recurrent aphthous ulcer (RAU) is a common disorder. They affect higher patient groups. There may be a female predominance in some adult and child patient. Recurrent Aphthous Ulcers are very painful oral mucosal disorder. They occur mainly in childhood and decreases as age increases. Symptomatic treatments are the main line of treatment. Topical medications are preferred. Diet modification improves the condition and quality of life.

KEY WORDS: RAS; Systemic Steroids; MiRAS; MjRAS; HRAS

INTRODUCTION

Aphthous stomatitis is a common condition affecting the oral cavity resulting in ovoid or round ulcerations on the oral mucosa. It is a very painful inflammatory oral mucosal condition which can cause pain on eating, swallowing and speaking. [1] It has been reported to affect 20% of the general population. [2] The peak age of RAS onset is during childhood and has a tendency to decrease in severity and frequency with age. [3]

Aetiopathogenesis:

- **Family history:** Genetic factors are likely to predispose patients to RAS, and more than 40% of affected individuals have first degree relatives with RAS. [4]
- **Immunopathogenesis:** The pathogenesis of RAS involves a predominantly cell-mediated immune response in which TNF- α plays a major role. [5]

Predisposing Factors:

- **Local factors:** Physical irritation at non keratinized local sites can initiate aphthous ulcerations. [6] Stress, smoking cessation, hormonal imbalance and food hypersensitivity are also known to be local predisposing factors. [7]
- **Systemic factors:** Immune disturbances- large aphthous ulcerations may be seen in the cases where CD4 cell count is less than 100 cells per milliliter. [8]
- **Hematinic deficiency states:** Deficiency of B₁, B₂, B₆, B₁₂ or iron may be associated with aphthous ulcerations. [9]
- **Gastrointestinal Disease:** Celiac disease and gluten sensitive enteropathy are reported to be associated with aphthous ulcerations. [10]
- **Behcet's syndrome:** It comprises of classical RAS and a range of systemic complications, affecting the eyes, joints, skin and neurological system. [11]

- **Periodic fever, aphthae, pharyngitis and adenitis syndrome (PFAPA):** Comprises periodic fever, aphthae like oral mucosal ulceration, pharyngitis and cervical adenitis. Although rare, PFAPA occurs in young children. It is self-limiting, and non-recurrent. [12]
- **Sweet's syndrome:** Also termed acute neutrophilic dermatosis. Affected patients have superficial ulceration similar to RAS. In addition, there is sudden onset fever, leucocytosis and well demarcated cutaneous, plum-coloured papules or plaques. Usually arises in middle-aged females. [13]

Clinical Presentation:

Three clinical presentations of RAS are recognized:

- ❖ Minor recurrent aphthous stomatitis (MiRAS)
- ❖ Major recurrent aphthous stomatitis (MjRAS)
- ❖ Herpetiform recurrent aphthous stomatitis (HRAS)

Minor Recurrent Aphthous Stomatitis (MiRAS):

This is the most common form of RAS and approximately 80% of patients has lesions of this type. [3] The characteristic picture of minor aphthous consists of a number of small ulcers (one to five) appearing on the buccal mucosa, the labial mucosa, the floor of the mouth or the tongue.

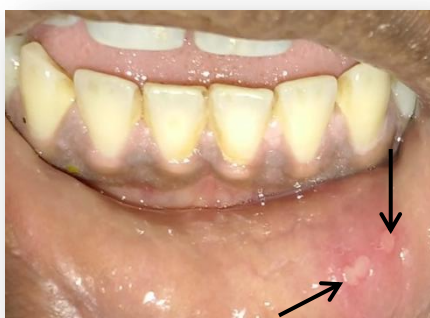

Fig1: Minor Recurrent Aphthous Stomatitis (Black Arrow)

Major Recurrent Aphthous Stomatitis (MjRAS):

MjRAS accounts for approximately 10–15% of cases, [3] The ulcers tend to be larger than those of minor aphthae, and they are of greater duration, up to a period of months in some cases. [14]

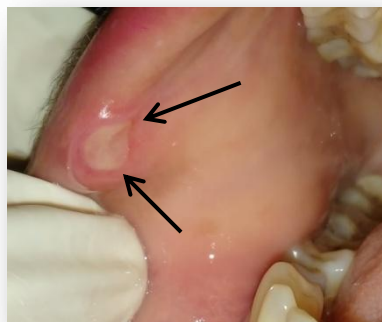

Fig2: Major Recurrent Aphthous Stomatitis (Black Arrow)

Herpetiform Recurrent Aphthous Stomatitis (HRAS):

It is the least common form of aphthous ulcers, affecting 5–10% of cases. [3] Individual ulcer are grey and without a delineating erythematous border. HRAS mimics ulcers of primary herpes simplex virus (HSV) infection. These ulcers are very painful. These ulcers decrease quality of life by causing difficulty in eating and speaking.

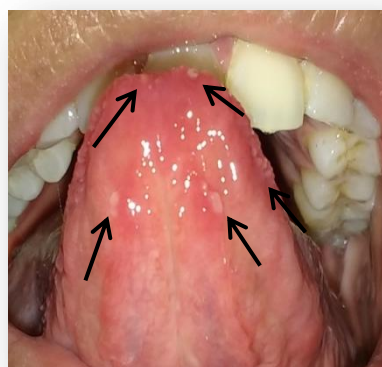


Fig:- 3 Herpetiform Recurrent Aphthous Stomatitis (Black Arrow)

S.No.	Clinical Features	Minor RAU	Major RAU	Herpiform RAU
1	Age	Childhood	Puberty	After puberty
2	Gender	M=F	M=F	F>M
3	Sites	Labial mucosa, Buccal mucosa, floor of mouth	Labial mucosa, soft palate and fauces	Labial mucosa, buccal mucosa, lingual mucosa, palatal mucosa, gingival mucosa, floor of the mouth, pharynx
4	Size (mm)	<10	>10	1-2 Can be larger in case of fusion of ulcer
5	Number	1-5	1-10	10-100
6	Duration (days)	4-14	>30	<30
7	Rate of Recurrence (months)	1-4	<monthly	<monthly
8	Permanent scarring	Uncommon	Common	Uncommon

MANAGEMENT

The etiology of RAS still remains unknown; therefore there is no definitive treatment. The goal of treatment is to decrease symptoms, reduce ulcer number and size and increase disease free periods. The treatment planning is done according to the disease severity, patient's medical history and frequency of flare ups. The patients are classified into 3 clinical presentations to determine management strategies.

- **Type A:** The patients experiencing RAS episodes lasting for only a few days, occurring a few times a year only are placed in this category. The patient is able to tolerate the pain in this category. The clinician must try to remove the predisposing factor first like physical trauma. The clinician must identify what the patient uses to treat ulcers, and if effective and safe, he should encourage the patient to continue the same. [15]
- **Type B:** the patient experiencing painful ulcers lasting between 3-10 days, each month are categorized in this category. The treatment in these cases includes the use of chlorhexidine mouthwash and short course of topical steroids as soon as ulcer appears. The alternate regimens include dexamethasone 0.05 mg/5 mL (rinse and spit) or a high potency topical corticosteroid ointment. [16] The patient must be observed for yeast superinfection. In recalcitrant patients short course of systemic steroids can also be given, which should not exceed 50 mg per day for five days. [15] Dose tapering of the systemic corticosteroids

is necessary to minimise the side effects. Complete oral and systemic health evaluation is important before prescribing the steroids.

- **Type C:** It involves painful, chronic ulcers in which by the time one ulcer heals, another appears. These patients are treated by potent topical corticosteroids such as betamethasone, beclomethasone, clobetasol, fluocinonide or systemic steroids, azathioprine or other immunosuppressant such as dapsone, pentoxifylline and sometimes thalidomide. [3] Also, intralesional injections of corticosteroids such as betamethasone, dexamethasone or triamcinolone. [15]

CONCLUSION

Recurrent aphthous stomatitis (RAS) or recurrent aphthous ulcers (RAU) remains a common oral mucosal disorder in most communities of the world. Proper systemic evaluation is important before prescribing the medication. Topical medications are easily washed away from the target area so systemic medications play a very important role in the management of RAS.

ACKNOWLEDGEMENT

Authors acknowledge the immense help received from the scholars whose articles are cited and included in reference of this manuscript. The authors are grateful to authors / editors / publishers of all those articles, journal and books from where the literature for this article has been reviewed and discussed.

REFERENCES

1. Miller MF, Ship II. A retrospective study of the prevalence and incidence of recurrent aphthous ulcers in a professional population, 1958-1971. *Oral surg Oral med Oral pathol* 1977; 43(4): 532-7.
2. Rennie JS, Reade PC, Hay KD, et al. Recurrent aphthous stomatitis. *Br Dent J* 1985; 159: 361-7.
3. Rogers RS, 3rd. Recurrent aphthous stomatitis. Clinical characteristics and associated systemic disorders. *Semin Cutan Med Surg* 1997; 16: 278-83.
4. Shohat-Zabarski R, Kalderon S, Klein T, et al. Close association of HLA-B51 in persons with recurrent aphthous stomatitis. *Oral Surg Oral Med Oral Pathol* 1992; 74: 455-8.
5. Natah SS, Hayrinen-Immonen R, Hietanen J. Immunolocalization of tumor necrosis factor- alpha expressing cells in recurrent aphthous ulcer lesions(RAU). *J oral Pathol Med* 2000; 29(1): 19-25.
6. Ross R, Kutscher AH, Zegarelli EV, Silvers H, Piro JD (1958). Relationship of mechanical trauma to recurrent ulcerative (aphthae) stomatitis. *N Y State Dent J* 24: 101-102.
7. Field EA, Longman LP. *Tyldesley's Oral Medicine*, 5th edn. Oxford: Oxford University Press, 2003.
8. Muzyka BC, Glick M. major aphthous ulcers in patient with HIV disease. *Oral Surg Oral Med Oral Pathol* 1994; 77(2):116-20.
9. Wray D, Ferguson MM, Mason DK. Recurrent aphthae: treatment with vitamin B12, folic acid and iron. *Br Med J* 1987; 2:490-3.
10. Wray D, Ferguson MM, Carmicheal HA. Et el. Coeliac disease associated with recurrent aphthae. *Gut* 1980; 21:223-6.
11. Schwatz T, Langevitz P, Zemer D. behcet's disease in familial Mediterranean fever: characterization of the association between the two diseases. *Semin Arthritis Rheum* 2000; 29:286-95.
12. Marshall GS, Edwards KM, Butler J, et al. Syndrome of periodic fever, pharyngitis and aphthous stomatitis. *J Pediatr* 1987; 110: 43-6.
13. Notani K, Kobayashi S, Kondoh K, et al. A case of Sweet's syndrome (acute febrile neutrophilic dermatosis) with palatal ulceration. *Oral Surg Oral Med Oral Pathol Oral Radiol Endod* 2000; 89: 477-9.
14. Scully C, Porter S (1989). Recurrent aphthous stomatitis: current concepts of etiology, pathogenesis and management. *J Oral Pathol Med* 18: 21-27.
15. Scully C, Gorsky M, Lozada-Nur F. The diagnosis and management of recurrent aphthous stomatitis: a consensus approach. *J Am Dent Assoc* 2003; 134: 200-7.
16. Siegel MA (1999). Strategies for management of commonly encountered oral mucosal disorders. *J Calif Dent Assoc* 27: 210-219.

How to cite this article: Kumar S, Bhagat SK, Khan M et al. Recurrent aphthous stomatitis: a review. *International Journal of Research and Review*. 2017; 4(11):35-38.
