

Case Report

# Inflammatory Bowel Disease (Ulcerative Colitis) Simulating/Masquerading as Acute Appendicitis

Bashir B. M<sup>1</sup>, Saddiku M. S<sup>2</sup>, Maiyaki A. S<sup>3</sup>, Abubakar I. U<sup>1</sup>

<sup>1</sup>Department of Surgery, <sup>2</sup>Department of Pathology, <sup>3</sup>Department of Medicine, Usmanu Danfodiyo University Teaching Hospital, Sokoto.

Corresponding Author: Bashir B.M.

Received: 18/08/2016

Revised: 31/08/2016

Accepted: 01/09/2016

## ABSTRACT

Inflammatory bowel disease (IBD) occurs more common in developed countries and is relatively unusual /rare in Africa, Asia and South America. Incidence in developing countries is likely to increase due to increasing endoscopic equipment. IBD could mimic other intestinal conditions like Amoebiasis, shigellosis, intestinal schistosomiasis and appendicitis. We are reporting an interesting case of a young nulliparous woman who initially presented with features of Acute appendicitis and was diagnosed later to have ulcerative colitis.

**Key words:** Inflammatory bowel disease (IBD), ulcerative colitis (UC).

## INTRODUCTION

IBD is an idiopathic disease associated with dysregulated immune response to host microflora. IBD generally denotes two disease of unknown cause with similar general characteristics Ulcerative Colitis (UC) and Crohn's Disease (CD). Distinction between the two can be established based on clinical and pathologic criteria. Where a clear distinction cannot be made, the disease is labeled indeterminate colitis (IL).

## CASE REPORT

A 28 year old female, who presented with a day history of right iliac fossa pain and vomiting with a 6 - month history of recurrent Muco bloody stools more than 6 episodes/day. She has no fever, abdominal distension, weight loss or chronic cough. No history of similar presentation in her family. She doesn't smoke cigarette or consume alcoholic beverages.

**Examination:** general examination findings

were unremarkable. Abdominal examination reveals positive pointing sign, right iliac fossa tenderness and rebound tenderness with positive psoas sign. DRE reveals an examining finger stained with Muco-bloody stool. She had appendectomy with a histologic finding of acute appendicitis with peritoneal inflammation. She subsequently had upper and lower GI endoscopy when symptoms persists post operatively.

Colonoscopy revealed pseudo polyps, crypt abscesses and continuous mucosal inflammation, especially in the rectum. The scope could not be advanced beyond the sigmoid because of intense mucosal inflammation. Multiple random biopsies were taken, which revealed chronic nonspecific inflammation. Upper GI endoscopy and biopsy- reveals antral gastritis with a histologic finding of H-pylori associated Gastritis. Stool MCS-No ova of Parasite seen. ESR & Mantoux - within normal limit. She was placed on 5-

ASA (ASACOLON), high dose steroid & Omeprazole. She got better; stool frequency has reduced to 1/day.

## DISCUSSION

The earliest documentation on UC was made by Samuel Wilks of London in 1859. While Crohn, Ginsberg and Oppenheimer published a landmark article on terminal ileitis in 1932, later named Crohn's Disease (CD). [3] IBD generally denotes two diseases of unknown cause (CD&UC) with similar general characteristics. Distinction between the two entities can usually be established based on clinical and pathological criteria. Where a distinction cannot be made its termed indeterminate colitis (IC) [1,2,5,8] Globally the incidence rate of IBD, UC & CD is 396/100,000, 0.5- 24.5/100,000 & 0.1-16/100,000 respectively. A disease of young people with a peak incidence between 10-40 years or a bimodal peak between 15-25 years & 40-60 years. [2,3,5-7] The extent of the disease in developing countries is largely unknown. [2,3,5-7]

Despite years of extensive research the genesis of IBD is unknown but theories suggest the cause is multifactorial (interplay between genetics & Environment). The chronic inflammation resulting from the dysregulation of gut immune system in response to a genetic failure to process certain commensal antigens leads to the development of either CD or UC. This is mediated by Th<sub>1</sub> & Th<sub>17</sub> T cell for CD while UC result from Th<sub>2</sub> & NKT cell pathway. A defect of CARD15/NOD2 (Caspase-recruitment Domain 15/ Nucleotide oligomerization 2) gene on chromosome 16q<sup>12</sup> is associated with increased risk of ileal CD- the locus has being named IBD. [1] Other loci that have being implicated are IBD, [2] IBD. [3-7] Family history is present in 5-20% of cases with first degree relatives having 20-50 fold risk of developing CD and 10-20 fold for UC. The hygiene hypothesis proposes that individual of low socioeconomic status or less privileged are exposed to helminth / microbes early in life

which confers reduced risk to IBD. Whereas the old Friends being microbes to which the intestinal immunogenic system have become commensals to during evolution. Smoking increases the risk for CD (Thrombogenic & Vasculitis effect) & confers protection for DC (Nicotine has protective effect). The risk of UC is said to be lowered by previous appendectomy. Our patient presented with symptoms that lasted for 2 months this is in contrast to other reportable cases in sub Saharan Africa in which patient symptoms lasted for years before diagnosis. The availability of trained personnel and endoscopic equipment coupled with the educational level of the patient may be responsible for early diagnosis. The presentation of our patient (Abdominal pain, Muco-bloody stool) was typical & most common feature as reported by other studies. [1-3,5-7] The colonoscopic findings of pseudo polyps, continuous mucosal inflammation & crypt abscesses were consistent with severe colitis based on true love & witts criteria, this similar to the findings by reference. [3,5,6]

Gaffen *et al* also reported pseudopolyps, mucosal ulceration and oedema as part of their findings on contrast studies. [9]

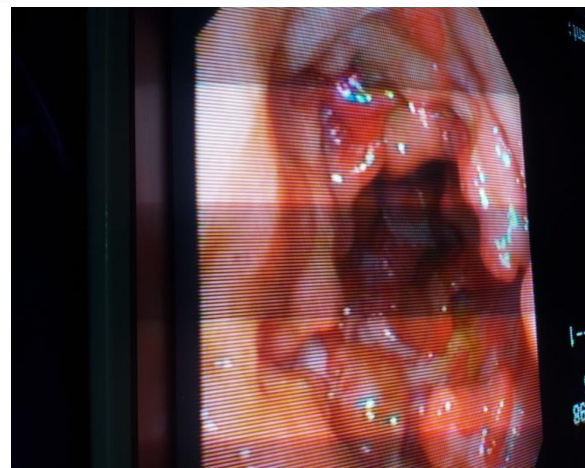


Fig 1: Colonoscopy view of colon showing pseudo-polyps and crypt abscesses

Histologic findings of nonspecific chronic inflammation are also seen as in other reports. [5,6] No extra intestinal manifestation was seen also as reported by. [3]

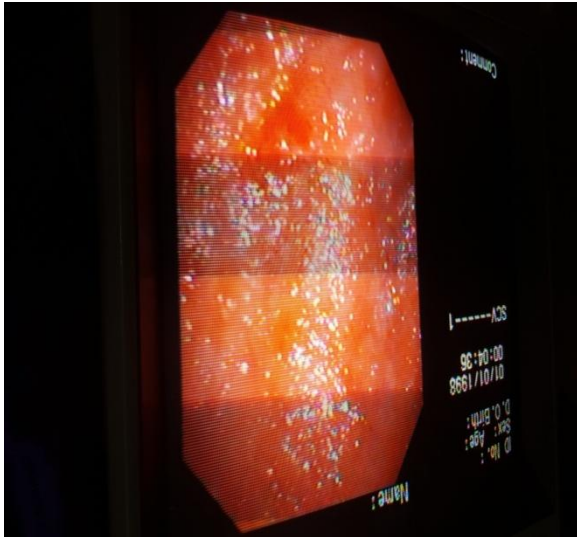


Fig 2: Colonoscopic view of inflammatory Rectal Mucosa

## CONCLUSION

Ulcerative Colitis is a rare disease in this environment, and the extent of the disease is largely unknown. Many cases remain undiagnosed because of wide variation in clinical presentation, as well as lack of awareness of the disease, and non-availability of endoscopic equipments. With increasing availability of trained personnel and endoscopic equipments, early diagnosis and treatment can substantially improve quality of life, and prevents complications.

## REFERENCES

1. Silverberg MS, Satsangi J, Ahmad T, Arnott ID, Bernstein CN, Brant SR, Caprilli R, Colombel JF, Gasche C, Geboes K, Jewel DP. Towards an integrated clinical, molecular and serological classification of inflammatory Bowel Disease: A Report of a working party of the 2005 Montreal world congress of Gastroenterology Can j Gastroentrol 2005 Sep 1, 19 (Suppl A) : 5-36.

2. Cater MJ, Lobo AJ, and Travis SP. Guidelines for the management of IBD in Adults. Gut 2004 Sep 1, 53(Suppl 5): VI-6.
3. Ukwenya AY, Ahmad A, and Odigie VI, Mohammed A. Inflammatory Bowel disease in Nigeria: Still a rare diagnosis? Annals of African Medicine 2011; 10 (2).
4. Leighton JA, Shen B, Baron TH, Adler DG, Davila R, Egan JV, Faigel DO, Gan SI, Hirota WK, Lichtenstein D, Qureshi WA. ASCE Guideline: Endoscopy in the diagnosis and treatment of Inflammatory Bowel Disease. Gastrointestinal endoscopy 2006 Apr 30; 63(4): 558-65.
5. Olatise OI, Otegbayo JA, Nwosu MN, Lawal OO, Ola SO, Anyawu SN, Ndububa DA, Akere A, Odike MA, Agbakwuru EA, Soyemi OM. Characteristic of Inflammatory Bowel Disease in Three Tertiary Health Centres In Southern Nigeria. West African Journal of Medicine. 2014 Jun 3; 31 (1):28-33.
6. Obaseki DE, Forae GD Clinicopathological Features of Inflammatory Bowel Disease in Benin City, Nigeria. International Journal of Advanced Medical & Health Research. 2014 Jan; 1(1):16.8
7. Oludara M, Akinola R, Popoola A, Makajuola S. Inflammatory Bowel Disease, a rare or under Diagnosed disease in Nigeria. British Medical Journal of Medicine and Medical Research. 2014Dec 11; 4(35):5620.
8. Bamias G, Nyce MR, Sarah A, Cominelli F. New Concept in the pathophysiology of inflammatory bowel disease. Annals of internal Medicine. 2005 Dec 20; 1443 (12): 895-904.
9. Gaffen N, Darnbough A, Dedonbal FT, Watkinson G, Goligher SC, Radilogical Signs of Ulcerative Colitis: assessment of their reliability by means of observer variation studies. Gut 1968 Apr 1:9 (2):1506.

How to cite this article: Bashir BM, Saddiku MS, Maiyaki AS et al. Inflammatory bowel disease (ulcerative colitis) simulating/masquerading as acute appendicitis. Int J Res Rev. 2016; 3(9):43-45.

\*\*\*\*\*