

Adenomatous Polyposis Coli in North-Western Nigeria: A Rare Case

Bashir B. M¹, Saddiku M. S², S. P Agbo¹, S. A Maiyaki³, A. M Koko¹

¹Department of Surgery, ²Department of Pathology, ³Department of Medicine, Usmanu Danfodiyo University Teaching Hospital, Sokoto.

Corresponding Author: Bashir B. M.

Received: 17/08/2016

Revised: 31/08/2016

Accepted: 01/09/2016

ABSTRACT

Adenomatous Polyposis is a rare disease in Africa, it occur more common in developed countries. The most common symptoms are bloody rectal drainage, abdominal pains, and diarrhea which can mimic other intestinal conditions. Familial Adenomatous Polyposis (FAP) is pre-cancerous with 100% risk of malignancy. It requires early detection and treatment. We are reporting an interesting case of a young woman presenting with chronic diarrhea, and was diagnosed to have Adenomatous Polyposis.

Key words: Adenomatous Polyposis (AP), Familial Adenomatous Polyposis (FAP).

INTRODUCTION

Familial adenomatous polyposis is an autosomal dominant inherited cancer-predisposition syndrome that is causally linked to the adenomatous polyposis gene located on chromosome 5q2³. The mutation in APC gene accelerates the initiation of the adenoma- carcinoma sequence, resulting in the development of numerous adenomatous polyps at a young age. [7] Familial adenomatous polyposis is defined as an inheritable condition in which the large intestine contains adenomatous polyps typically more than 100. [1] The incidence of familial adenomatous polyposis in developed countries is 1: 10, 000- 1: 30, 000. [2] It is more common in males than females with age of onset of 15 years. [2] Before this age the disease is reported to be asymptomatic and with no macroscopically visible polyps. [2] FAP is precancerous with 100% risk of malignancy. Extra colonic site involvement is found in 40-90% of patients, where polyps have been seen in the antrum,

duodenum, periampullary region and the ileum. [3,5] Colorectal polyps may also coexist with gall bladder polyps. [11] The diagnosis of FAP is made by the presence of 100 or more colonic polyps in a partially expressed phenotype and 1000 to 5000 polyps in fully expressed phenotype. The disease may occur following spontaneous mutation in 20-30% of patients, who therefore show a negative family history. [2]

The natural history of FAP includes the development of adenomatous polyps in the late teens to early twenties. Symptoms typically develop by the third decade of life. The most common symptom is bloody rectal drainage; however complaints of abdominal pain, tenesmus, diarrhea and obstruction have been noted. [1] Often disease may be asymptomatic in the absence of malignant transformation of colonic polyp. In untreated cases, death usually occurs at a mean age of 42 yrs, which is 20 yr earlier than the mean age of death from sporadic colorectal carcinoma. [1] Although most patients with

FAP will have a known family history of the disease, up to 25% present without other affected family members. [4]

CASE REPORT

A 35 yr-year old woman was admitted with an 8-month history of passage of mucoid diarrhoeal stool, weight loss and generalised body weakness. Has no known family history of similar problem. On physical examination, the patient was weak and pale. Her abdomen was soft, non tender, non-distended, without organomegaly, masses or ascites and rectal examination revealed normal findings. Laboratory investigation demonstrated haemoglobin of 7gm/dL and haematocrit of 21 %, stool occult blood test was positive and carcinoembryonic antigen was normal (1.0ng/ml), both serum electrolytes and liver function tests were normal. Colonoscopy revealed multiple polyps, involving whole colon sparing rectum and histology confirmed adenomatous polyposis coli. She was optimised and subsequently had total colectomy and ileorectal anastomosis. Patients recovered well and discharge home to be followed in out-patient clinic. Family members were counseled for screening.

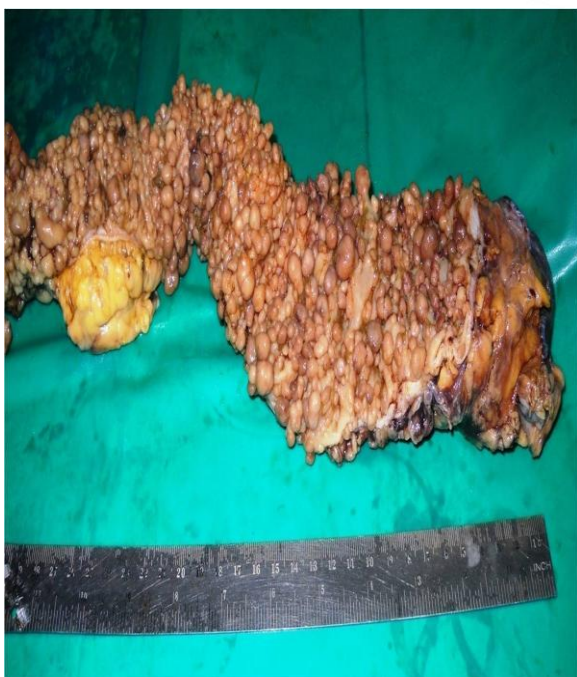

Fig. 1: Gross Specimen with numerous Polyps.

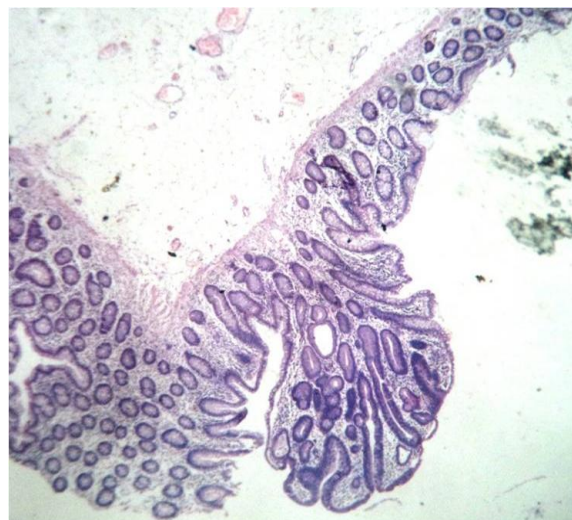


Fig. 2 (a): Histologic Slide of Adenomatous Polyp

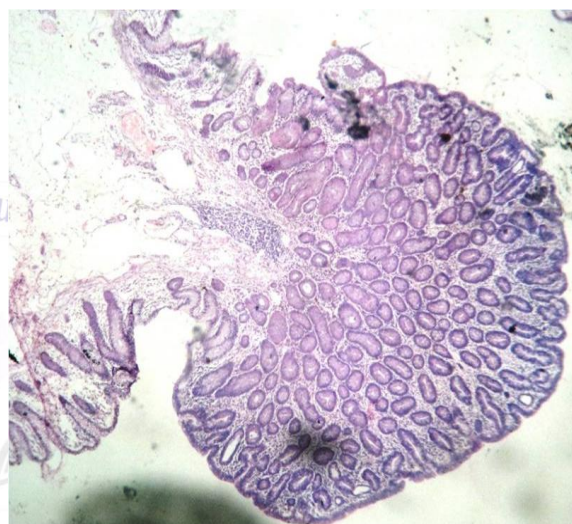

Fig. 2 (b): Histologic Slide of Adenomatous Polyp

DISCUSSION

The first known description of multiple colorectal polypoid lesions dates from 1721 and was published in Latin by Menzel in a medical journal from Berlin, Germany. He drew an 18-cm colonic segment with 15 wart-like mucosal and submucosal excrescences at a post-mortem of a 15-year-old boy who died of dysentery. [5] Sklifasowski published the first histologically verified case of adenomatous polyposis in Russia in 188; He described a 51 year-old merchant with a history of 7 years of bloody diarrhoea and abdominal Pain. [1,5] In 1882, attention would also turn toward the inherited predisposition for what Cripps termed “disseminated polypus of the rectum” on the basis of 20-30 adenomas in two affected siblings, aged 17 and 19, both

of whom experienced rectal haemorrhage from prepuberty. [5] In 1925, Lockhart-Mummery stated that adenomas should be distinguished from inflammatory polyps, and that the hereditary factor in FAP is not cancer, but multiple adenomas having a marked tendency to undergo malignant change. On the basis of his early polyposis series the polyposis registry was established at St. Mark's Hospital as the first in the world. [5] The first 3-stage proctocolectomy was performed in 1924 by Coffey in 1951, Gardner described what was later termed "Gardner's syndrome" including colorectal adenomas, desmoid tumours, bone tumours, and soft tissue tumors. [4,5] Dukes was the first to describe the psychological aspects of the disease in 1952 and stated that "in the study of polyposis scientific enthusiasm must always be tempered with sympathy and tact." [4]

FAP has been very rare in Africa; this is said by many to be the reason why the incidence of colorectal cancer in Africans is much less than in Europe or United States of America. [6,9,10] The above case is one of the few reported in Nigeria. The first documented case of FAP in the west African sub-region was that of a 16yr-old girl who presented with rectal prolapsed, bleeding per rectum, diarrhea and severe weight loss of 13 years duration [6,8] FAP presents challenges in the African setting; colonoscopy not readily available in many centres so probably many cases will go undiagnosed. [2] Double contrast barium enema may be more available but tiny polyps in asymptomatic cases are difficult to pick.

CONCLUSION

Colonoscopy has advantage that when biopsies are taken, even microscopic polyps may not be missed. This case along

with other previously reported cases of FAP, suggests a requirement for long term surveillance of patient and her family members. She is been treated for chronic diarrhea and the report was made to highlight the need for colonoscopy in the developing world.

REFERENCES

1. Derrick Beech, Familial Adenomatous Polyposis (FAP): A case report and a review of literature, Natl Med Assoc 2001; 93:20813.
2. Sebbaale A K, Obote, Familial Adenomatous Polyposis Coli: A case report, East and Central African Journal of surgery vol 9 no.2-Dec 2004.
3. Sabiston Textbook of surgery: The biological Basis of modern surgical practice 1997, WB. Saunders Company, chp.32 section VI.
4. Schwartz's Manual of surgery F Charles Brunicaudi, 8 ed. Chp.28 pg.754.
5. S. bull. The history of Familial Adenomatous Polyposis: Familial Cancer (2006) 5:213-220.
6. OB Alese and D O Irabor, Adenomatous Polyposis Coli in Elderly Female Nigerian-Ghana Medical Journal, 2009 Sep; 43 (3):139-141.
7. Kyu YK, Retrogression of colonic adenomas after treatment with Sulindac in FAP: A case report with 2yr follow-up without a prophylactic colectomy; Ann coloproctol 2014 Aug; 30(4):201-204.
8. Udofot, SU. Ekpo, Khalil MI, Familial Polyposis coli a usual case in West African, Central African Journal of Medicine, 1992 Jan. 38 (1): 44-48.
9. Irabor, DO. Colorectal cancer in West Africa, some considerations on its relatively lower incidence compared with Caucasians Pak Journal of Medical Sci. 2008; 24: 331-335.
10. Irabor D, Adedeji OA. Colorectal Cancer in Nigeria: 40 years on. A review European Journal of Cancer 2009; 18:110-115.
11. Yasuhisa Mori, Nohutaka Matoyoshi: Rare combination of FAP and Gallbladder Polyps; world Journal of Gastro 2014 Dec, 20 (46) 17661-17665.

How to cite this article: Bashir BM, Saddiku MS, Agbo SP et al. Adenomatous polyposis coli in North-Western Nigeria: a rare case. Int J Res Rev. 2016; 3(9):40-42.
