

Case Report

# Adrenal Myelolipoma Presenting As Incidentaloma - A Rare Case Report

Ankita Goel<sup>1\*</sup>, Parul Jain<sup>2\*\*</sup>, Vissa Shanthi<sup>3\*</sup>, Syam Sundar Byna<sup>4\*</sup>

<sup>1</sup>Assistant Professor, <sup>2</sup>Senior Resident, <sup>3</sup>Professor, <sup>4</sup>Associate Professor,  
\*Department of Pathology, \*\*Department of Endocrinology,  
Narayana Medical College and Hospital, Nellore, Andhra Pradesh, India.

Corresponding Author: Ankita Goel

Received: 31/05/2016

Revised: 10/06/2016

Accepted: 16/06/2016

## ABSTRACT

Myelolipoma is an uncommon asymptomatic, small, non-functional benign tumor composed of mature adipose tissue & hematopoietic elements and is most commonly found in the adrenal gland. We report a case of adrenal tumor in 53 year old male, which was discovered incidentally by computed tomographic imaging technique followed by surgical excision because of large size. The definite diagnosis of myelolipoma was suggested only by histopathological examination because of unique microscopic features.

**Key words:** myelolipoma, incidentaloma, adrenal gland.

## INTRODUCTION

Myelolipoma is rare, benign tumors, mostly found in the adrenal gland, although extra-adrenal locations like retroperitoneum, thorax and pelvis are also known. They are composed of variable amount of mature adipose tissue and hematopoietic cells including megakaryocytes. [1]

Myelolipomas are usually asymptomatic and are found incidentally (incidentaloma) at autopsy or non invasive imaging studies done for other reasons. The incidence of myelolipoma presenting as adrenal incidentaloma varies between 7-15%. Malignant transformation in myelolipoma is very rare but hemorrhagic complications like extra-peritoneal or intra-tumoral hemorrhage can occur. Laparoscopic excision of tumor is recommended. [2]

In this article we present a case report of a 50 year old male with an incidentally detected adrenal myelolipoma.

## CASE REPORT

A 53-year-old male patient presented to general surgery OPD, Narayana medical college and hospital, Nellore, India with dull aching intermittent pain in right lumbar region since three months relieved by analgesics. No hematuria, dysuria, pyuria or lower urinary tract infection was present. Bowel habits were normal. No history of prior surgery and comorbid conditions was present. Patient is chronic smoker since 20 years.

On clinical examination he was found to be pre-hypertensive (BP: 130/90mmHg.) No postural hypotension, palpitation and Cushing's features were present. There was no other significant finding clinically.

Routine hematological parameters like hemoglobin, complete blood count, peripheral smear were within normal limits. Blood glucose, urea, creatinine, sodium, potassium and bicarbonate levels were normal.

Urinary adrenaline, noradrenalin, dopamine and vanillyl mandelic acid were within normal limits. Plasma biochemistry showed normal levels for free cortisol, metanephrine and nor-metanephrine. Thus proving that adrenal mass is non functional.

Computerized tomography (CT) scan showed a well outlined mass measuring 7.8 x7.1 cm with fat densities, in the suprarenal region of right kidney. The Hounsfield unit (HU) of the fat containing areas was -81. Right kidney was pushed 11mm downward by the tumor. Left kidney was normal. Possibility of lipoma and fat-rich adrenal adenoma was suggested.

Based on CT findings patient was referred to urology department where right laparoscopic adrenalectomy was performed under general anesthesia. Post operative period was uneventful.

**Gross:** Right adrenalectomy specimen measuring 8 x 5 x 4 cm, grayish brown in color and encapsulated was received by department of pathology, Narayana medical college, Nellore, India. External surface was covered by fat. Cut section showed yellowish fatty areas with multiple grayish brown hemorrhagic areas (figure 1).

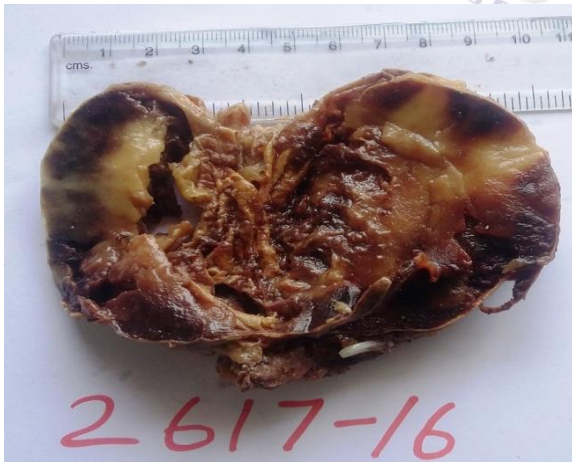

Figure 1: Cut section of specimen showing dark (myeloid) areas with yellowish (fatty areas).

**Microscopic examination:** revealed adrenal tissue at the periphery (figure 2) beneath which was seen a mass composed of large areas of mature adipose tissue along with scattered areas of hematopoietic tissue containing erythroid, lymphoid, granulocytic and megakaryocytic elements

(Figure 3 & 4). There was no evidence of any other associated elements like pheochromocytoma, adreno-cortical hyperplasia or adenoma on microscopic examination. A histological diagnosis of myelolipoma was suggested.

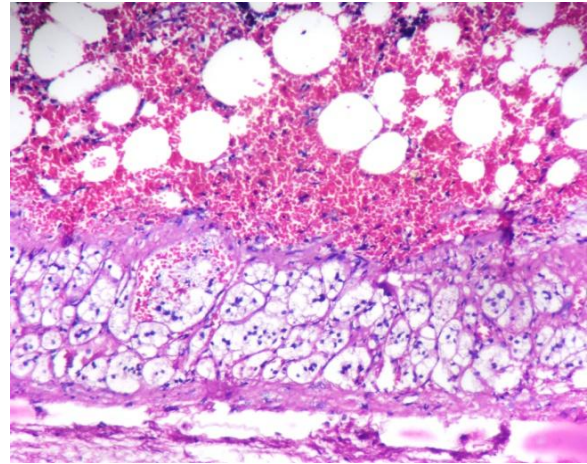


Figure 2: Showing myelolipoma with peripheral normal adrenal cortical cells (hematoxylin and eosin, 10x)

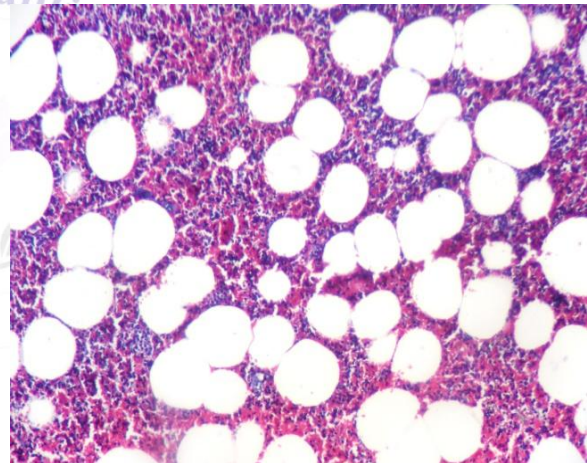


Figure 3: Showing mature adipose tissue with hematopoietic cells (hematoxylin and eosin, 10 x).

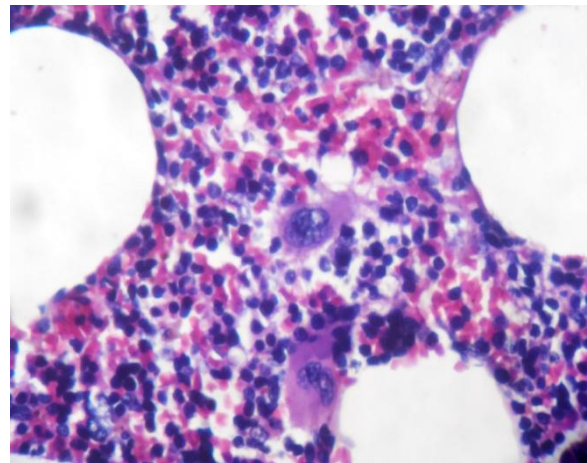


Figure 4: Showing fat globules & hematopoietic cells including megakaryocytes (hematoxylin and eosin, 40x)

## DISCUSSION

Adrenal myelolipoma is an unusual type of the adrenal incidentaloma composed of mature adipocytes and hematopoietic elements. [2] Edgar Von Gierke, a German pathologist first described this lesion in 1905 but it was not until 1929, that the lesion was given its name, "myelolipoma", by Charles Oberling, a French pathologist. [3]

Most of these tumors are small in size, asymptomatic and have no endocrine function. However pain can occur in some case because of mechanical compression from a large tumor, retroperitoneal hemorrhage or tumor necrosis. Very rarely, these tumors are functional and coexist with primary aldosteronism, congenital adrenal hyperplasia (CAH), pheochromocytoma and Cushing's syndrome. [2]

The incidence of adrenal myelolipoma varies from 0.08% to 0.4 %. It presents with equal frequency in male and female, and are commonly diagnosed in the 5<sup>th</sup> to 7<sup>th</sup> decade. In the majority of cases it is unilateral, however can be bilateral also. It can be found coincidentally with other lesions in the adrenal glands (as "collision tumors"), such as adenomas, pheochromocytoma or metastases. It varies in size, from a few centimeters to more than 30 cm (commonly 2-10 cm in diameter). [3]

The present case report shows a right sided adrenal incidentaloma unassociated with other lesion in adrenal gland in 50 years old male with non specific intermittent pain in right flank. Size of the tumor is 8cm.

The pathogenesis of myelolipoma is unspecified but various theories are suggested. According to D. C. Collins, myelolipoma depicts a site of extramedullary hematopoiesis. The most widely believed theory is the study of the natural history of adrenal myelolipoma by Meaglia and Schmidt in 1992. According to it, myelolipoma is due to metaplasia of the reticuloendothelial cells of blood capillaries in the adrenal gland in reaction to stimuli such as necrosis, infection, stress or long-term ACTH stimulation. [4] Chang et al

discussed a case of adrenal myelolipoma with a translocation t (3; 21) (q25; p11). A similar mutation, t (3; 21) (q26; p11), is found in hematopoietic neoplasms, such as myelodysplastic syndromes & chronic myeloid leukemia, suggesting that myelolipoma is a derivative from misplaced hematopoietic cells. [5]

Incidental detection of non-functioning asymptomatic adrenal myelolipoma is reported by many authors in English literature. [4-8]

The differential diagnosis of myelolipoma include angiomyolipoma (in extremely vascular tumors), lipoma, liposarcoma and extramedullary hematopoiesis in adrenal gland.

1. Angiomyolipoma contain vascular and leiomyomatous elements in addition to adipose tissue.
2. Extramedullary hematopoiesis is usually secondary to a primary hematologic disorder (such as hemolytic anemia) and is distinguished from myelolipoma by presence of reticular sinusoids or bone spicules like bone marrow and involvement of other organs of hematopoiesis (liver, spleen). Pseudocapsule and lipomatous elements are typically absent.
3. Lipoma is composed of benign adipocytes with absent hematopoietic elements.
4. Liposarcoma contain malignant lipoblast without blood cells.

**Diagnosis:** CT scan is the primary adopted method for evaluating the abdomen if there is a suspicious mass or lesion, as it is readily available, and provides spatial resolution and differentiates tissues by different HU values. It shows the negative density of the fat in the adrenal mass. However, the enhancement of the soft-tissue elements is not specific, raising the problem of a precise characterization of the lesion. [9] In the present case report CT scan findings were suggestive of benign adrenal tumor without any definitive diagnosis. Benign lipomatous lesion and malignant lipomatous lesion were not distinguished by CT scan.

Histopathological examination provided a definitive diagnosis of myelolipoma.

**Management:** According to the national institutes of health state of the science conference lesions >6 cm should be surgical excised. Regular follow up of lesions of <4 cm. The surveillance could be stopped if there is no evidence of an increase in the size of the tumor on two consecutive images at 6-month intervals with no evidence of abnormal hormonal secretion. <sup>[10]</sup>

Laparoscopy is the standard surgical procedure recommended for tumor excision because of minimal blood loss and postoperative complications. Open adrenalectomy should be performed for tumors >10 cm or malignant tumors requiring a wide resection with satisfactory margins, to eliminate future carcinogenic development. <sup>[9]</sup> In the present case report, patient was asymptomatic but keeping in view the size of the lesion (8cm) laproscopic right adrenalectomy was done.

#### REFERENCES

1. Kenney PJ, Wagner BJ, Rao P, Heffess CS. Myelolipoma: CT and pathologic features. *Radiology*. 1998; 208:87-95.
2. Shanthi V, RAO NM, Chaitanya B, Krishna BA, Mohan KV. Adrenal myelolipoma: A rare case report. *Journal of Dr. NTR university of health sciences* 2012;1(2):124-6
3. Hakim A, Rozeik C. Adrenal and Extra-adrenal Myelolipomas - A Comparative Case Report. *Journal of radiology case reports*. 2014; 8(1):1-12.
4. Doddi S, Singhal T, Leake T, Sinha P. Management of an incidentally found large adrenal myelolipoma: a case report. *Cases Journal*. 2009; 2:8414.
5. Chang KC, Chen PI, Huang ZH, Lin YM, Kuo PL. Adrenal myelolipoma with translocation (3;21)(q25;p11) *Cancer Genet Cytogenet*. 2002; 134(1):77-80.
6. Al Harthi B, Riaz MM, Al Khalaf AH, Al Zoum M, Al Shakweer W. Adrenal myelolipoma a rare benign tumour managed laparoscopically: Report of two cases. *Journal of minimal access surgery*. 2009; 5(4):118-20.
7. Lam KY1, Lo CY. Adrenal lipomatous tumours: a 30 year clinicopathological experience at a single institution. *J Clin Pathol*. 2001; 54(9):707-12.
8. Gurbuz E, Sayar H, Bakaris S, Inci MF. Adrenal myelolipoma's connection with adenoma in the same adrenal gland. *BMJ Case Reports* 2013;255-8
9. Khater N, Khauli R. Myelolipomas and other fatty tumours of the adrenals. *Arab Journal of Urology*. 2011; 9(4):259-65.
10. Grumbach MM, Biller BM, Braunstein GD, Campbell KK, Carney JA, Godley PA et al. *Ann Intern Med*. 2003; 138(5):424-9.

How to cite this article: Goel A, Jain P, Shanthi V et al. Adrenal myelolipoma presenting as incidentaloma - a rare case report. *Int J Res Rev*. 2016; 3(6):39-42.

\*\*\*\*\*