

Case Report

Testicular Filariasis Mimicking As Testicular Tumor - Case Report

B. Syam Sundar¹, Vissa Shanthi², Nandam Mohan Rao¹, Bhavana Grandhi³,
Ankita Goel³

¹Associate Professor, ²Professor, ³Assistant Professor,
Department of Pathology, Narayana Medical College, Nellore (A.P), India

Corresponding Author: B. Syam Sundar

Received: 23/04/2016

Revised: 03/05/2016

Accepted: 06/05/2016

ABSTRACT

Filariasis is a major public health problem. It is a parasitic infection most commonly caused by *Wuchereria bancrofti*. The clinical picture of the disease depends on duration of the disease, infection in the human host and worm load. We present an unusual case of testicular filariasis who presented with scrotal swelling.

Key words: filariasis, testis, *Wuchereria bancrofti*.

INTRODUCTION

Lymphatic filariasis is a major health problem in India with majority of them asymptomatic. In tropical countries like India, genital filariasis usually presented as secondary vaginal hydrocele with epididymo orchitis. Isolated testicular involvement is very rare. ⁽¹⁾ The disease has been targeted by world health organization for global elimination by 2020. One of the major public health and socioeconomic problem in tropical and subtropical countries is lymphatic filariasis. This is caused by nematode *Wuchereria bancrofti*. ⁽²⁾ Secondary bacterial infection or obstructions of lymphatic channels usually lead to formation of hydrocele. ⁽³⁾ It is estimated that approximately around 120 million people are affected in at least 80 countries both in tropic and sub tropics. We present an unusual case of testicular filariasis, who presented with scrotal swelling, testicular involvement is rare. The discovery of an adult's worm in the

testicular tunica has reported very few cases previously. Histopathologies confirm the diagnosis of testicular filariasis.

CASE REPORT

A 45 years male was admitted to the department of surgery with complaints of swelling in his right testis since one month and associated with pain. He also complained of fever since one week. There was no history of trauma to testis. On examination of the genitalia revealed mild enlargement of right testis with ill defined tender swelling of size 3 cmx2cm. The epididymis and spermatic cord were normal to palpation. The left testis and cord were normal. Complete blood count and his chest x ray were normal. There was no inguinal lymphadenopathy and rest of the genital examination and abdominal examination was unremarkable. On ultra sound examination of scrotum reveal normal sized right testis with multiple cystic areas and linear hypoechoic areas within the testicular parenchyma and similar hypo echoic lesion

noted in right epididymis. Clinical diagnosis was right inguinal hernia with testicular tumor. The patient underwent a right inguinal orchidectomy with mesh hernioplasty. The specimen sent to histopathology department for further evaluation. Macroscopic findings of specimens shows testis, epididymis measuring 6x3x2 cm, cut section of testis revealed grey white areas with tiny cystic areas. Epididymis and cord were normal. Histopathological examination revealed structure of testis consisting of atrophic seminiferous tubules and some them hyalinized. Few tubules were showing maturation arrest. Interstitium shows Leydig cell hyperplasia with areas of fibrosis and congested blood vessels. One focus shows cut section of adult filarial worm. Histopathology confirmed the diagnosis of testicular filariasis. Post operative state was uneventful and four months follow up of the case showed good recovery.

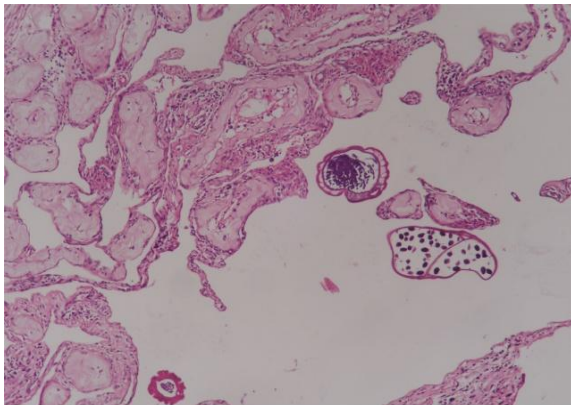


Fig 1: Hyalinized seminiferous tubules and adult filarial worm. (H & E, X100)

DISCUSSION

The filarial infection is prevalent in both the urban and rural areas. Adult worms found in the lymphatic vessels and lymph nodes of humans only and there is no animal reservoir. (4) Genital filariasis manifest in several ways like acute manifestations and chronic manifestations. Acute manifestations are epididymo orchitis, funiculitis and chronic manifestation benign hydrocele, lymph scrotum, lymph varix, filarial penis and chiluria. In tropical countries presented like India, genital

filariasis usually presented as secondary vaginal hydrocele with epididymo or orchitis. Isolated testicular involvement is very rare. (1) Morbidity due to genital filariasis is mostly caused by hydrocele. (2) Bacterial infection plays a key role in causing acute attacks which can prevent by hygiene practices. The formation of hydrocele in wuchereria bancrofti infection is a result of inflammation of the tunica vaginalis or impaired lymphatic drainage through the spermatic cord and adult worms reside in lymphatic vessels, local host inflammations induced by the parasite or secreted worm products themselves may cause lymphatic dysfunction with formation of hydroceles. (5) Filariasis is transmitted by culex mosquito. There are eight filarial species causing infection in man. Traditionally the term filariasis refers to lymphatic filariasis which is caused by Wuchereria or Brugia species. (6) Based on literature Wuchereria bancrofti can produce variable lesions by involving the lymphatics in soft tissues, lung, breast, thyroid, bronchoalveolar fluid, gastric brushing and testis. Diagnosis of filarial infection depends on demonstration of microfilaria in peripheral smear examination and detection of antigens and antibodies by immunological assay can be used. The circulating filarial antigen is the gold standard for detecting wuchereria. (2a). Imaging technique like ultra sonography and nuclear magnetic resonance spectroscopy can also be used for detecting filarial worms. Literature revealed reported cases that yield microfilariae in fine needle aspiration cytology from lymph nodes and other various sites. (7) The diseases often lead to orchidectomy as it clinically simulates malignancy. (8) Testicular neoplasms clinically mimic filariasis and tuberculosis. Histopathological examination is required to exclude all possibilities. Microscopic examination of tuberculosis of testis shows structure of testis with granulomas consisting of caseous necrosis surrounded by epithelioid cells, lymphocytes and langhans giant cells.

Microscopic features of malignancy of testis shows loss of architecture which is replaced by pleomorphic tumor cells have increased N: C ratio and moderate cytoplasm. The other diagnostic tests for filariasis are noncontributory histopathological examination serves as a useful diagnostic modality for correct diagnosis. Microscopic features of Testicular filariasis shows cut section of the worm surrounding tissue having inflammatory cells, predominantly eosinophils. In chronic conditions worm is surrounded by dense fibrous tissue with paucity of inflammatory cells. In our case there was increased fibrosis of tunica with hyalinized seminiferous tubules in testis. Some rare manifestations of filarial presentations were suggested in review of literature. These are filarial orchitis presenting as scrotal abscess by Ezhil Arasi et al ⁽⁹⁾ and another is Testicular filariasis masquerading as a testicular tumor-Case report with review of literature by P Joshi et al. ⁽¹⁰⁾ In one case report by Joseph et al, ⁽¹¹⁾ Association of filarial worm infestation with tuberculosis orchitis was reported. Genital manifestation of the disease is common in filariasis through documentation of testicular filariasis is rare.

CONCLUSION

The person with testicular swelling should warrant a suspicion of malignancy. Histopathological examination is useful diagnostic modality as in our case to exclude malignancy and tuberculosis.

REFERENCES

1. Barreto SG, Rodrigues J, Pinto RGW. Filarial granuloma of the testicular tunic

- mimicking a testicular neoplasm: a case report. *J Med Case Reports* 2008; 2:321.
2. Shah AP, Mulla SA. Circulating filarial antigen in serum and hydrocele fluid from individuals living in endemic area for Bancroftian filariasis. *Indian Journal of microbiology*.2007; 25:253-255.
3. Iturregui-pagan JR, Fortuno RF, Noy MA. Genital manifestation of filariasis. *Urology* 1976; 8:207-9N.
4. Chaubal NG, Pradhan GM, J Chaubal JN, Ramani SK. Dance of live adult filarial worms is a reliable sign of scrotal filarial infection. *J Ultrasound Med* 2003; 22:765-9.
5. Dreyer G, Noroes J, Figueredo - silva J, Piessens WF. Pathogenesis of lymphatics disease in filariasis: a clinical perspective. *parasitol TODAY*.2000;16:544-8.
6. David TJ, William AP Jr; *Medical Parasitology*, 9th edition, 2006; 359-362.
7. Varghese TR, Raghuvver CV, pai MR, Bansal R; *Microfilariae in cytological smears. A report of six cases. ACTA CYTOL*, 1996; 40:299-301.
8. Johnson WD Jr, Johnson CW, Lowe FC. Tuberculosis and parasitic diseases of the genitourinary system. In: Walsh PC, Retik AB, Vaughan ED Jr, Wein AJ, Editors. *Campbells urology*, vol.1, 7th ed. Philadelphia: Saunders; 757-66.
9. Ezhil Arasi N, Neelima. G, Manimekhala. P, Annunay. J, Akhila. P, Nagesh. Filarial orchitis Mimicking as Scrotal Abscess-A case Report: *Sch J Med Case Rep*, August 2015; 3(8A):738-739.
10. P Joshi, S Shivde, M Mandolkar. Testicular Filariasis Masquerading as a Testicular Tumor-Case Report with Review of literature: *The internet journal of surgery* .2009, vol 23 number1.
11. Joseph paul, Sriram Krishnamoorthy, Marie Teresa, and Santosh Kumar. Isolated tuberculosis orchitis: A mimicker of testicular malignancy: *Indian J Urol*.2010 April-Jun; 26 (2): 284-286.

How to cite this article: Sundar BS, Shanthi V, Rao NM et al. Testicular filariasis mimicking as testicular tumor - case report. *Int J Res Rev*. 2016; 3(5):82-84.
