

Spectrum of Liver Pathology at Autopsy

Umesh Babu R¹, Gayathri B.N², Harendra Kumar M.L³

¹Professor, Department of Forensic Medicine and Toxicology, Sri Devraj Urs Medical College Tamaka, Kolar, Karnataka, India

²Associate Professor, Department of Pathology, Kodagu Institute of Medical Sciences, Madikeri, Kodagu, Karnataka, India

³Professor, Department of Pathology, Sri Devraj Urs Medical College, Tamaka, Kolar, Karnataka, India

Corresponding author: Umesh babu R

Received: 20/02/2015

Revised: 14/03/2015

Accepted: 24/03/2015

ABSTRACT

Background: Most of the chronic liver diseases, even in advanced stages, may cause no prominent clinical signs or symptoms. They either go undiagnosed or are found incidentally during general health check-ups, investigations for other diseases, surgery, or autopsy. The underlying causes of chronic liver diseases vary in different geographic areas and are based on various factors such as socioeconomic status, life style, diet, local or regional infections, and other endemic diseases.

Objectives: To study the spectrum of liver pathology at autopsy

Method: We collected liver samples from 105 cases for histopathological study. Information regarding age, sex, marital status, place, food habit, alcoholic usage and previous history of any disease particularly liver disease etc., were collected from the first degree of the deceased during autopsy in which ever cases possible. Bits from right and left lobe and one bit from deeper areas of the liver was taken. Processed tissue sections were stained with haematoxylin and eosin. The cases were analysed by descriptive statistics.

Results: Satisfactory tissue samples for histologic evaluation were available in all the cases with a mean age of 39 years. Normal histology was found in 5 (4.7%) cases. Important findings included steatosis in 24 (22.8%), steatohepatitis in 37 (35.2%), chronic hepatitis in 22 (20.9%), congestion in 10 (9.5%), hepatic granulomas in 4 (3.8%) cases. Causes of death were: Road traffic accident (41.9%), poisoning (24.8%), burns (6.7%), snake bite (5.7%), fall from tree/wall (2.9%).

Conclusion: Silent diseases of the liver are not uncommon. Steatohepatitis and chronic hepatitis comprise a significant finding in our locality.

Key words: autopsy, liver disease, steatohepatitis

INTRODUCTION

Liver is vulnerable to a wide variety of metabolic, toxic, microbial and circulatory insults. In some instances, the disease is primary while in others the hepatic involvement is secondary to cardiac

de-compensation, alcoholism or extrahepatic infections. Quite rightly liver is called as “the custodian of milieu interior”. Autopsy study is useful to monitor the cause of death and to plan medical strategy. ^[1]

MATERIALS AND METHODS

105 specimens of liver were received from Forensic Department of cases subjected for clinical autopsy, or medico-legal autopsy. Liver specimens received either as a part of examination of multiple viscera, or whole liver taken out from the deceased was examined. Information regarding age, sex, marital status, place, food habit, alcoholic usage and previous history of any disease particularly liver disease etc., were collected from the first degree of the deceased during autopsy in which ever cases possible. Consent for examination of liver was taken from next of kin. Samples from grossly visible lesions were studied and random bits from right lobe, left lobe, caudate and quadrate lobe and one bit from deeper areas of the liver was studied. All the bits were fixed in 10% formalin. Processed tissue sections were

stained with Haematoxylin and Eosin according to standard procedures. Special stains were performed whenever necessary. The cases were analysed by descriptive statistics.

Inclusion criteria: Patients above 3 years on whom clinical and medico legal autopsies had been done to ascertain the cause of death.

Exclusion criteria: Autopsies on exhumed bodies.

On microscopic examination degree of steatosis, steatohepatitis and chronic hepatitis were graded as follows shown in table 1, 2 & 3:

Table 1: Grading of steatosis.

I	When micro and macrovesicular steatosis affected 5-25% of the liver parenchyma
II	When 26-50% of the parenchyma was affected
III	When 51-75% was affected
IV	When more than 75% of the parenchyma was involved

Table 2: A scoring system for steatohepatitis

Necroinflammatory grading	
Grade 1 (mild)	Steatosis (mainly macrovesicular) involving up to 66% of lobules; occasional ballooned perivenular hepatocytes; scattered neutrophils with or without lymphocytes; no or mild chronic portal inflammation
Grade 2 (moderate)	steatosis of anydegree; obvious ballooning (mainly perivenular); intralobular neutrophils, may be associated with perivenular pericellular fibrosis if evident; mild to moderate portal and intralobular chronic inflammation
Grade 3 (severe)	Panlobular steatosis; obvious perivenular ballooning and disarray; marked lobular inflammation; neutrophils may be concentrated in perivenular areas of ballooning and in areas of pericellular fibrosis if evident. Portal inflammation mild or moderate
Fibrosis staging	
Stage 1	Pericellular fibrosis in perivenular areas, focal or extensive
Stage 2	As above, plus focal or extensive Periportal fibrosis
Stage 3	Bridging fibrosis, focal or extensive
Stage 4	Cirrhosis

Table 3: A simple scoring system for chronic hepatitis

1	Grade	
	A	Portal inflammation and interface hepatitis
	0	Absent or minimal
	1	Portal inflammation only
	2	Mild or localized interface hepatitis
	3	Moderate or more extensive interface hepatitis
	4	Severe and widespread interface hepatitis
	B	Lobular activity
	0	None
	1	Inflammatory cells but no hepatocellular damage
	2	Focal necrosis or apoptosis
	3	Severe hepatocellular damage
	4	Damage includes bridging confluent necrosis
2	Stage	
	0	No fibrosis
	1	Fibrosis confined to portal tracts
	2	Periportal or portal-portal septa but intact vascular relationships
	3	Fibrosis with distorted structure but no obvious cirrhosis
	4	Probable or definite cirrhosis

RESULTS

In the present study, the age ranged from 3- 72 years. Mean age was 39 years. Majority of patients belonged to the 4th decade of life, followed by 5th decade as shown in table 4.

Table 4: Age distribution

Age groups	Number	Percentage
0-9	2	1.9
10-19	7	6.7
20-29	19	18.1
30-39	28	26.7
40-49	20	19.1
50-59	16	15.2
60-69	9	8.6
70-79	4	3.8
Total	105	100

The number of males was 69 (65.7%) and number of females was 36 (34.9%). The male to female ratio was 1.9 as shown in table 5

Table 5: Gender distribution

Age groups	Female	Male	Total Number
0-9	1	1	2
10-19	3	4	7
20-29	9	10	19
30-39	9	19	28
40-49	4	16	20
50-59	5	11	16
60-69	4	5	9
70-79	1	3	4
Total	36	69	105

Table-6 Cause of death distribution

Cause of death	Total Number	Percentage (%)
Road traffic accident	44	41.9
Poison	26	24.8
Burns	7	6.7
Snake Bite	6	5.7
Drowning	5	4.8
Hanging	5	4.8
Fall from height	3	2.9
Assault	2	1.9
Natural death	2	1.9
Pregnancy complication	1	0.9
Bee sting	1	0.9
Head Injury	3	2.9
Police custody	1	0.9
TOTAL	105	100

Table 9: Gross findings

Size	Weight	Colour	Consistency	Cut surface	Number
Increased	>N	Grey yellow	Soft	Greasy	24
Slightly Incr	>N	Red brown	Soft	Nutmeg	10
Slightly Incr	>N	Yellow green	Firm	Micronodular	02
Slightly Incr	N	Greenish Grey	Soft	Greenish	01
Normal	N	Normal	Soft to firm	Normal	68
Total					105

Also a few gross anomalies were noted, there was absence of caudate lobe in 3 cases and quadrate lobe in one case. Small nodules were seen in 3 cases. Micronodular cirrhosis was seen in two cases, Nutmeg liver was seen in 10 cases. Laceration/raw areas were seen in 8 cases with road traffic accidents. Also there were two notches on the external surface on the right lobe of liver each ms 4cm x3cm in one case could be rib impressions.

In the current study, the most common cause of death was road traffic accidents (RTA) which occurred in 44 cases (41.9%), followed by poisoning in 26 cases (24.8%) as shown in table 6

Table 7: History of alcohol and smoking

History	Number	Percentage (%)
Both smoking & alcohol	21	30.4
Alcohol	13	18.8
Smoking	10	14.4
None	25	36.2

In present study none of the female cases had history of smoking & alcohol consumption

Table 8: Liver weight and sex

Liver weight(grams)	Male	Female	Total
<1000	12	14	26
1000-1500	44	11	55
1500-2500	12	04	16
2000-2500	03	01	04
>2500	04	00	04
Total			105

55 (maximum number) livers weighed between 1000-1500 grams, followed by 26 livers <1000 grams, 16 between 1500-2500 grams, 4 livers between 2000-2500 grams and 4 > 2500 grams.

Table 10: Histopathological findings

Histopathological findings	Cases	Percentage
Steatohepatitis	37	35.2
Steatosis	24	22.8
Chronic hepatitis	22	20.9
Congestion	10	9.52
Hepatic granulomas	04	3.80
Micronodular cirrhosis	02	1.90
Bile duct hamartoma	01	0.95
Normal	05	4.76

Predominantly macrovesicular steatosis was seen with fatty cyst. Few cases had mixed steatosis, with grading of III and IV (fig 1). Diffuse congestion was seen

with, centrilobular and sinusoidal congestion and mild periportal fatty change (fig 2).

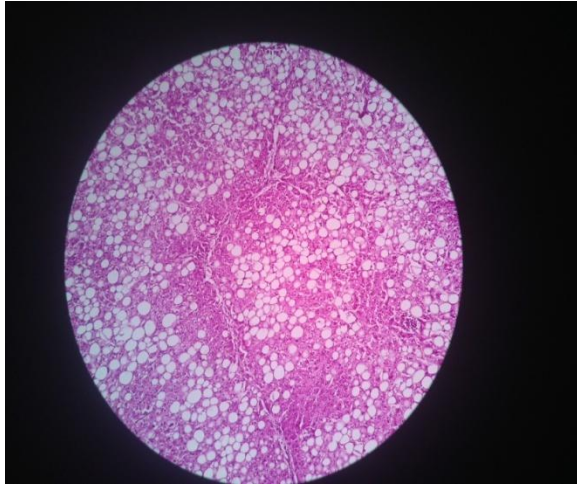


Fig 1. Microphotograph showing diffuse macrovascular steatosis. HEx100

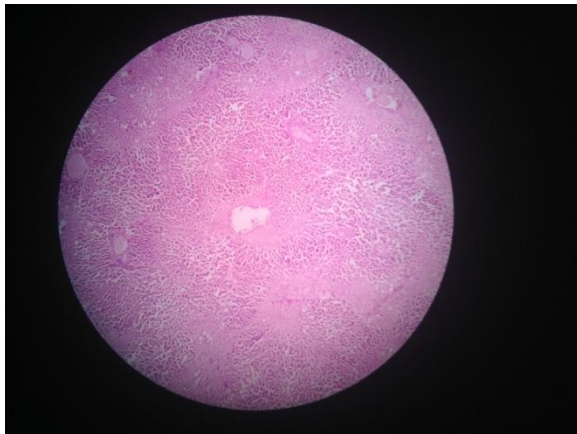


Fig 2. Microphotograph showing CVC liver with mild periportal fatty change. HEx40

The main pathological feature was steatohepatitis characterised by steatosis with hepatocellular damage, inflammation, and fibrosis (fig 3). A scoring system for steatohepatitis was done with necroinflammatory grading of Grade 1 (mild) to Grade 2 (moderate) in 30 cases. There was pericellular fibrosis in 4 cases and periportal fibrosis in 3 cases (fig 4).

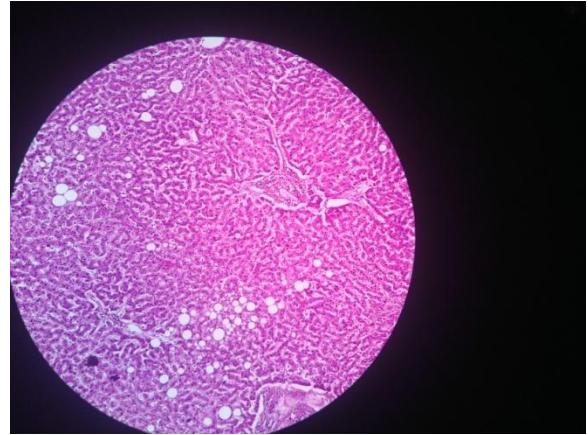


Fig 3. Microphotograph showing inflammatory infiltrate with lobular activity and foci of steatosis. HEx40

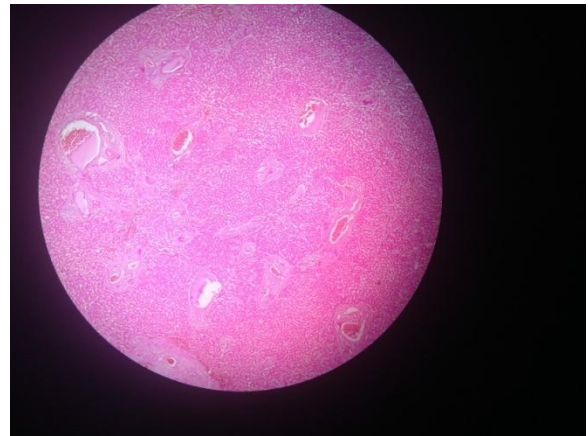


Fig 4. Microphotograph showing periportal fibrosis. HEx40

In most of our cases mildest forms of chronic hepatitis was seen, the infiltrate was confined to portal tracts and the margins of the tracts remained regular. We also encountered cases of interface hepatitis, the inflammatory cells extended from the portal tracts into the adjacent parenchyma and there was destruction of hepatocytes. Chronic hepatitis with lobular activity was noted. Clumps of inflammatory cells, extended through the parenchyma with hepatocytes loss (fig 5). A simple scoring system was done for chronic hepatitis. Most of the cases had mild to moderate portal inflammation and mild or localized interface hepatitis. There was periportal and portal – portal fibrosis in 6 cases.

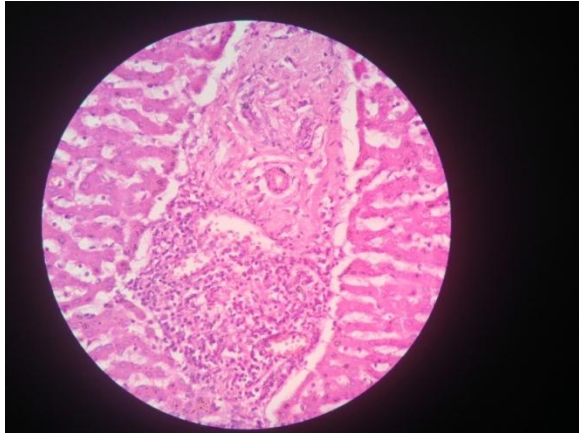


Fig 5. Microphotograph showing dense lymphocytic infiltrate in the portal tract in a case of chronic hepatitis.HEx100

Microhamartomas are multiple biliary channels lined by regular epithelium and set in a stroma of dense fibrous tissue. The lumens of the biliary structure contained inspissated bile (fig 6). They are usually found incidentally and do not normally give rise to symptoms or abnormalities of liver function. We found one case of microhamartoma in our study.

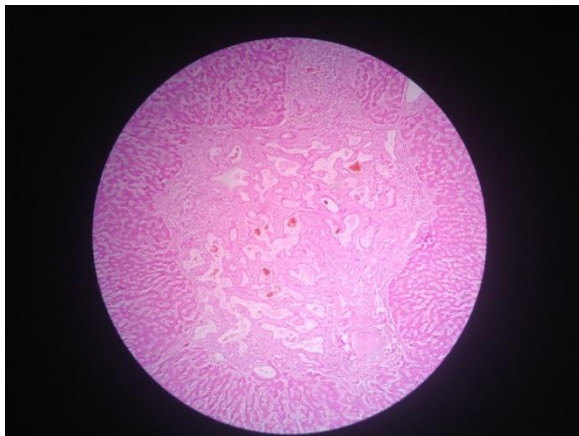


Fig 6. Microphotograph showing bile duct hamartoma.HEx100

Hepatocellular changes in cirrhosis in the form of regenerative hyperplasia were noted. In a minority of cirrhotic livers, the hepatocytes showed structural atypia and the one we encountered was large cell dysplasia. The cells were enlarged and their nuclei hyperchromatic and irregular in shape, with prominent nucleoli (fig 7). One case with

micro nodular cirrhosis had bridging fibrous septa between portal to portal tracts and central vein (fig 8).

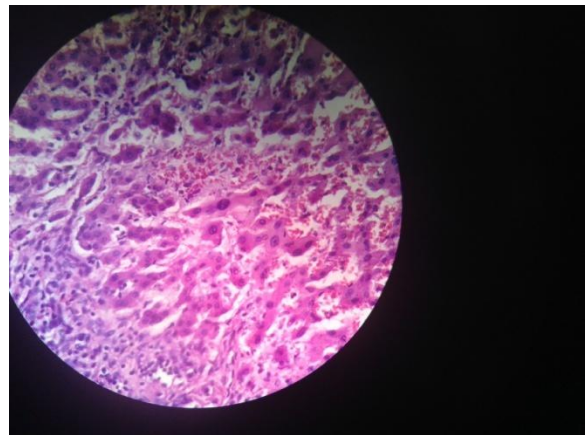


Fig 7. Microphotograph showing mild anisokaryosis of hepatocytes in a case of cirrhosis.HEx100

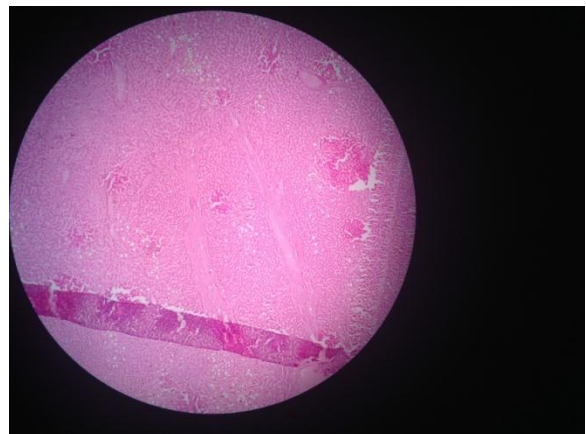


Fig 8. Microphotograph showing bridging fibrous septae between portal to portal tracts and central vein.HEx40

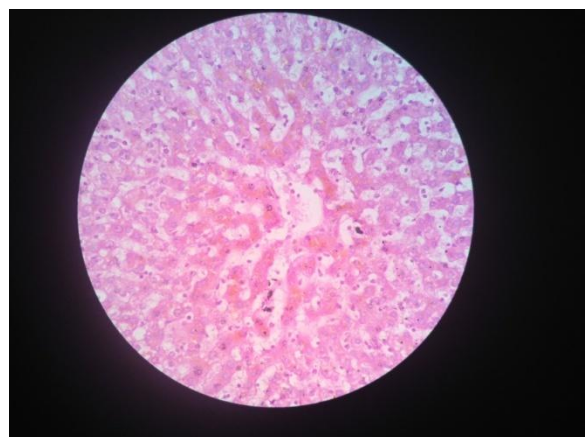


Fig 9. Microphotograph showing perivenular hepatocytes with lipofuscin pigment.HEx100

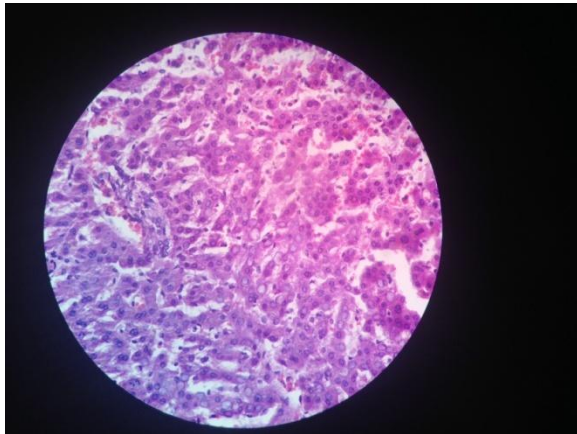


Fig 10. Microphotograph showing glycogen vacuoles within the nucleus of hepatocytes. HEx100

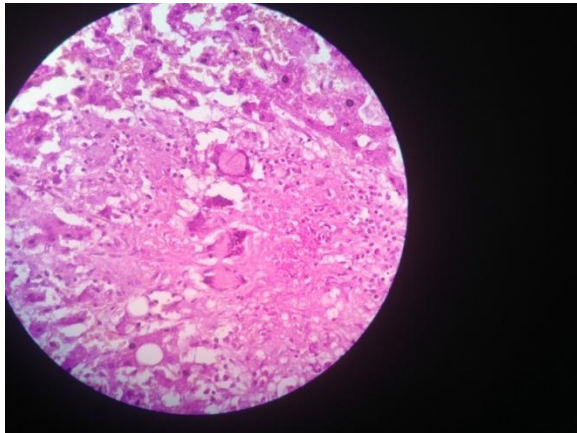


Fig 11. Microphotograph showing hepatic granuloma. HEx100

Age related changes which were observed included increased in the number of binucleated cells and increased number of lipofuscin pigment (fig 9). The pathological findings seen in burns cases included focal degeneration and necrosis of hepatocytes and proliferation of kupffer cells showing active phagocytosis. There was focal centrilobular necrosis in two of the poisoning cases. An autopsy case with history of diabetes mellitus, showed glycogen vacuoles within nucleus (fig 10).

Also there were four cases of hepatic granulomas. One was suspicious of infectious origin, probably tuberculosis, since the case had previous history of tuberculosis. On microscopy giant cells and

epithelioid cells were seen forming granuloma which was parenchymal in location (fig 11). Z-N stain for AFB was negative. Two were drug induced granulomas. One was lipogranuloma.

DISCUSSION

Alcohol abuse generally leads to the pathological distinct liver diseases; in which the most frequent hepatic lesions are fatty change, hepatitis and alcoholic cirrhosis. Person can have any one or all three can occur at the same time. [2] These diseases are presently the most common chronic liver disease problem in western and developing countries like India. Short term ingestion of up to 8 gm of alcohol generally produce mild to severe hepatic changes such as fatty liver, ingestion increase up to 160 gm or more per day for more than 20 years results in cirrhosis of liver. Occurrence is between 20-80 years but peak incidence is between 40 and 50 years as seen in our study. Apart from the major three liver diseases, chronic congestion, abscess and malignancy, yellow atrophy, infarcts and cysts can be seen as “silent liver disease” in histological findings. [3]

In the study of 4908 autopsy cases from Russia, the most frequent hepatic lesions were steatosis and inflammatory disorders. [2] Berry in 1500 autopsies performed in the coronal system in South-East London reported cirrhosis, adenoma, metastatic carcinoma, and hamartoma as the most common findings. Space occupying lesions were found in about 5% of livers in that study. [4] Another study based on analysis of 1839 necropsies in Singapore revealed that unanticipated liver lesions are common. The most important ones were cholelithiasis, cirrhosis, and primary carcinoma of the liver. [5] In our study steatohepatitis, steatosis and chronic hepatitis were frequent hepatic lesions.

Non-alcoholic fatty liver disease (NAFLD) includes a spectrum of liver diseases, ranging from simple steatosis to steatohepatitis, advanced fibrosis, and cirrhosis. Non-alcoholic steatohepatitis (NASH) represents a stage in the spectrum of NAFLD, characterized by presence of inflammation leading to gradual fibrosis in some of the affected patients. This disease is presently the most common chronic liver problem in western societies. The clinical importance of NAFLD is related to its prevalence and natural history. According to a recent study, the prevalence of NAFLD and NASH in western general population is approximately 20% and 30% respectively. But the true incidence and prevalence of NAFLD and NASH are not well known in different populations. [6]

This is partly because liver histology is required as the gold standard for precise diagnosis of this condition and the relatively invasive procedure of liver biopsy is still not considered essential for management of NAFLD by many physicians. [6]

Most of the reports about the prevalence rates of this disease are based on ultrasonographic studies and/or the presence of elevated serum levels of aminotransferases in the absence of any other known liver disease or significant alcohol consumption. [7]

The prevalence of NAFLD in patients undergoing liver biopsy for any reason ranges between 15% and 39%. This wide range is naturally related to the differences in the populations studied. In these studies, the prevalence of NASH ranges between 1.4% and 4.8%. [6]

In clinical practice, diagnostic liver biopsy is only performed for highly selected patients. Therefore, the reported rates which are based on liver biopsies cannot reflect the true prevalence of NAFLD in the general population. Autopsies, performed for those who have passed away for reasons other

than liver diseases, are certainly better sources for determination of a more reliable prevalence of NAFLD and NASH. In our study both males and females were diagnosed of having NAFLD and NASH with a prevalence of 16% and 3.2% respectively.

The particular characteristics of forensic autopsies are the relatively young age of subjects and usually better general health condition before death. Among our cases male gender was predominant, most of the subjects had no history of chronic diseases, and in more than 70% of the cases the cause of death was acute events like road traffic accident, trauma, and poisoning.

Most patients with steatohepatitis are alcohol abusers, overweight or diabetic, or have a combination of these attributes. In our study also we found the above combination in few cases. The histological lesion of NASH is rarely very severe compared with ASH. The presence of abundant neutrophils and Mallory bodies should lead to a suspicion of alcohol abuse. Glycogen vacuolation of nucleus is common in NASH. We had 35.2% of cases with steatohepatitis and 20.9% of cases with chronic hepatitis. This incidence is more compared to previous studies in the literature. [8,10]

Venous congestion of liver is terminal end stage of death seen in most of the liver autopsies. Copeland reported congestion with fatty change in 3.4% of liver autopsies of alcoholics who died suddenly. The present study revealed congestion in 9.5% cases, slightly more as compared Copeland's findings. [9]

Drugs are an important cause of otherwise unexplained granulomas. They are sometimes the only or main manifestation of a drug reaction, but can also form part of a cholestatic or hepatitis picture. The granuloma was portal in one of our case and was thought as lipogranuloma, as they were

associated with macrovesicular steatosis and fatty cyst. [8]

Bal M.S, et al study was conducted in Patiala (Punjab) observed that out of 100 cases of liver specimens fatty liver 39%, normal 30%, cirrhosis 14%, congestion 9%, hepatitis and malignancy each 3% and chronic abscess 2%; male were predominate 83% and female 17%; fatty liver seen between 41-60 years of age. [1]

In a study by Tamil Selvi et al from Salem, the most common findings were fatty changes seen in age group of 50-70 years and started with 40 years due to chronic consumption of alcohol in the population of Salem district, Tamil Nadu. [10]

In our study Steatohepatitis, steatosis and chronic hepatitis were the leading silent liver diseases compared to other studies. [1,6,10]

CONCLUSION

Histopathological study is a great value in improving the vision and diagnostic setup for clinical assessment. In this prospective study steatohepatitis and hepatitis were common silent liver diseases compared to steatosis. The incidence of liver diseases is more in males as compared to females.

REFERENCES

1. Bal MS, Singh SP, Bodal VK, Oberoi SS, Surinder K. Pathological findings in Liver autopsy. JIAFM 2004; 26(2): 55-57.

2. Voinova LV. Aetiological and nosological structure of liver diseases (on autopsy data of clinics of I.M. Sechenov Moscow Medical Academy in 1988-1997). Arkh patol. 2000; 62:45-47.
3. Saphir O. Liver 4th ed. Autopsy diagnosis and techniques by Paul B, Hobber, New York. 1958:354-65.
4. Berry CL. Liver lesions in an autopsy population. Hum Toxicol. 1987; 6:209-214.
5. Lee YS. The pattern of liver diseases in Singapore. An autopsy study. Trop Geogr Med. 1979; 31:69-74.
6. Sotoudehmanesh R, Sotoudeh M, Asgary AA, Adedi-Ardakani B, Tavangar SM, Khakinejad A et al. Silent Liver Diseases in Autopsies from Forensic Medicine of Tehran. Arch Iranian Med 2006; 9(4):324-328.
7. Hultrantz R, Glaumann H, Lindberg G, Nilsson LH. Liver investigation in 149 asymptomatic patients with moderately elevated activities of serum aminotransferases. Scand J Gastroenterol. 1986; 21:109-113.
8. Kochar N, Lowes J, Teague RH. Non-alcoholic fatty liver disease in South West England. Gastroenterology. 2002; 122:667-670.
9. Copeland AR. Sudden death in the alcoholics. Jr. Forens. Sci. Inter. 1985;29:159-159
10. Selvi RT, Selvam V, subramaniam PM. Common silent liver disease in and around of Salem population: an autopsy study. Journal of Clinical and Diagnostic Research. 2012;6(2):207-210.

How to cite this article: Umesh BR, Gayathri BN, Harendra Kumar ML. Spectrum of liver pathology at autopsy. Int J Res Rev. 2015; 2(3):79-86.
