

# Moringa oleifera L. Leaf Extract as Wound Dressing on Collagen Formation in Burn Wounds

Muhammad Mumtazmahal Al-Fathonah<sup>1</sup>, William Sutanto<sup>2</sup>,  
Ryka Marina Walanda<sup>3</sup>, Asrawati Sofyan<sup>4</sup>, Junjun Fitriani<sup>5</sup>

<sup>1,2</sup>Medical Student, Faculty of Medicine, Tadulako University, Palu, Indonesia, 94118

<sup>3</sup>Department Biochemistry, Faculty of Medicine, Tadulako University, Palu, Indonesia, 94118

<sup>4,5</sup>Department of Pharmacology, Faculty of Medicine, Tadulako University, Palu, Indonesia, 94118

Corresponding Author: Muhammad Mumtazmahal Al-Fathonah

DOI: <https://doi.org/10.52403/ijrr.20250324>

## ABSTRACT

**Background:** Burns are damage to organic skin tissue due to thermal exposure. According to Indonesia's Research Institute (2018), the incidence of burns in 2018 were 1,701 cases. The long healing time and inappropriate treatment methods are the causes of the high mortality rate of burns. The use of Bioplacenton as a conventional medicine for burns have relatively expensive prices, limited availability, and reaps pros and cons regarding its halal status. Moringa leaves can be an alternative in the treatment of burns because they contain secondary metabolism such as flavonoids, saponins, tannins, and alkaloids that can accelerate the wound healing process. The large natural potential it has is also one of the advantages in the use of Moringa leaves.

**Objective:** To determine the effectiveness of wound dressing gel extract of Moringa leaves (*Moringa oleifera* L.) on collagen formation in the healing of burns in male Wistar rats (*Rattus Norvegicus*).

**Method:** The study used a quasi-experimental design in vivo category post control group design with a quantitative approach. The research sample of 15 mice that met the inclusion and exclusion criteria were divided into 5 groups, namely the positive control group (Bioplacenton), the

negative control group (Basis gel), the Moringa extract treatment group 10%, 20%. And 40%. Results: Data analysis obtained the results of the Shapiro-Wilk test showing a sig value > 0.05 which means the data is normally distributed, then continued with the One-way ANOVA test obtained a sig value > 0.05 with the results showing no significant value between groups so that the post hoc test was not necessary.

**Conclusion:** Administration of Moringa leaf extract gel does not provide significant effectiveness on the formation of collagen density in healing burns in experimental animals.

**Keywords:** Moringa Leaves, Burn Wounds, Gel Leaf Extract

## INTRODUCTION

Burns are a condition of injury or damage to organic tissue caused by various conditions, such as excessive friction, thermal contact, radiation, chemical contact, and contact with other materials that have high temperatures. Burns are still a common health problem due to the high prevalence and mortality rates. [1,2] Based on WHO data (2018), the mortality rate of burns reached 180,000 people with 60% of them coming from Asia and Africa. Based on basic health research data (Riskesdas) (2018), in Indonesia there were increases in

the prevalence of burns in the 2014-2018 period of 35% with 1,701 burns in 2018. The most common case of burns are second-degree burns which are characterized by tissue damage to all layers of the epidermis to part of the dermis. [3,4]

The length of time for physiological wound healing required and the high costs required in the process of healing burns in terms of construction and aesthetics are causes of the high mortality rate of burns. Many errors in treatment methods can increase the probability of burn complications. [5,6] Physiologically, the healing process is divided into four main processes, namely haemostasis, inflammation, proliferation, and remodelling with collagen being an important extracellular component in the process. Collagen induces the activation of platelet aggregation for the deposition of fibrin clots at the site of injury and collagen degradation releases fragments that encourage fibroblasts and growth factor synthesis that cause angiogenesis and re-epithelialization. [7,8]

The use of conventional drugs to help the wound healing process usually uses Bioplacenton which contains neomycin sulphate and placenta extract. The use of this drug is limited due to its high price, limited availability, and reaps pros and cons related to its halal status, so it is necessary to utilize alternative treatments that are more economical and guaranteed halal. [9,10,11] Utilization of moringa leaf extract can be an alternative as it contains saponin and tannin compounds that stimulate collagen activation for wound healing. In addition, moringa leaf extract also contains other secondary metabolic compounds such as flavonoids, gallic acid, quercetin, isoquercetin which also play a role in the wound healing process. The large natural potential related to the abundant growth of moringa plants is one of the advantages in its utilization. [12,13]

This study aims to use moringa extract which will be made into a topical gel preparation. The selection of the gel preparation was chosen due to the non-

sticky and easy-to-wash nature of the gel. The higher water content in the gel preparation also provides a cooling effect when applied and facilitates the penetration of substances into the target tissue, so that it can help accelerate the healing process of burns. [14] It is considered necessary to conduct research related to the use of moringa leaf extract gel on collagen formation in healing burns.

## MATERIALS & METHODS

This study used a quasi-experimental research design in vivo category post control group design with a quantitative approach. The study assessed the effectiveness of moringa leaf extract concentrations of 10%, 20%, and 40% on collagen formation in the wound healing process compared to the positive control group (Bioplacenton) and negative control (Na-CMC gel base). The study was conducted at the Integrated Laboratory of the Faculty of Medicine, Tadulako University (UNTAD), Palu, Indonesia and the Pathology Anatomy Laboratory of Gadjah Mada University (UGM) in July-September 2024. All of this research obtained permission to implement from the Medical and Health Research Ethics Committee of Tadulako University based on a research ethics feasibility letter number: 58/3/UN.281.30/KL/202.

The samples used in this study were male Wistar rats (*Rattus norvegicus*) that met the inclusion and exclusion criteria, namely: healthy condition, weight 200-350gr, age 2.5-3 months, rats experienced IIA degree burns during burn induction. Rats were acclimatized for 7 days in a plastic cage with a wire mesh cover, and received 12 hours of dark-12 hours of light lighting. During the adaptation process, rats were given food ad libitum. Prior to the study, skin on the dorsal side of rats was shaved and the extract was applied (500 mm<sup>2</sup>) to test skin irritation. The area was covered using adhesive tape and observations were conducted at different time intervals at 1,

24, and 48 hours and untreated skin served as control.

The extraction process was carried out using maceration method, carried out by soaking dry *Moringa* leaves with 70% ethanol solvent with a ratio of *Moringa* leaves: solvent of 1: 1. The soaking process was carried out for 2 days in an Erlenmeyer flask container and tightly closed using aluminium foil or using a closed container. During the soaking process, the container was shaken every 2 hours for 5 minutes. The soaking results were then filtered using filter paper to obtain the filtrate. Analysis of secondary metabolite content in the preparations that were made was carried out at the Pharmacognosy and Phytochemistry Laboratory of Science UNTAD. The secondary metabolite content analysed were flavonoids, tannins, saponins and terpenoids which were carried out qualitatively.

Gel preparations were made in preparations with extract concentrations of 10%, 20%, and 40%. Preparation of the preparation was done by dissolving nipagin in distilled water that had been heated to a temperature of 70°C, then added Na-CMC and stirring until homogeneous. After that, the moringa leaf extraction were added and stirred again until homogeneous.

Burn induction was carried out using solder connected to a 3cm metal, solder heated to 67°C, and attached to the back of the mouse for 7 seconds to form a second degree burn with a diameter of 2 cm. Before the solder induction treatment, the mouse was anesthetized using ethyl spray. The animal treatment was divided into 5 groups, with the following details: (1) Group 1 (K1): the positive control group was given 1gr of Bioplacenton with a dose of the giver, (2) Group 2 (K2): the negative control group was given Na-CMC gel base with a dose of 1 time a day, (3) Group 3 (K3): the treatment group was given 10% moringa leaf extraction gel with a dose of 1 time a day, (4) Group 4 (K4): the treatment group was given 20% moringa leaf extraction gel with a dose of 1 time a day, (5) Group 5 (K5): the treatment group was given 40%

moringa leaf extraction gel with a dose of 1 time a day. The animal treatment was carried out for 7 days in the Integrated Laboratory of Biochemistry at UNTAD.

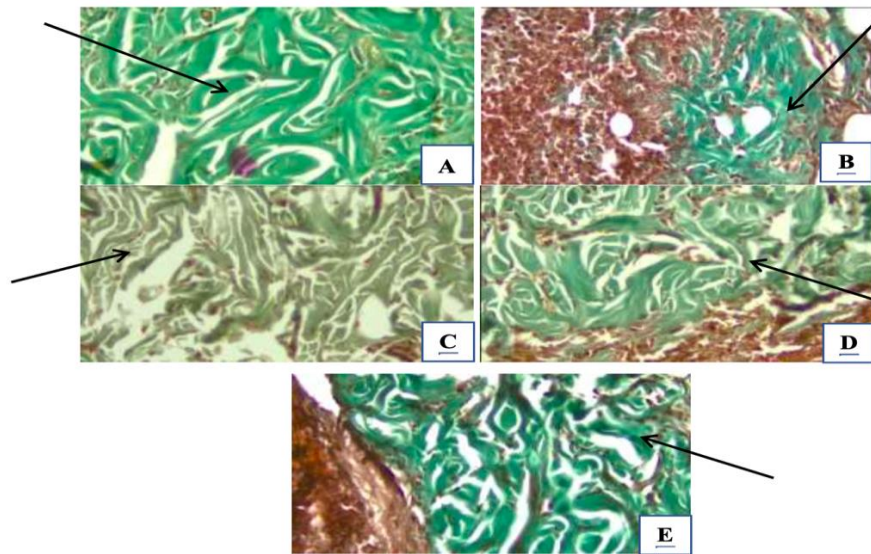
Experimental animals that were treated for 7 days had have their wound tissues taken. Anaesthesia was performed using ketamine with a dose of 75-100mg/kg body weight IM, then the wound skin tissue was excised transversely and stored in a labelled container containing 10% formalin buffer for 24 hours. Preparation of samples were carried out in the Anatomical Pathology Laboratory of the Faculty of Medicine and Public Health at UGM using a Leica RM 2235 microtome with the Manson T staining technique.

Collagen density observations was carried out using a 4000x magnification microscope in one field of view and the percentage of collagen density was calculated using the ImageJ software. The data obtained was tested for *Saphiro Wilk* normality. Normally distributed data will be analysed using the *One-way ANOVA* test followed by the Fisher post hoc test, while data that is not normally distributed will be analysed using the *Kruskal Walls Test* followed by the *Mann Whitney One Post Hoc Test*. Observations for the percentage of collagen density of injured skin tissue was carried out using a 400x magnification microscope with observation of one field of view. Observations were carried out using a double blind technique.

## RESULT

The histopathology of the skin tissue of experimental animals that experienced burns are shown in Figure 1, with the green area indicating the density of collagen formed. Figure (a) is group K1 as a positive control group with Bioplacenton administration showing the densest collagen image. Figure (b) is group K2 as a negative control with empty gel administration showing a collagen image that is not too dense. Figures (c), (d), and (e) are images of collagen density in the treatment groups with 10%, 20%, and 40% moringa extract

administration which show the densest collagen image in the treatment group with 40% moringa extract administration.



**Figure 1.** Histopathological picture of skin tissue of experimental animals (A) group K1, (B) group K2, (C) group K3, (D) group K4, (E) group K5. Black arrows indicates the formed collagen.

The average collagen density data in each experimental groups are shown in Table 1. In group K1, the administration of Bioplacenton had the highest average collagen density of 65.967%. In group K2 as a negative control, the administration of Na-CMC had the lowest collagen density of 49%. In the treatment groups of moringa

leaf extract administration, the administration of 40% concentration, namely group K5, had the highest average collagen density of 62.433%, followed by a concentration of 20%, namely group K4 of 51.300%, and the administration of 10% concentration, namely group K3 of 50.844%.

**Table 1.** The average collagen density of experimental animals in each treatment group

Group	N	Mean ± Deviation Std. (%)
K1	3	65,967 ± 5,0063
K2	3	49,167 ± 10,4318
K3	3	50,844 ± 9,6521
K4	3	51,300 ± 13,8011
K5	3	62,433 ± 4,0079
Total	15	55,490 ± 10,6090

\* K1: Positive control (Bioplacenton); K2: Negative control (Na-CMC); K3: 10% extract; K4: 20% extract; K5: 40% extract.

The collected data was tested for normality between groups using the Shapiro-Wilk test and the results obtained were normally distributed data with  $p > 0.05$  (0.103), so that parametric data analysis tests will be continued using the ANOVA test to analyse whether there is a significant difference in the average between two or more groups. Based on the ANOVA data analysis test, a significance value of  $> 0.05$  (0.164), hence

the administration of Moringa leaf extract gel did not provide significant effectiveness on the formation of collagen density in healing burns in experimental animals based on statistical analysis.

## DISCUSSION

*Moringa oleifera* leaf extract has shown potential for wound healing, particularly in burn wounds. Studies have demonstrated its

ability to increase collagen density, promote new capillary vessel formation, and enhance epithelialization in rat models. The extract's effectiveness is attributed to its antimicrobial, antioxidant, and anti-inflammatory properties, as well as its ability to stimulate fibroblast activation and reduce inflammatory cells. However, its efficacy may vary depending whether the samples had an infection as well as the type of infection. While multiple studies have reported significant wound healing abilities, further research is needed to identify the main bioactive compounds and establish safety profiles. [15]

These results were not in line with the research conducted by Herdiana et al (2022) which stated that moringa leaf extract has significant effectiveness on collagen formation in the healing process of punch biopsy wounds in experimental animals. The results of the study concluded that the 15% moringa extract content had a collagen formation effect on days 3, 5, and 7 of the wound healing process. [16] Assessment of collagen density on day 7 has not provided maximum results, so it is necessary to assess collagen density on several days (H + 7, H + 9 and H + 21) to provide a more optimal collagen density assessment. This is in accordance with the results of a study conducted by Etriwati et al (2023) which stated that collagen growth on the 14th day after treatment provided a more significant picture of collagen density compared to the picture of collagen density on the 3rd and 7th days after treatment. [17]

Another possibility is that the entire population of experimental animals has reached the maximum proliferation phase, so that an assessment of collagen density is needed in the early phases of the burn wound healing process (H + 3 and H + 5) to provide maximum results for assessing the effectiveness of collagen formation. The burn wound healing process is also influenced by several factors, both accelerating the healing process and slowing down the burn wound healing process. Some of these factors include: age, gender,

genetic factors, body metabolism factors, food factors, and lifestyle factors of living things. [18]

Through proliferative, antioxidant, and antibacterial processes, the *M. oleifera* leaf extract formulation was demonstrated to accelerate wound healing in diabetic rats. The local delivery of high and sustained concentrations of active substances at the wound site through topical application is anticipated to be beneficial, promoting quicker wound contraction, closure, and general healing. Furthermore, compared to oral intake, local applications are thought to have less systemic absorption, which could lower the risk of toxicity. In order to promote fibroblast cell infiltration and hasten the production of growth factors for wound healing, the proper moisture content or humidity in the wound area is also crucial. [15,18]

## CONCLUSION

Based on the results of the research that has been carried out, it can be concluded that statistically there is no effect of giving moringa extract gel on the percentage of collagen formation in healing burns in experimental animals. The positive control group with Bioplacenton administration has the highest density level, namely 65.967%. The concentration of moringa extract that has the highest level of collagen formation is 40% moringa extract, namely 62.433%.

### Declaration by Authors

**Ethical Approval:** Approved ethical permission to implement research from the Medical and Health Research Ethics Committee of Tadulako University based on research ethics feasibility letter number: 58/3/UN.281.30/KL/202.

**Acknowledgement:** None

**Source of Funding:** This work did not receive any grant from funding agencies in the public, commercial, or not-for-profit sectors.

**Conflict of Interest:** No conflicts of interest declared by any of the authors of this study.

## REFERENCES

1. Susanti., Fadilah, N.N., Nurani, A.S., et al. Formulasi Sediaan Patch Bioselulosa Ekstrak Daun Kelor (*Moringa oleifera*)

- Untuk Pengobatan Luka Bakar. *Jurnal Sains dan Kesehatan*. 2024; 6(1):1–9.
2. Ramdani, M.L. Peningkatan Pengetahuan Bahaya Luka Bakar dan P3K Kegawatan Luka Bakar pada Anggota Ranting Aisyiyah. Seminar Nasional. Purwokerto: Universitas Muhammadiyah Purwokerto; 2019
  3. WHO. Burns. Media Center of Burn. 2017.
  4. Riset Kesehatan Dasar (Riskesdas). Laporan Riskesdas 2018 Nasional. Jakarta: Badan Penelitian dan Pengembangan Kementerian Kesehatan RI; 2018.
  5. Akbar, M.A., and Agustina, F. Gambaran Perilaku Masyarakat Terhadap Penanganan Luka Bakar di Rumah. *Jurnal Kesehatan Komunitas*. 2023; 9(1):21-26.
  6. Arga, N.A., Jufriзал., Aklima. Pengetahuan Masyarakat Tentang Penanganan Pertama Luka Bakar. *JIM FKEP*. 2023; 7(2).
  7. Giri, M.D.S., Wardani, K., and Suena, D.S. Peran Metabolit Sekunder Tumbuhan dalam Pembentukan Kolagen pada Kulit Tikus yang Mengalami Luka Bakar. *Jurnal Integrasi Obat Tradisional*. 2021; 1(1):23-30.
  8. Matthe-stener, S.S., Roy, S., and Sen, C.K. Collagen in Wound Healing. *Bioengineering (Basel)*. 2021; 8(5):63.
  9. Alwafi, H., Almas,A.I., and Yazid,E.A. Perbandingan Efektivitas Produk Lebah dan Salep Luka Bakar Terhadap Kecepatan Penyembuhan Luka Bakar Derajat II pada Tikus Putih Jantan Galur Wistar. *JIMKI*. 2018; 6(2).
  10. Ivanalee, A.S., Yudianiyanti, I.S., Yunita, M.N., et al. Efektivitas Sugar Dressing (100% Gula) Dalam Meningkatkan Kepadatan Kolagen pada Proses Penyembuhan Luka Bakar Buatan pada Kulit Tikus Putih (*Rattus Norvegicus*) Jantan. *Jurnal Medik Veteriner*. 2018; 1(3):134-41.
  11. Zakiya, R., Mulqie, L., and Fitrianiingsih, S.P. Uji Aktivitas Ekstrak Etanol Daun Kelor (*Moringa oleifera* Lam) Terhadap Penyembuhan Luka Bakar Derajat II pada Mencit Swiss Weebster Jantan. *Prosiding Farmas*. 2019: 504-11.
  12. Puspitasari, D., Meliyana, S.M., Jayadilaga, Y., Rhesa, M., Saleh, A.R. Pengenalan Manfaat dan Pengolahan *Moringa Oleifera* Pada Anak di BTN Kasumberang Kabupaten Gowa. *JHP2M (Jurnal Hasil Pengabdian dan Pemberdayaan Masyarakat)*. 2023; 2(1):72-77.
  13. Erwiyani, A.R., Haswan, D., Agasi, A., et al. Pengaruh Sediaan Gel dan Krim Ekstrak Etanol Daun Kelor (*Moringa oleifera* Lamk) terhadap Penurunan Luas Luka Bakar pada Tikus. *Indonesian Journal of Pharmacy and Natural Product*. 2020; 3(2):41-52.
  14. Rinaldi., Fauziah., and Musfira, Y. Studi Formulasi Dan Efektivitas Gel Ekstrak Etanol Daun Sirih (*Piper betle* L.) Terhadap Penyembuhan Luka Bakar Pada Kelinci (*Oryctolagus cuniculus*). *Jurnal Dunia Farmasi*. 2019; 4(1):23-33.
  15. Mohammad Shafie, N., Raja Shahrman Shah, R.N.I.; Krishnan, P.; et al. Scoping Review: Evaluation of *Moringa oleifera* (Lam.) for Potential Wound Healing in In Vivo Studies. *Molecules*. 2022; 27: 5541. Available from <https://doi.org/10.3390/molecules27175541>
  16. Herdiana, M., Pramasari, CN., and Purnamasari, CB. Pengaruh Ekstrak Daun Kelor (*Moringa oleifera* Lam.) Terhadap Penyembuhan Luka. *Mulawarman Dental Journal*. 2022; 2(1).
  17. Etriwati, E., Muttaqin, A.C., Dasrul., et al. Pemberian Esktrak Jelly Daun Sikhoh-Khoh (*Chromolaena odorata*) Terhadap Kepadatan Kolagen Selama Penyembuhan Luka Inisi Tikus Putih (*Rattus Norvegicus*). *Jurnal Ilmiah Mahasiswa Veteriner (JIMVET)*. 2023; 7(3):74-82.
  18. Nurhaidah. Faktor-Faktor yang Mempengaruhi Proses Penyembuhan Luka Bakar Pada Penderita di Rumah Sakit Martha Friska Pulo Brayon Medan Tahun 2017. *Excellent Midwifery Journal*. 2018; 1(2):8-13.
- How to cite this article: Muhammad Mumtazmahal Al-Fathonah, William Sutanto, Ryka Marina Walanda, Asrawati Sofyan, Junjun Fitriani. *Moringa oleifera* L. leaf extract as wound dressing on collagen formation in burn wounds. *International Journal of Research and Review*. 2025; 12(3): 168-173. DOI: <https://doi.org/10.52403/ijrr.20250324>

\*\*\*\*\*