

Muscle Hernia of the Leg

**Dr. Tejashree Sonawane¹, Dr. Varsha Varghese², Dr. Rohanish More³,
Dr. Swapnil Mahajan⁴, Dr. Ananta Kulkarni⁵**

¹MBBS, MS Surgery, Senior Resident, BAVMC, Pune

²MBBS, DNB Surgery, Senior Resident, BAVMC, Pune

³MBBS intern BAVMC, Pune

⁴MBBS, DNB Surgery, Senior Resident, BAVMC, Pune

⁵MBBS, MS, MCH Plastic & Reconstructive surgery, Professor & HOD, Dept. of General Surgery, BAVMC
Pune

Corresponding Author: Dr. Tejashree Sonawane

DOI: <https://doi.org/10.52403/ijrr.20240235>

ABSTRACT

Muscle herniation is defined as a myofascial defect resulting in protruding of the muscle through the fascia covering it⁽³⁾. It can present anywhere in the body, the most common is the lower limbs⁽³⁾. Tibialis muscle herniation is considered a rare entity with few reported cases. Here, we present the case of a 24-year-old athlete male patient who complained of swelling and pain in the anterior aspect of the left leg for three months. He underwent fasciotomy with a good outcome.

KEYWORDS: Muscle hernia, tibialis anterior muscle, fasciotomy, trauma, athlete, myofascial

INTRODUCTION

Muscle hernias (also known as myofascial herniations) of the extremities most commonly occur in the leg (between the knee and ankle). Hugo Idhe is credited with providing the original investigation and groundwork on lower extremity muscle hernias in 1929⁽²⁾.

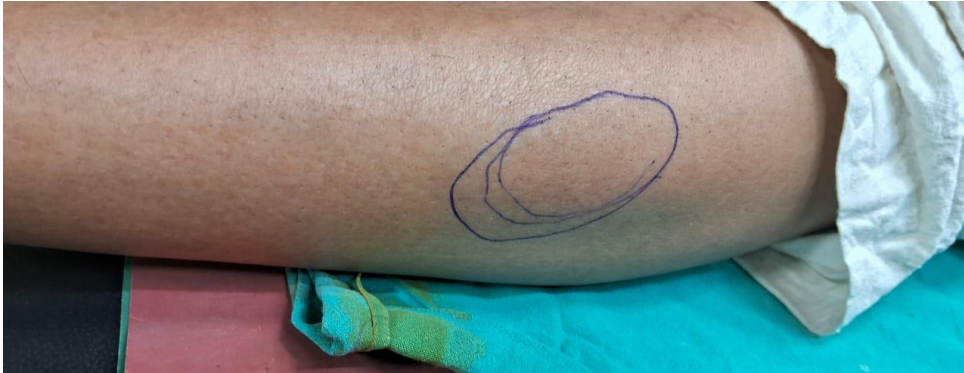Historically, treating military surgeons pioneered the early documentation of leg hernias observed in active military recruits

⁽¹⁾. A focal fascial defect can cause a muscle to herniate, forming a variable palpable subcutaneous mass, and causing pain and potentially neuropathic symptoms with nerve involvement⁽¹⁾. Most symptomatic cases respond successfully to conservative treatment, with surgery reserved for refractory cases⁽¹⁾. A variety of surgical techniques have been described, ranging from fasciotomy to anatomical repair of the fascial defect, with no consensus on optimal treatment⁽¹⁾.

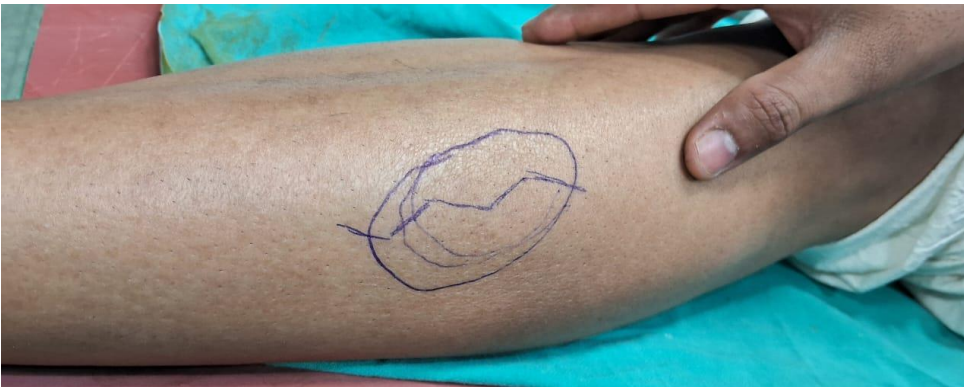CASE PRESENTATION

A 24-year-old athlete male, presented to the clinic with anterior left leg swelling that had been persistent for three months. It was associated with pain upon exertion. There was no history of skin changes and no history of trauma. On examination, there was a well-defined swelling on the anterior left leg, approximately 1 cm x 1 cm, non-tender. Dynamic US showed a muscular fascial defect at the anterior aspect of the mid-left leg, measuring around 1 cm and associated with muscle fibre herniation. There was no abnormal vascularity on Doppler images.

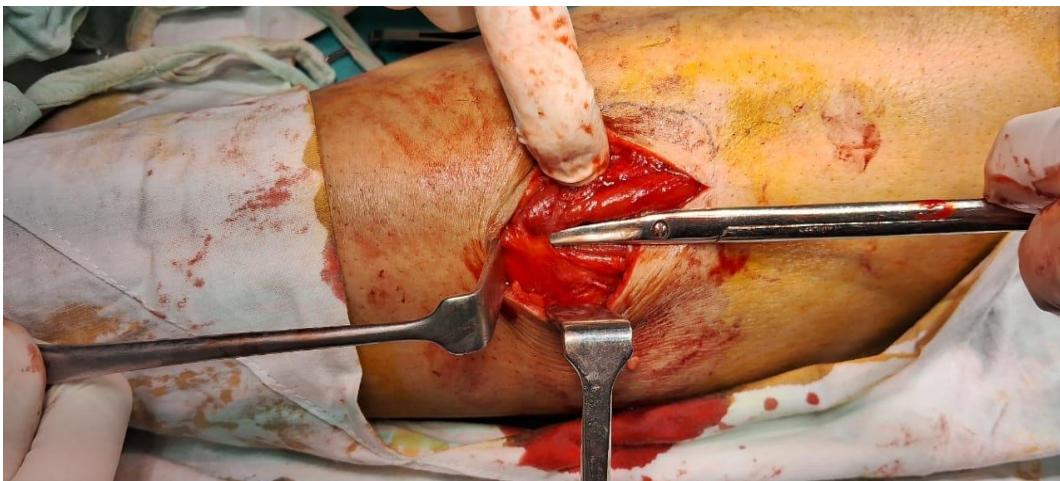
Photograph showing site of swelling on the anterior aspect of leg



Photograph showing incision mark over swelling



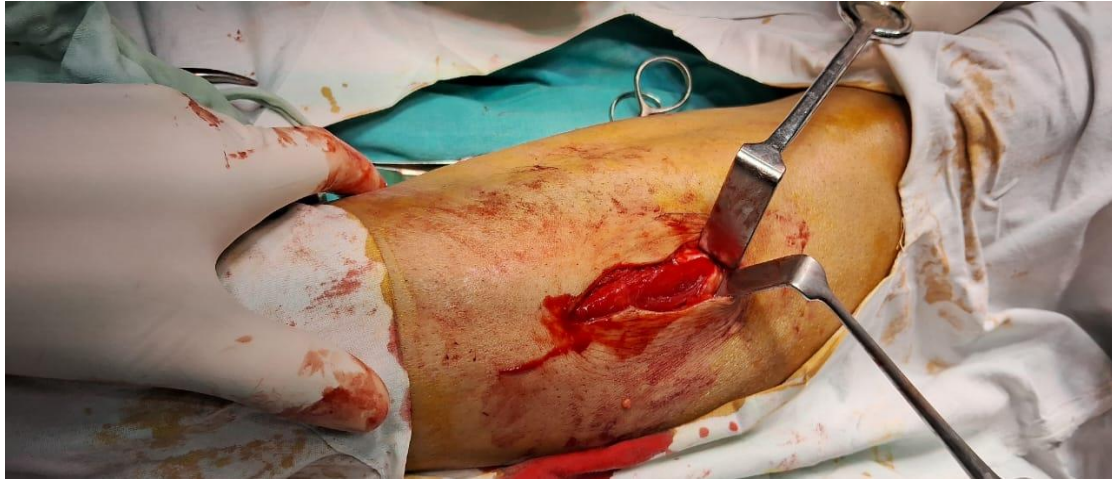Surgical exploration was done with a lazy S incision over the swelling. During the exploration, the fascial defect was identified by palpation.



Photograph depicting herniation matter with an underlying defect on the tibialis anterior muscle

The herniation matter was visible and was found to be subcutaneous fat with an underlying defect on the tibialis anterior muscle. It was roughly 1 cm in diameter.

Fasciotomy was done as defect was not getting approximated and tight fascia was above and below the defect, hence fasciotomy was performed.



Photograph showing defect in fascia of tibialis anterior muscle

At the follow-up three months post-surgery, the patient had a healed wound and did not have complaints of pain.

DISCUSSION

While the true incidence is not known, the etiology has been classified as secondary to a congenital (or constitutional) fascial weakness, or acquired fascial defect, usually secondary to direct or indirect trauma⁽¹⁾. The highest occurrence is believed to be in young, physically active males. Involvement of the tibialis anterior is most common, although other muscles have been reported⁽¹⁾.

Clinical findings include the presence of soft, compressible nodules that vary in size depending on their position. This mass is characterized by herniation during leg dorsi flexion also known as 'fencer's lunge position'⁽⁵⁾.

Although this condition is typically diagnosed by clinical observation, imaging specially ultrasound should confirm the diagnosis to avoid unnecessary biopsy. The clinical differential diagnoses are soft tissue

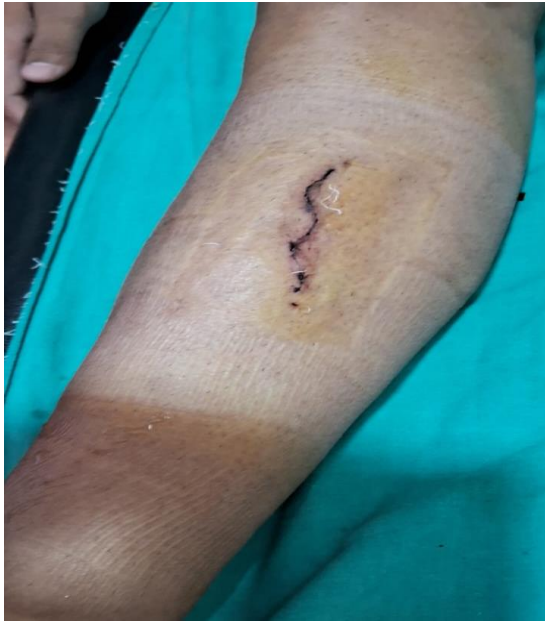tumors, such as lipoma, leiomyoma, Schwannoma, and dermatofibroma⁽⁶⁾.

Dynamic ultra sonography or magnetic resonance imaging is often used to confirm the diagnosis and guide treatment.

Complications of muscle herniation may be linked to pain, abnormal sensation, and compartment syndrome⁽⁴⁾.

There has been controversy regarding the treatment of tibialis anterior herniation, however, in the literature, asymptomatic hernias are preferably treated conservatively. Conservative options include rest, exercise restriction, and compression stockings. Surgical options that have been described in the literature include fasciotomy, primary repair of fascia, mesh repair, tibial periosteal flap, and fascia graft of the tensor fascia lata⁽³⁾.

Minimally invasive fasciotomy is safe and effective for management of muscle herniae of the tibialis anterior, allowing patients to return to their usual activities with no further symptoms⁽⁷⁾.



Photograph showing post operative closure of wound

A minimally invasive fasciotomy centered over the hernial orifice and extending proximally and distally allows complete recovery and return to pre-injury sport levels of activity⁽⁷⁾.

The efficacy of fasciotomy as standard management for patients with muscle hernia has been reported⁽⁷⁾.

Declaration by Authors

Acknowledgement: None

Source of Funding: None

Conflict of Interest: The authors declare no conflict of interest.

REFERENCES

1. Muscle hernias of the leg: A case report and comprehensive review of the literature Jesse T Nguyen MD1, Jenny L Nguyen MD2, Michael J Wheatley MD3, Tuan A Nguyen MD DDS FACS Jt nguyen, JL nguyen, MJ Wheatley, tA nguyen. Muscle hernias of the leg: A case report and comprehensive review of the literature. *Can J plast Surg* 2013;21(4):243-247
2. Ihde H. On muscular hernia of the leg. *Acta Chir Scand* 1929; 65:97-120.
3. Tibialis Anterior Muscle Hernia in a Young Woman Abdullah M. AlZahrani, Felwa A. AlMarshad, Nehal A. Mahabbat, Nora N. Alsaud, Khalid Fayi, Yazeed A. Jarman, Raghad AlKhashan, Abdulaziz Jarman DOI: 10.7759/cureus.36596
4. Reddy R: Focal herniation of tibialis anterior muscle diagnosed on dynamic high-resolution ultrasonography using provocative manoeuvres. *Cureus*. 2021, 13: e17119. 10.7759/cureus.17119
5. Lee JC, Healy J (2004) Sonography of lower limb muscle injury. *Am J Roentgenol* 182:341–351
6. doi:10.1186/s13089-014-0014-0 Artul and Habib: The importance of dynamic ultrasound in the diagnosis of tibialis anterior muscle herniation. *Critical Ultrasound Journal* 2014 6:14
7. Minimally invasive fasciotomy for symptomatic tibialis anterior muscle hernia <https://doi.org/10.1016/j.surge.2022.01.005>

How to cite this article: Tejashree Sonawane, Varsha Varghese, Rohanish More, DSwapnil Mahajan, Ananta Kulkarni. Muscle hernia of the leg. *International Journal of Research and Review*. 2024; 11(2): 333-336. DOI: <https://doi.org/10.52403/ijrr.20240235>
