

# Multilocular Cystic Renal Neoplasm of Low Malignant Potential - A Rare Case Report with Literature Review

Dr. Sunanda Lakshmi GV<sup>1</sup>, Dr. Vaheda Begum Korrappadu<sup>2</sup>,  
Dr. Kharidehal Durga<sup>3</sup>, Dr. Syam Sundar. B<sup>4</sup>, Dr. Deepthi. K<sup>5</sup>

<sup>1,2,3,4,5</sup>Department of Pathology, Narayana Medical College, Dr. YSRUHS University, Nellore, India

Corresponding Author: Sunanda Lakshmi GV

DOI: <https://doi.org/10.52403/ijrr.20240102>

## ABSTRACT

Multilocular cystic renal cell carcinoma or multilocular clear cell renal cell carcinoma is a rare type of cystic neoplasms of kidney. MCRCC comprises 1-2% of all renal tumors. MCRCC has well defined diagnostic criteria, has low stage The term MCRCC was renamed as MCRNLMP by ISUP in 2013. Only few cases of MCRCC are reported in literature till now We report a rare case of MCRCC / MCRNLMP in 52 years female presented with chief complaints of pain and dragging sensation in the right side of abdomen for 1 year.

**Keywords:** Multilocular, cystic, renal cell carcinoma, nephrectomy, low malignant potential.

## INTRODUCTION

Multilocular cystic renal cell carcinoma is an uncommon cystic variant of renal cell carcinoma with an excellent prognosis. It is currently defined by strict morphological criteria according to 2004 WHO classification of tumors. M: F is 1.1:1 in MCRCC and 0.9:1 in clear cell RCC. Cytogenic abnormality seen in clear cell renal cell carcinoma is 3p deletion.

Differential diagnosis of MCRCC is Cystic nephroma, cystic clear cell carcinoma, clear cell papillary RCC, and tubulocystic carcinomas. These tumors are differentiated based on radiology, microscopic features and immunohistochemistry.

## CASE REPORT

A 52 years old female came to urology OP of Narayana medical college and hospital with chief complaints of pain and dragging sensation in the right side of abdomen.

### Imaging:

Complete blood picture, renal function tests and other preoperative investigations were normal.

**CECT** shows solitary heterogeneously enhancing iso to hypodense mass lesion measuring approximately 4.5×4.5 cm seen in right kidney extending into parapelvic fat compressing lower pole calices, renal pelvis and causing mild hydronephrosis. Multiple cystic areas seen within the lesion. Impression was right renal mass? malignancy.

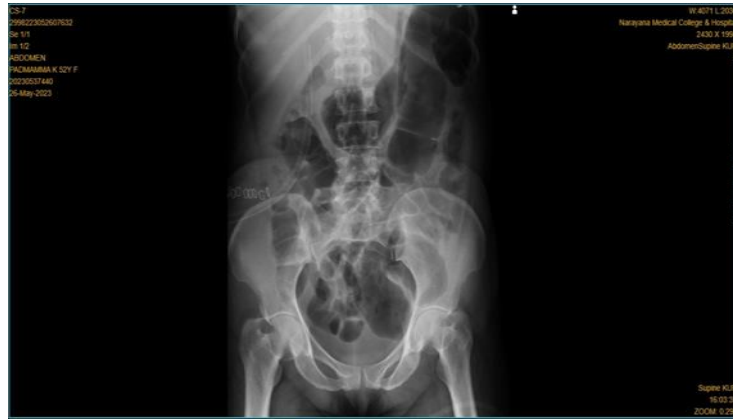

Figure 1 - Scanogram : Image showing right side renal lesion.

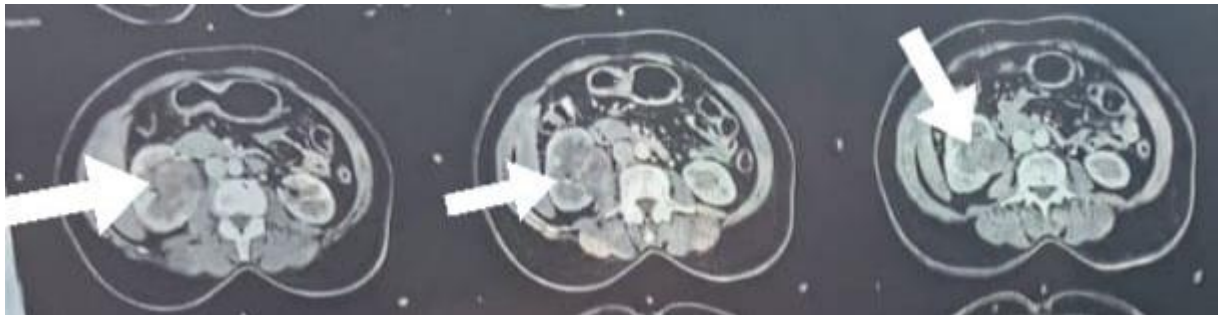

Figure 2 – CECT image showing cystic lesion in the right kidney in the lower pole.

In view of malignancy nephrectomy was done and specimen was sent for histopathological examination.

**Gross examination** on cut section revealed well defined well encapsulated 3.5×4×4 cm

multiloculated cyst 5 cm from upper pole, 2 cm from lower pole and 2 cm from lateral border. Cysts are filled with mucoid material and few cysts are filled with blood clots.

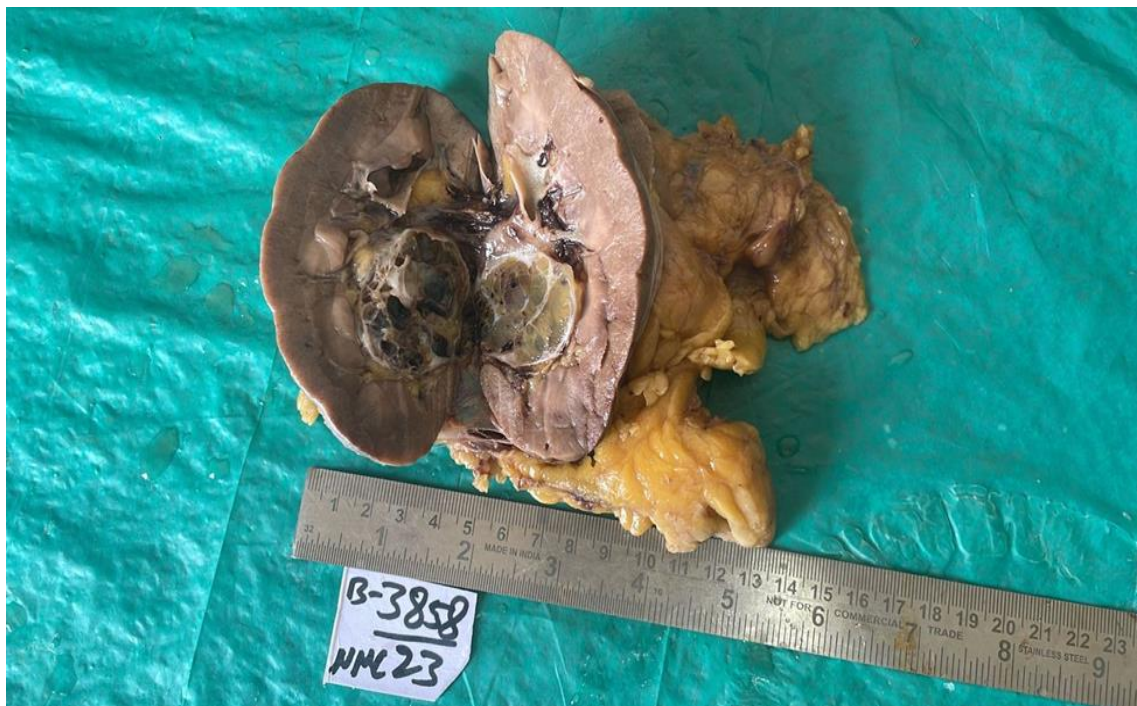

Figure 3 – Gross image showing cystic lesion in the right kidney lower pole.

**Microscopy:** Histopathological examination revealed tumor tissue with large to medium sized cysts lined by clear cells. Cysts are separated by fibrovascular tissue showing clusters of clear cell, inflammatory cells and congested blood vessels. Individual clear cells show distinct cell borders, clear

cytoplasm and centrally placed nuclei without pleomorphic nuclei. Cysts are filled with pink hyaline material and few cysts show hemorrhagic material. Renal capsule, perinephric pad of fat and hilar structures are free from tumor.

Fuhrman nuclear grade: Grade 1.

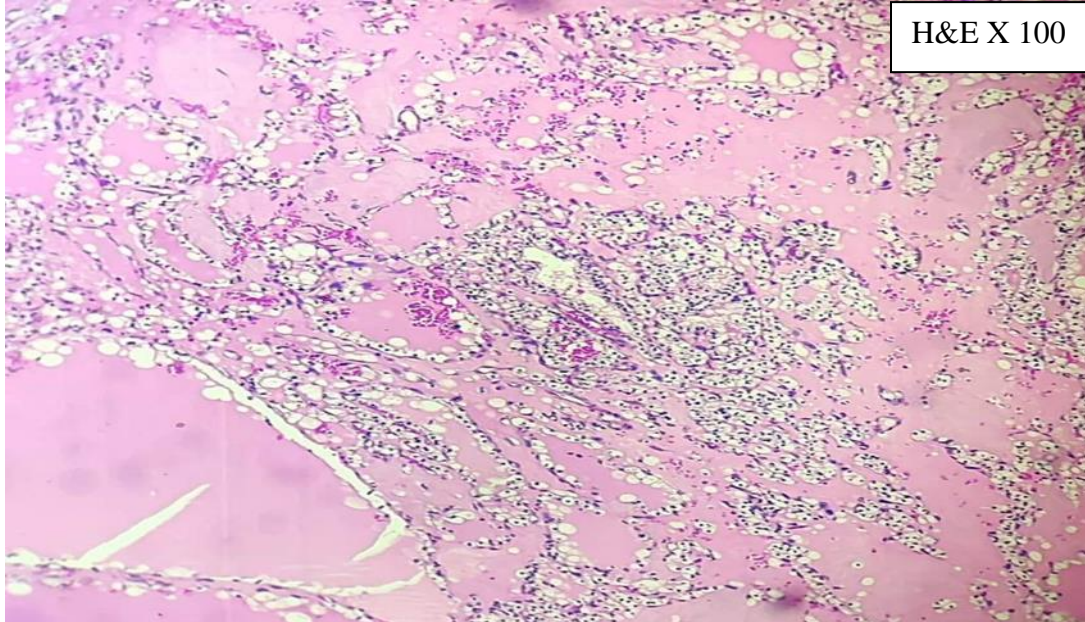


Figure 3: H&E shows multiple cystic spaces filled with pink hyaline material and lined by clear cells

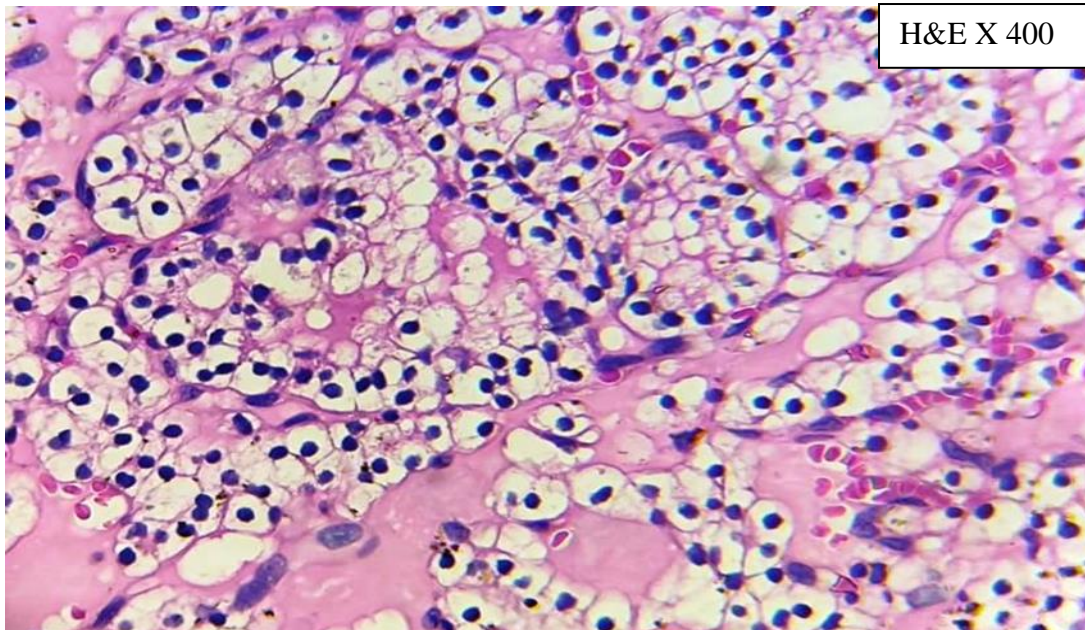


Figure 4: H& E stained section shows clear cells with well defined cell borders, clear cytoplasm and central nucleus without prominent nucleoli.

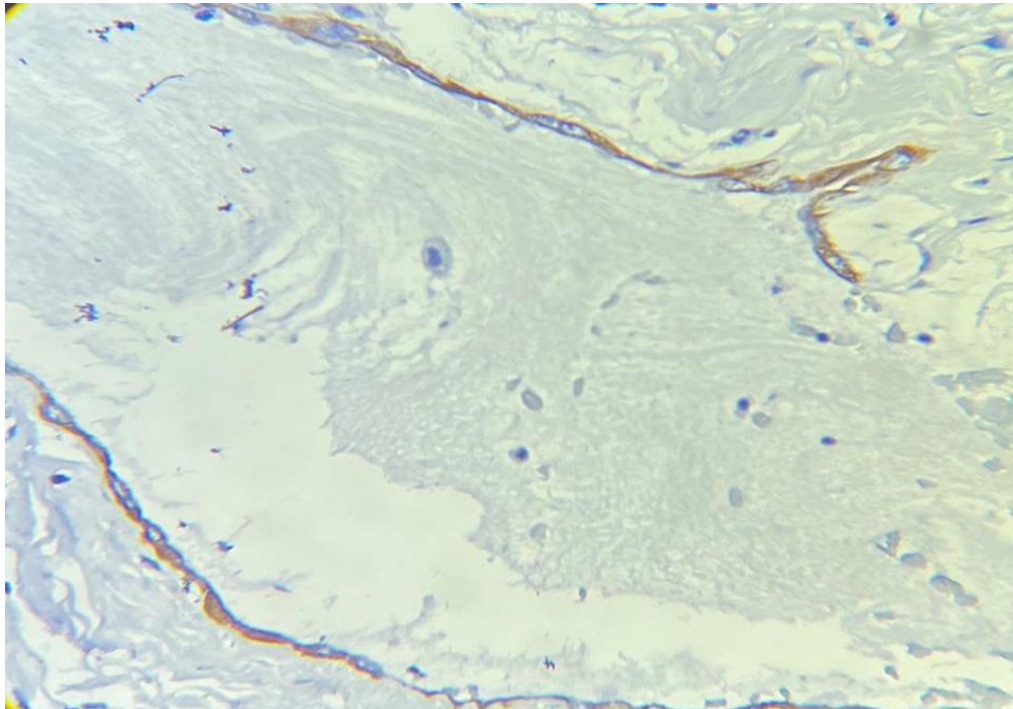


Figure 5: Immunohistochemical picture showing CK 7 positive tumor cells lining the cystic cavity.

## DISCUSSION

MCRCC was first described by Perlmann in 1928. MCRCC is a rare type of cystic neoplasms of kidney comprising less than 2% of all renal tumors. MCRCC occurs mainly in the age group of 30-80 years with mean age of 51 years and male to female ratio of 3:1[1]. The term MCRCC was renamed as MCRNLMP – Multilocular cystic renal neoplasm of low malignant potential was first described by Suzigan et al [2] in 2006. The term MCRCC was renamed as MCRNLMP by ISUP in 2013. MCRNLMP is a multilocular cystic tumor lined by clear cell with low nuclear grade [2]. Tumor size has no relation with patient survival rate [5]. The closest differential diagnosis of MCRNLMP is cystic clear cell renal cell carcinoma. Diagnostic criteria were established by WHO2004 and according to Eble and Bonsib and states that multilocular cysts separated by fibrous septa and lined by single layer of clear cells with furhmann low nuclear grade. Groups of clear cells may be seen in septae without expansile mass, this feature differentiates it from cystic clear cell RCC. Other differential diagnosis includes cystic nephroma, cystic papillary RCC and

tubulocystic RCC. MCRNLMP carries excellent prognosis compared to conventional RCC. Usually there is no tendency for recurrence or metastasis and only exception is regional lymph node metastasis described by Wash et al. CD10, EMA and vimentin are positive in both MCRCC and cystic clear cell RCC.

## CONCLUSION

Multilocular cystic renal neoplasm of low malignant potential has to be kept in mind while dealing with cystic neoplasms of kidney as this carry less malignant potential and less chances of recurrence and good prognosis compared to conventional cystic clear cell RCC

### *Declaration by Authors*

**Acknowledgement:** None

**Source of Funding:** None

**Conflict of Interest:** The authors declare no conflict of interest.

## REFERENCES

1. Chowdhury AR, Chakraborty D, Bhattacharya P and Dey RK Multilocular cystic renal cell carcinoma a diagnostic dilemma: A case report in a 30-year-old woman. Urol Ann 5: 119-121, 2013

2. Suzigan S, López-Beltrán A, Montironi R, Drut R, Romero A, Hayashi T, et al. Multilocular cystic renal cell carcinoma: a report of 45 cases of a kidney tumor of low malignant potential. *Am J ClinPathol* 2006; 125:217-222
3. Eble JN, Bonsib SM. Extensively cystic renal neoplasms: cystic nephroma, cystic partially differentiated nephroblastoma, multilocular cystic renal cell carcinoma, and cystic hamartoma of renal pelvis. *SeminDiagnPathol* 1998; 15:2-20
4. Murad T, Komaiko W, Oyasu R, Bauer K. Multilocular cystic renal cell carcinoma. *Am J ClinPathol* 1991;95: 633-637
5. Tamura Y, Okamura K, Ogura H, Kawada T, Tsuji H, Takahashi Y, Fukabori Y, Kobayashi M, Imai K and Yamanaka H: Multilocularcystic renal cell carcinoma: A report of 2 cases. *HinyokikaKiyo* 36: 437-441, 1990 (In Japanese).

How to cite this article: Sunanda Lakshmi GV, Vaheda Begum Korrapadu, Kharidehal Durga, Syam Sundar. B, Deepthi. K. Multilocular cystic renal neoplasm of low malignant potential - a rare case report with literature review. *International Journal of Research and Review*. 2024; 11(1): 10-14.  
DOI: <https://doi.org/10.52403/ijrr.20240102>

\*\*\*\*\*